This is a digital copy of a book that was preserved for generations on library shelves before it was carefully scanned by Google as part of a project to make the world's books discoverable online.

It has survived long enough for the copyright to expire and the book to enter the public domain. A public domain book is one that was never subject to copyright or whose legal copyright term has expired. Whether a book is in the public domain may vary country to country. Public domain books are our gateways to the past, representing a wealth of history, culture and knowledge that's often difficult to discover.

Marks, notations and other marginalia present in the original volume will appear in this file - a reminder of this book's long journey from the publisher to a library and finally to you.

Usage guidelines

Google is proud to partner with libraries to digitize public domain materials and make them widely accessible. Public domain books belong to the public and we are merely their custodians. Nevertheless, this work is expensive, so in order to keep providing this resource, we have taken steps to prevent abuse by commercial parties, including placing technical restrictions on automated querying.

We also ask that you:

+ *Make non-commercial use of the files* We designed Google Book Search for use by individuals, and we request that you use these files for personal, non-commercial purposes.

+ *Refrain from automated querying* Do not send automated queries of any sort to Google's system: If you are conducting research on machine translation, optical character recognition or other areas where access to a large amount of text is helpful, please contact us. We encourage the use of public domain materials for these purposes and may be able to help.

+ *Maintain attribution* The Google "watermark" you see on each file is essential for informing people about this project and helping them find additional materials through Google Book Search. Please do not remove it.

+ *Keep it legal* Whatever your use, remember that you are responsible for ensuring that what you are doing is legal. Do not assume that just because we believe a book is in the public domain for users in the United States, that the work is also in the public domain for users in other countries. Whether a book is still in copyright varies from country to country, and we can't offer guidance on whether any specific use of any specific book is allowed. Please do not assume that a book's appearance in Google Book Search means it can be used in any manner anywhere in the world. Copyright infringement liability can be quite severe.

About Google Book Search

Google's mission is to organize the world's information and to make it universally accessible and useful. Google Book Search helps readers discover the world's books while helping authors and publishers reach new audiences. You can search through the full text of this book on the web at `http://books.google.com/`

Transactions of the Ophthalmological Society of ...

Ophthalmological Society of the United Kingdom

Digitized by Google

E 413

BOSTON
MEDICAL LIBRARY
8 THE FENWAY.

Digitized by Google

Digitized by Google

Digitized by Google

O. Wadsworth

OPHTHALMOLOGICAL TRANSACTIONS

VOL. XXIII

Digitized by Google

Digitized by Google

TRANSACTIONS

OF THE

OPHTHALMOLOGICAL SOCIETY

OF THE

UNITED KINGDOM

VOL. XXIII

SESSION 1902–1903

WITH

LIST OF OFFICERS, MEMBERS, ETC.

LONDON
J. & A. CHURCHILL
7, GREAT MARLBOROUGH STREET

1903

Digitized by Google

BOSTON MEDICAL
OCT 7 1909
814
LIBRARY.

CATALOGUED
OCT 7 1909
J. F. B.

PRINTED BY ADLARD AND SON,
BARTHOLOMEW CLOSE, E.C.; 20, HANOVER SQUARE, W.;
AND DORKING.

Digitized by Google

IN EXCHANGE.

American Journal of Ophthalmology.
Annales d'Oculistique.
Annals of Ophthalmology, St. Louis, Mo., U.S.A.
Archiv für Ophthalmologie, Von Graefe.
Archives de Neurologie, Charcot.
Archives d'Ophtalmologie, Lapersonne, Landolt, Gayet, et Badal.
Archives of Ophthalmology, Knapp and Schweigger.
Bericht der ophthalmologischen Gesellschaft, Heidelberg.
Brain.
Centralblatt für praktische Augenheilkunde, Hirschberg.
Klinische Monatsblätter für Augenheilkunde, Axenfeld u. Uhthoff.
Ophthalmic Record, Chicago.
Recueil d'Ophtalmologie.
Revue générale d'Ophtalmologie.
Royal London Ophthalmic Hospital Reports.
Transactions of the American Ophthalmological Society.

Digitized by Google

NOTICE.

THE present volume comprises the proceedings of the Ophthalmological Society of the United Kingdom during its Twenty-second Session, October, 1902, to July, 1903.

The Society does not hold itself responsible for the statements, reasonings, or opinions expressed in the communications which the Council has deemed suitable for publication.

11, CHANDOS STREET,
CAVENDISH SQUARE, W.
October, 1903.

Digitized by Google

TABLE OF CONTENTS

OF VOLUME XXIII.

	PAGE
Officers and Council	IX
List of Presidents	X
List of Members	XI
Rules	XXXI
List of Communications made during the Session 1902–1903	XLI
List of Plates	XLVIII
List of Diagrams, etc., in Text	L
Diseases of the Eyelids	1
Diseases of the Conjunctiva	3
Diseases of the Cornea	25
Diseases of the Iris	39
Sympathetic Disease	46
Diseases of the Retina and Choroid	48
Diseases of the Optic Nerve	77
Diseases of the Orbit and Sinuses	154
Parasites	193
Colour-blindness	206
Pathological Anatomy	216
Congenital Conditions	242
Injuries	279
Operations, Instruments, and Appliances	324
Miscellaneous	356
Appendix	397
Report of Council	399
Notice to Members	402
Index	403

Digitized by Google

Digitized by Google

OFFICERS AND COUNCIL

OF THE

Ophthalmological Society of the United Kingdom

ELECTED AT

THE ANNUAL GENERAL MEETING, JULY 3RD, 1903.

President.

JOHN TWEEDY.

Vice-Presidents.

SIR G. ANDERSON CRITCHETT.
C. HIGGENS.
A. H. BENSON (Dublin).
A. W. SANDFORD (Cork).
C. E. GLASCOTT (Manchester).
A. STANFORD MORTON.
C. E. BEEVOR, M.D.
CHARLES OLDHAM (Brighton).
A. QUARRY SILCOCK.

Treasurer.

JOHN ABERCROMBIE, M.D.

Librarian.

W. ADAMS FROST.

Council.

P. FLEMMING.
W. M. BEAUMONT (Bath).
TATHAM THOMPSON (Cardiff).
E. TREACHER COLLINS.
ANGUS McGILLIVRAY (Dundee).
L. WERNER (Dublin).
H. WORK DODD.
NORMAN M. MacLEHOSE.
E. C. GREEN (Derby).
SECKER WALKER (Leeds).
DEVEREUX MARSHALL.
W. ALDREN TURNER, M.D.

Secretaries.

SYDNEY STEPHENSON.
J. S. RISIEN RUSSELL, M.D.

Digitized by Google

PRESIDENTS OF THE SOCIETY

(FROM ITS FORMATION).

ELECTED	
1880	SIR WILLIAM BOWMAN, BART., LL.D., F.R.S.
1883	JONATHAN HUTCHINSON, F.R.S.
1886	JOHN WHITAKER HULKE, F.R.S.
1889	JOHN HUGHLINGS JACKSON, M.D., LL.D., F.R.S.
1890	HENRY POWER.
1893	D. ARGYLL ROBERTSON, M.D.
1895	EDWARD NETTLESHIP.
1897	HENRY R. SWANZY.
1899	SIR ANDERSON CRITCHETT.
1901	DAVID LITTLE, M.D.
1903	JOHN TWEEDY.

TRUSTEES FOR THE SOCIETY.

JOHN ABERCROMBIE, M.D.
W. A. BRAILEY.
R. MARCUS GUNN.
STEPHEN MACKENZIE, M.D.
EDWARD NETTLESHIP.
SEYMOUR J. SHARKEY, M.D.

BOWMAN LECTURERS.

ELECTED	
1884	JONATHAN HUTCHINSON, F.R.S.
1885	J. HUGHLINGS JACKSON, M.D., F.R.S.
1886	PROF. ZEHENDER (Rostock).
1887	HENRY POWER.
1888	H. R. SWANZY.
1889	PROF. HANSEN GRUT (Copenhagen).
1890	J. W. HULKE, F.R.S.
1892	PROF. LEBER (Heidelberg).
1893	T. PRIDGIN TEALE, F.R.S.
1895	SIR W. R. GOWERS, M.D., F.R.S.
1896	PROF. SNELLEN (Utrecht).
1898	PRIESTLEY SMITH.
1900	R. MARCUS GUNN.
1902	PROF. E. FUCHS (Vienna).

Digitized by Google

*** *Members are requested to communicate with the Medical Secretary when corrections are necessary.*

LIST OF MEMBERS OF THE SOCIETY.

Honorary Members.

PROFESSOR ZEHENDER, Eutin, Oldenburg.
PROFESSOR LEBER, Heidelberg.
PROFESSOR HANSEN GRUT, Copenhagen.
PROFESSOR SNELLEN, Utrecht.
PROFESSOR FUCHS, Vienna.

EXPLANATION OF ABBREVIATIONS.

O.M.—Original Member.
Pres.—President.
V.-P.—Vice-President.
T.—Treasurer.
L.—Librarian.
S.—Secretary.
C.—Member of Council.
*.—Denotes Resident Life Members.
†.—Denotes Non-Resident Life Members.

GENERAL LIST OF MEMBERS.

ELECTED

O.M. *ABERCROMBIE, JOHN, M.D. (T.), 23, Upper Wimpole Street, W. (S. 1882-5. C. 1885-8. V.-P. 1897-8.)

1901 ADAM, JOHN LAW, M.B., Blackwater, Hants.

1884 †ALLISON, H., M.D., care of Messrs. Binny and Co., Madras, India.

1899 AMENABAR, JULIO DANIEL, Guayacan, Coquimbo, Chili.

1887 *ANDERSON, TEMPEST, M.D., 17, Stone-gate, York.

1883 ANDREWS, A. G., Carlton House, Moss Lane East, Manchester.

Digitized by Google

ELECTED

O.M. ARCHER, T. BRITTIN, 29, Nottingham Place, W.

1891 †ARMSTRONG, HUGH, Hobart, Tasmania.

1895 ATTLEE, JOHN, M.B., 58, Brook Street, W.

1903 BALLANTYNE, A. J., 11, Sandyford Place, Glasgow.

1900 †BARKER, A. J. GLANVILLE, P.M.O., Kuching, Sarawak, Borneo.

O.M. *BARLOW, Sir THOMAS, Bart., K.C.V.O., M.D., 10, Wimpole Street, W. (C. 1880-81. V.-P. 1894-7.)

1889 †BARRETT, JAMES W., M.D., 34, Collins Street East, Melbourne, Australia.

1883 BARTON, J. KINGSTON, 14, Ashburn Place, Courtfield Road, S.W.

1902 BATTEN, FRED. E., M.D., 33, Harley Street, W.

1892 BATTEN, RAYNER D., M.D., 33, Harley Street, W.

1888 *BEAUMONT, W. M. (C.), 4, Gay Street, Bath.

O.M. *BEEVOR, C. E., M.D. (V.-P.), 135, Harley Street, W. (S. 1891-4. C. 1894-7.)

1891 †BENNETT, ALFRED H., Adelaide, South Australia.

1897 BENNETT, H. PERCY, 12, Victoria Square, Newcastle-on-Tyne.

O.M. BENSON, A. H., M.D. (V.-P.), 42, Fitzwilliam Square, Dublin. (C. 1888-91.)

O.M. BERRY, G. A., M.D., 31, Drumsheugh Gardens, Edinburgh. (C. 1889-92. V.-P. 1895-8.)

1899 BICKERTON, R. E., M.B., 137, Harley Street, W.

1881 *BICKERTON, T. H., 88, Rodney Street, Liverpool. (C. 1895-8.)

1892 BLACK, JOHN WILSON, M.D.Edin., 46, Academy Street, Inverness.

1891 BLACK, J. URQUHART, M.B.

1898 BLAIR, CHARLES SAMUEL, M.D., 117A, Harley Street, W.

1885 BLUMER, W. P., 15, Esplanade West, Sunderland.

1895 †BONAR, THOMSON, M.D., 114, Via del Babuino, Piazzi di Spagna, Rome.

1885 BOWER, ERNEST DYKES, Elton House, Gloucester.

1897 BOWER, JOHN A., M.B., Portland House, Cheltenham.

Digitized by Google

ELECTED

1893 Bowerman, Albert Claude, M.B., Brentwood, California, U.S.A.

O.M. Brailey, W. A., M.D., 11, Old Burlington Street, W. (V.P. 1898-1901. S. 1883-6. C. 1880-3, 1886-9.)

1902 *Brailey, Wm. Herbert, 11, Old Burlington Street, W.

1897 Breuer, August, M.D., 10, Finsbury Circus, E.C.

1899 Brewerton, Elmore, 45, Weymouth Street, W.

1891 Bristowe, Hubert Carpenter, M.D., Wrington, Somerset.

1886 Bronner, Adolph, M.D., 33, Manor Row, Bradford. (C. 1900-3.)

1901 *Brooks, R. Philip, 24, Wimpole Street, W.

O.M. Browne, Edgar A., 39, Rodney Street, Liverpool. (C. 1887-90. V.-P. 1893-6.)

1898 Browne, James M., M.B., 22, St. Patrick's Hill, Cork.

1895 Browne, J. Walton, M.D., 10, College Square North, Belfast.

1901 Buchanan, Leslie, 17, Sandyford Place, Glasgow.

1893 †Bull, G. J., M.D., 4, Rue de la Paix, Paris.

1889 Bullar, John F., M.B., 7, Carlton Crescent, Southampton.

1883 †Buller, Frank, M.D., 838, Dorchester Street, Montreal, Canada.

1897 Bulteel, Marcus Henry, Havilland Street, Guernsey.

O.M. †Burnham, G. H., M.B., 157, Simcoe Street, Toronto, Canada.

1902 Buzzard, E. Farquhar, 33, Harley Street, W.

O.M. Buzzard, Thomas, M.D., 74, Grosvenor Street, W. (V.-P. 1888-91. C. 1881-2.)

1897 †Byers, W. Gordon M., M.D., 192, Peel Street, Montreal.

1892 †Caiger, Herbert, M.B., Burghersdorp, Cape Colony.

1891 Campbell, E. Kenneth, M.B., 23, Wimpole Street, W.

1887 Cant, W. E., M.D., British Ophthalmic Hospital, Jerusalem, Palestine.

1882 *Cant, W. J., 3, Lindum Road, Lincoln. (C. 1898-1901.)

Digitized by Google

ELECTED

1891 CARGILL, L. VERNON, 31, Harley Street, W.

1895 CARTWRIGHT, E. H., M.D., 1, Bower Terrace, Maidstone, Kent.

1898 CHATTERTON, EDGAR, 2, Upper Westbourne Terrace, Hyde Park, W.

1885 CHESSHIRE, ARTHUR EDWIN, 55, Darlington Street, Wolverhampton.

1897 CHETWOOD-AIKEN, K. C., M.B., C.M., Southleigh, Truro.

1885 CLARKE, ERNEST, M.D., B.S., 3, Chandos Street, Cavendish Square, W. (C. 1893-6.)

1902 COATS, GEORGE, M.D., 30, Weymouth Street, W.

1899 COLE, J. M. COATES, Maracaibo, Venezuela.

1901 COLE-BAKER, LYSTER, M.D., Bayfield, Kent Road, Southsea.

1899 COLEMAN, MAURICE W., M.D., Beaufort House, Reading.

1885 COLLINS, E. TREACHER, 17, Queen Anne Street, Cavendish Square, W. (C. 1889-92. S. 1898-1901.)

1886 COLLINS, Sir W. J., M.S., M.D., B.Sc., 1, Albert Terrace, Gloucester Gate, Regent's Park, N.W.

1901 COOKE, ARTHUR, 69, Bridge Street, Cambridge.

1898 COOPER, AUSTIN E., M.D., 41, Sloane Square, S.W.

1901 COOPER, LUDFORD, 19, Victoria Street, Rochester, Kent.

1894 †COOTE, PATRICK, M.D., 73, St. Ann Street, Quebec, Canada.

1898 COULTER, ROBERT J., M.B., 11, Clytha Park Road, Newport, Mon.

1884 COULTER, WILLIAM, M.D., 2/2, Harrington Street, Calcutta.

O.M. COUPER, JOHN, 80, Grosvenor Street, W. (C. 1881-2. V.-P. 1895-8.)

1895 †COURTENAY, J. D., M.D., Ottawa, Canada.

O.M. COWELL, GEORGE, 24, Harrington Gardens, S.W. (V.-P. 1889-91; 1898-1901. C. 1883-6. T. 1891-8.)

1901 CRAWLEY, F. C., M.D., 41, Lower Baggot Street, Dublin.

1899 CRESSWELL, B. P. SKEFFINGTON, M.B., B.S., 24, Windsor Place, Cardiff.

Digitized by Google

ELECTED

O.M. Critchett, Sir G. Anderson (V.-P.), 21, Harley Street, W. (*Pres.* 1899-1900. C. 1883-6. V.-P. 1894-7.)

1898 Critchley, Harry G., M.D., 166, Ebury Street, S.W.

1900 *Cropper, John, Mount Ballan, Chepstow (Mon.).

1881 Cross, F. R., Worcester House, Clifton, Bristol. (V.-P. 1898-1901. C. 1891-4.)

1902 Cruise, R. R., 2, Harley Street, W.

1884 Davidson, James McKenzie, M.B., 76, Portland Place, W. (C. 1892-5.)

1903 Davies, David, 18, Mount Sion, Tunbridge Wells.

1889 †Davis, G. C., 3, Hyde Park Terrace, 173, Liverpool Street, Sydney, New South Wales.

1897 Dawnay, Arch. Hugh Payan, 48, St. Mary Abbot's Terrace, Kensington, W.

1903 Dean, C. W., 16, Queen Street, Lancaster.

O.M. Dent, Clinton Thomas, 61, Brook Street, W.

1881 Dixon, W. E., Bridge Cot, Oulton Broad, Lowestoft.

1889 Dodd, Henry Work (C.), 136, Harley Street, W.

1882 †Dodge, Stephen, M.D.

1890 Donaldson, Eben., 49, Great James Street, Londonderry.

1899 Douglas, J. Sholto, M.B., George Town, British Guiana.

1890 Douty, Edward Henry, M.B., B.C., Hotel Belvedere, Davos Platz, Switzerland.

1887 Doyne, Robert W., 64, St. Giles', Oxford. (C. 1892-5.)

1881 *Drake-Brockman, E. F., 14, Welbeck Street, Cavendish Square, W. (C. 1895-8.)

1889 †Drake-Brockman, Herbert E., I.M.S., care of Wm. Watson and Co., Bombay, India.

1895 Du Boulay, H. H., 2, Royal Terrace, Weymouth.

1886 Dunn, Hugh Percy, 54, Wimpole Street, Cavendish Square, W.

O.M. Eales, Henry, 7, Newhall Street, Birmingham. (C. 1890-3. V.-P. 1900.)

1900 Eason, Herbert L., M.B., Guy's Hospital, S.E.

O.M. *Edmunds, Walter, M.D., 2, Devonshire Place, Portland Place, W. (C. 1885-8.)

Digitized by Google

ELECTED

1902 †Elliot, Robert Henry, c/o Messrs. Grindlay, 54, Parliament Street, S.W.

1903 Ellis, W. F., c/o Messrs. Holt, 3, Whitehall Place, S.W.

1883 *Embys-Jones, A., M.D., 10, St. John Street, Manchester.

1887 Ensor, Henry C., 23, Windsor Place, Cardiff.

1900 Evans, John Jameson, M.B., 110, Edmund Street, Birmingham.

1900 †Evans, Thomas, 211, Macquarie Street, Sydney, New South Wales.

1902 Evershed, A. R. F., 15, Great Winchester Street, E.C.

1891 Evill, F. Claude, Hadleycote, Hadley Green, Barnet.

1888 Fergus, A. Freeland, M.B., 22, Blythswood Square, Glasgow.

O.M. †Ferguson, H. L., Dunedin, New Zealand.

1889 Ferrier, David, M.D., F.R.S., 34, Cavendish Square, W. (C. 1896-7.)

1894 †Fischer, E. C., M.B., Cairo, Egypt.

1895 Fisher, J. Herbert, M.B., 83, Wimpole Street, Cavendish Square, W.

O.M. Fitzgerald, C. E., M.D., 27, Upper Merrion Street, Dublin. (V.P. 1882-5. C. 1880-1.)

O.M. Fitz-Gerald, W. A., M.D.

1889 Flemming, Percy (C.), 31, Wimpole Street, W.

1891 Foggin, George, 24, Eldon Square, Newcastle-on-Tyne.

1892 Folker, Herbert Henry, 11, Havelock Place, Stoke-on-Trent.

1886 Ford, A. Vernon, South View Lodge, Kent Road, Southsea.

1898 Frank, Philip, M.D., 3, Elvaston Place, S.W.

O.M. Frost, W. Adams (L.), 30, Cavendish Square, W.

1895 Galloway, A. Rudolf, M.B., 250, Union Street, Aberdeen, N.B.

1887 †Gardner, John J., M.D., 184, Peel Street, Montreal. Canada.

Digitized by Google

ELECTED

1889 GIBBS, ALFRED N. G., 52, Whiteladies Road, Clifton.

1902 †GIBSON, J. LOCKHART, M.D., Wickham Terrace, Brisbane, Australia.

O.M. GLASCOTT, C. E., M.D. (V.-P.), 23, St. John Street, Manchester. (C. 1896-9.)

1885 †GODFRAY, ALFRED CHARLES, St. Heliers House, St. Heliers, Jersey.

1899 GOLDSMITH, GEO. H., M.B., Bedford.

1897 GORDON, WILLIAM, M.D., B.C., Barnfield Lodge, Exeter.

O.M. GOWERS, Sir W. R., M.D., F.R.S., 50, Queen Anne Street, W. (C. 1880-3. V.-P. 1896-9.)

1897 GRANGER, F. M., 18, Nicholas Street, Chester.

1895 †GRANT, H. Y., M.D., 414, Delaware Avenue, Buffalo, U.S.

1895 †GRAY, JAMES, M.D., 119, Robert Street, Toronto, Canada.

1887 GREEN, EDWIN COLLIER (C.), 27, Friar Gate, Derby.

1900 GREEN, F. W. EDRIDGE, M.D., 14, Welbeck Street, W.

1903 GREENE, ARTHUR, 53, Torrington Square, W.C.

1896 GREY-EDWARDS, HENRY, M.D., Bank Place, Bangor, N. Wales.

1895 GRIFFIN, W. WATSON, M.B., 68, Brunswick Place, Hove, Brighton.

1885 *GRIFFITH, A. HILL, M.D., 17, St. John Street, Manchester. (C. 1893-6.)

1894 GRIMSDALE, HAROLD, M.B., 114, Harley Street, W.

O.M. GROSSMANN, K. A., 70, Rodney Street, Liverpool.

1899 GRUBER, RUDOLPH, M.D., 67, Wimpole Street, W.

1889 GUNN, DONALD S., 66, Wimpole Street, W. (C. 1900-2.)

O.M. GUNN, R. MARCUS, 54, Queen Anne Street, W. (C. 1882-5, 1889-92. S. 1886-9. V.-P. 1896-9.)

1898 GUTHRIE, LEONARD G., M.D., 15, Upper Berkeley Street, W.

1887 *HABERSHON, SAMUEL HERBERT, M.D., 88, Harley Street, W. (S. 1894-7. C. 1897-1900.)

Digitized by Google

ELECTED

1889 Hailes, C. D. G., M.D., Hawkesdale, 27, Alma Road, Clifton.

1885 †Haines, Humphrey, Auckland, New Zealand.

1902 †Halliday, J. C., Macquarie Street, Sydney, N.S.W.

1900 Hallidee, Andrew, M.B., 8, Warrior Square Terrace, St. Leonards-on-Sea.

1900 Hamilton, John. (*Address not communicated.*)

1896 Hamilton, Robert J., 42, Rodney Street, Liverpool.

1878 †Hamilton, T. K., M.D., Wakefield Street, Adelaide, South Australia.

1901 Hancock, Edw. D., Inns of Court Hotel, Holborn.

1899 Hancock, W. Ilbert, 19, Harley Street, W.

1901 Hanson, Reginald E., 5, Harley Street, W.

1900 Harman, N. B., M.B., 34, Queen Anne Street, W.

1901 Hartigan, T. P., Heathcote, East Grinstead, Sussex.

1886 Hartley, Robert N., M.B., 2, Clarendon Road, Leeds.

1882 *Hartridge, Gustavus, 12, Wimpole Street, W. (C. 1889-92, 1895-8. S. 1892-5.)

1899 Hawkes, C. S., c/o Dr. A. M. Hawkes, Glan-y-mor, Penally, Tenby, Wales.

1901 Hawthorne, C. O., 28, Weymouth Street, W.

1892 Haydon, Frank, Apothecaries' Hall, Water Lane, Blackfriars, E.C.

1898 Hayes, George C., 22, Park Place, Leeds.

1899 Henderson, Edward E., M.B., 12, Kensington Square, W.

1903 Henderson, Thomson, Eye Hospital, Bristol.

1896 Henry, R. Wallace, M.D., 6, Market Street, Leicester.

1901 Henry, John P., M.D., 41, Welbeck Street, W.

1897 †Herbert, Major Herbert, I.M.S. (care of Messrs. H. S. King and Co., 45, Pall Mall, S.W.).

1887 Hern, John, M.D., Semmercote, Darlington.

1895 Hickman, H. R. Belcher, M.B., 5, Harley Street, W.

O.M. Higgens, Charles (V.-P.), 52, Brook Street, W. (C. 1880-3.)

1903 Hill, Francis R., 12, Bolton Place, Carlisle.

Digitized by Google

ELECTED

1888 *Hinnell, J. S., M.B., 62, Garland Street, Bury St. Edmunds.

1902 Hoban, Thomas, Newport, Isle of Wight.

1899 Hobday, James, M.B., Bridgefield, Muswell Avenue, Muswell Hill, N.

1886 †Hodge, Rev. Sydney Rupert, Wesleyan Mission, Hankow, China.

1897 Hogg, G. H., M.D., 95, George Street, Launceston, Tasmania.

1889 Holthouse, Edwin H., M.B., 57, Devonshire Street, Portland Place, W.

1898 Hopkinson, Emilius, 45, Sussex Square, Brighton.

1893 †Howe, Lucien, 183, Delaware Avenue, Buffalo.

1901 Hudson, A. Ainslie, 32, Von Brandis Street, Johannesburg, South Africa.

1884 †Hudson, Ernest, Central Gaol, Benares, N.W.P., India.

1889 †Hughes, Samuel H., Gingola, Mowbray Road, Willoughby, Sydney, New South Wales.

1893 †Hughes, Wilfrid Kent, M.B., 102, Collins Street, Melbourne.

O.M. Hutchinson, Jonathan, F.R.S., 15, Cavendish Square, W. (*Pres.* 1883-6. V.-P. 1880-1, 1886-9.)

1901 Inman, Wm., M.B., Royal Ophthalmic Hospital, City Road, E.C.

1883 †Jackson, James, M.D., Collins Street East, Melbourne, Australia.

O.M. Jackson, J. Hughlings, M.D., F.R.S., 3, Manchester Square, W. (*Pres.* 1889-90. V.-P. 1880-2, 1890-3.)

1898 James, George Brooksbank, 1, Carlisle Mansions, Victoria Street, S.W.

1888 James, J. T., M.D., 30, Harley Street, W.

1883 †Jenkins, E. J., M.D., Nepean Towers, Douglass Park, Sydney, N.S.W., Australia.

1883 Jessop, W. H. H., 73, Harley Street, W. (C. 1889-92.)

1882 Johnson, G. Lindsay, M.B., Cortina, 24, Netherhall Gardens, South Hampstead.

Digitized by Google

ELECTED

1888 †Johnston, Geo. D., Georgia Street, Vancouver, British Columbia.

1902 Jones, E. Harries, 45, Sheep Street, Northampton.

O.M. Jones, Evan, Ty-mawr, Aberdare, Glamorganshire.

1898 *Jones, George, M.B., 8, Church Terrace, Lee, S.E.

O.M. Jones, H. Macnaughton, M.D., 141, Harley Street, W.

1897 Jones, Hugh E., 7, Rodney Street, Liverpool.

1894 †Jones, R. H., M.B., B.S., 209, Macquarie Street, Sydney, New South Wales.

1901 Joyce, Robert D., 7, Ely Place, Dublin.

O.M. Juler, H. E., 23, Cavendish Square, W. (C. 1886-9. V.-P. 1900-2.)

1899 Keeling, G. S., 23, Cavendish Square, W.

1900† Kelsall, H. T., M.D., 1, Devonshire Terrace, Perth, W. Australia.

1898 †Kendall, H. W. Martindale, Wellington, New Zealand.

1900 Kenna, Patrick James, M.B., Liverpool Street, Hyde Park, Sydney, N.S.W.

1888 †Kenny, Augustus Leo, M.B., 87, Collins Street, Melbourne, Victoria, Australia.

1890 Keogh, Alfred H., Surgeon-General, M.D., M.Ch., Army Medical Department, 18, Victoria Street, S.W.

1901 Kerr, James, M.D., School Board Offices, Victoria Embankment.

1891 Kingdon, E. C., M.B., C.M., 4, Upper College Street, Nottingham.

1900 Kirkland, Thomas Spier, M.B., College Street, Sydney, N.S.W.

1895 Knaggs, Robert Lawford, M.D., 27, Park Square, Leeds.

1881 †Knaggs, S. T., M.D., 16, College Street, Hyde Park, Sydney, New South Wales.

O.M. Lang, William, 22, Cavendish Square, W. (C. 1886-9. V.-P. 1900-3. *Acting Pres.* 1903.)

1881 Langdon, J. Winkley, 4, Winkley Square, Preston.

Digitized by Google

ELECTED

O.M. Lawford, J. B., 99, Harley Street, Cavendish Square, W. (C. 1886-9; 1898-1901. S. 1895-8.)

1889 *Laws, Wm. G., M.B., 3, East Circus Street, Nottingham.

1896 Lawson, Arnold, M.D., 12, Harley Street, W.

O.M. Lawson, George, 12, Harley Street, Cavendish Square, W. (C. 1882-4. V.-P. 1892-5.)

1895 †Lea, J. Augustus, M.B., Royal Colonial Institute, Northumberland Avenue, W.C.

1885 †Le Cronier, Hardwick, St. Heliers, Jersey.

O.M. Lediard, H. A., M.D., 35, Lowther Street, Carlisle. (C. 1900-1.)

1885 Lee, Charles G., 11, Princes Avenue, Liverpool.

1899 Leete, A. H. (*Address uncommunicated.*)

1896 Lister, W. T., M.B., Rose Hill, Totteridge, Herts.

1902 Little, Andrew, 14, Manningham Lane, Bradford, Yorks.

1892 Lodge, Samuel, jun., M.D., 13, Manningham Lane, Bradford.

1903 †Lückhoff, James, M.D., St. George's Street, Capetown.

1883 Lunn, J. R., Resident Medical Officer, New Marylebone Infirmary, Rackham Street, Ladbroke Grove Road, W. (C. 1892-5.)

1899 Lyle, Herbert W., M.D., Cintra, Elmfield Road, Bromley, Kent; and 29, Charles Street, Berkeley Square, W.

1892 Macarthur, Robert F., M.B. (*Address uncommunicated.*)

1900 MacCallan, Arthur Ferguson, M.B., Turf Club, Cairo, Egypt.

1902 Mackay, Duncan M., M.D., Throat and Ear Hospital, Brighton.

1888 *Mackay, George, M.D., 20, Drumsheugh Gardens, Edinburgh. (C. 1900-2.)

1889 †Mackenzie, F. Wallace, M.B., 139, Upper Willis Street, Wellington, New Zealand.

O.M. Mackenzie, Stephen, M.D., 18, Cavendish Square, W. (S. 1880-2. C. 1882-5. V.-P. 1893-6.)

Digitized by Google

ELECTED

1889 MacLehose, Norman M., M.B. (C.), 13, Queen Anne Street, Cavendish Square, W.

1897 Maclennan, Duncan N., M.D., 596, Jarvis Street, Toronto, Canada.

1892 †MacLeod, Charles G., M.B., 26, College Street, Hyde Park, Sydney, N.S.W.

1881 †Maconachie, G. A., Brigade Surgeon Lieutenant-Colonel, M.D., 33, Queen's Road, Aberdeen.

1899 Maddox, Ernest E., M.D., Lansdowne Road, Bournemouth.

1883 †Maher, W. Odillo, M.D., 20, College Street, Hyde Park, Sydney, N.S.W.

1899 †Manché, Charles, B.A., M.D., 18, Sda. Molini, Valletta, Malta.

1901 †Manning, Leslie S., Christchurch, New Zealand.

1883 †Marlow, Frank William, M.D., 401, Montgomery Street, Syracuse, New York State, U.S.A.

1892 Marshall, Charles Devereux (C.), 112, Harley Street, W.

1888 †Martin, Albert, M.D., Wellington, New Zealand.

1884 Maxwell, Patrick William, M.D., 19, Lower Baggot Street, Dublin. (C. 1900-2.)

1893 Maynard, Frederic Pinsent, Major, Indian Medical Service, care of Grindlay and Co. Calcutta.

1899 Maynard, George D., Roche, Cornwall, R.S.O.

1902 Mayou, Stephen, 46, Weymouth Street, W.

1890 *McGillivray, Angus, M.D. (C.), 23, South Tay Street, Dundee, N.B.

O.M. McHardy, M. M., 5, Savile Row, W. (C. 1887-90.)

1895 †McIntosh, J. R., M.D., 44, King Square, St. John, New Brunswick, Canada.

1895 McKenzie, H. V., M.D., Elmbank, Abbey Road, Torquay.

1884 McKeown, David, M.D., 25, St. John Street, Manchester.

1884 McKeown, W. A., M.D., 20, College Square East, Belfast.

Digitized by Google

ELECTED

1902 McMullen, W. H., 319A, Brixton Road, S.W.

O.M. Meighan, T. S., M.D., 37, Elmbank Crescent, Glasgow.

1901 Menzies, J. A., Caledonian Club, Charles Street, St. James's, S.W.

1902 Messer, Andrew, Lemington, Newcastle-on-Tyne.

1897 Miller, G. Victor, M.B., 2, Barrington Crescent, Stockton-on-Tees.

1899 Miller, Herbert Percy, M.D., 100, Stoke Newington Road, N.

1881 †Milles, W. Jennings, care of Drs. Henderson and Macleod, Shanghai, China.

1897 †Minnes, Robert Stanley, M.D., 127, Metcalfe Street, Ottawa, Ontario.

1901 Montgomery, Robert J., M.B., 18, Westland Row, Dublin.

1896 Mooney, Herbert C., M.B., 22, Lower Baggot Street, Dublin.

O.M. Morton, A. Stanford (V.-P.), 133, Harley Street, W. (C. 1886-9.)

1898 Mott, F. W., M.D., F.R.S., 25, Nottingham Place, W.

1890 Mowat, Daniel, M.D., St. Ninian's, 93, Stamford Hill, N.

O.M. Mules, P. H., M.D., 31, Nicholas Street, Chester. (C. 1886-9. V.-P. 1900-2.)

1899 Murphy, James Keogh, 35, Prince's Square, W.

1891 Myddelton-Gavey, Edward Herbert, 16, Broadwater Down, Tunbridge Wells.

1893 Napier, F. H., M.B., B.S., 18, Brandon Place, Glasgow.

O.M. *Nelson, Joseph, M.D., 29, Wellington Place, Belfast. (C. 1893-5.)

O.M. *Nettleship, Edward, Nutcombe, Hindhead, Haslemere. (*Pres.* 1895-7. S. 1880-3. C. 1883-6. V.-P. 1886-9.)

1881 Nicholson, A., 30, Brunswick Square, Brighton.

1901 Nixon, John Alex., 55, Venner Road, Sydenham, S.E.

1895 *Ogilvie, F. Menteith, M.B., 53, Broad Street, Oxford.

Digitized by Google

ELECTED

1895 Ogilvy, Alexander, M.B., Montrose House, Clifton.

1889 †O'Kinealy, Frederick, Major, I.M.S., care of Messrs. H. S. King, and Co., 45, Pall Mall, London.

1884 Oldham, Charles J. (V.-P.), 38, Brunswick Square, Brighton. (C. 1897-1900.)

1899 Oldmeadow, Lloyd J. H., 15, Half Moon Street, W.

1902 O'Leary, Richard, Grantley, Eltham, Kent.

1899 Ormond, Arthur Wm., 22, St. Thomas Street, London Bridge, S.E.

1892 †Orr, Andrew William, M.D., A. M. P. Buildings, Edward Street, Brisbane.

1890 †Osborne, A. B., M.D., 46, McNab Street South, Hamilton, Canada.

O.M. Owen, D. C. Lloyd, 41, Newhall Street, Birmingham. (V.-P. 1891-4.)

O.M. Page, Herbert W., 146, Harley Street, W. (C. 1890-3.)

1890 †Palmer, L. Loran, M.D., 42, St. George Street, Toronto, Ontario, Canada.

1894 *Parker, Herbert, 7, Bloomsbury Place, W.C.

1899 Parker, Herbert George, 29, Chorley New Road, Bolton.

1900 Parsons, John Herbert, 28, Great Ormond Street, W.C.

1893 Part, J. Shepley, 20, Ashchurch Park Villas, Goldhawk Road, Ravenscourt Park, W.

1887 †Patel, D. H., Bai Hirabai, B. J. Charitable Dispensary, Tardeo, Bombay.

1900 †Patkar, Bhagvant Sakharam, Carnac Road, Kalkadeir Post, Bombay, India.

1902 Paton, Leslie, 1, Spanish Place, Manchester Square, W.

1897 Pechell, Horace James, M.B., Molteno, Cape Colony.

1888 Percival, Archibald Stanley, M.B., B.Ch., 26, Ellison Place, Newcastle-on-Tyne.

Digitized by Google

ELECTED

1891 Perry, A., Surgeon-Major, Principal Civil Medical Officer, Ceylon.

1889 †Perry, Francis F., Lahore Medical College, Punjab, India.

1889 Phillips, T., 124, Harley Street, W.

1895 Pickard, Ransom, M.D., 31, East Southernhay, Exeter.

1900 †Pockley, Francis Antill, M.B., 227, Macquarie Street, Sydney, N.S.W.

1896 Pooley, G. H., Royal Westminster Ophthalmic Hospital.

1894 †Pope, R. J., M.D., Box 497, G.P.O., Sydney, N.S.W.

1900 Pope, Thomas Henry, M.D., B.Sc., Marshall's Road, Egmore, Madras, India.

1902 Potter, Bernard E., 16, Little Grosvenor Street, W.

1903 Potts, George, County Ophthalmic Hospital, Maidstone.

O.M. Power, Henry, 10A, Chandos Street, W. (*Pres.* 1890-3. V.-P. 1882-5, 1893-6. C. 1880-2.)

1899 Price, Henry J., Maldon, Essex.

1888 Price, John A. P., M.D., 124, Castle Street, Reading.

1882 Prichard, Arthur William, 6, Rodney Place, Clifton.

1892 Pronger, Charles Ernest, East Parade, Harrogate.

O.M. Purves, W. Laidlaw, 20, Stratford Place, Oxford Street, W.

1888 Rainy, Adam R., M.B., 6, Upper Wimpole Street, W.

1889 Ramsay, A. Maitland, M.D., 15, Woodside Place, Glasgow.

1899 Read, E. I., Government Medical Officer, Trinidad, West Indies.

1881 †Reeve, R. A., M.D., 22, Shuter Street, Toronto, Canada.

O.M. Reid, Thomas, M.D., 11, Elmbank Street, Glasgow. (V.-P. 1884-7.)

1885 Renton, James Crawford, M.D., 1, Woodside Terrace, Glasgow.

1891 Reynolds, Austin Edward, Highcroft, Shepherd's Hill, Highgate, N.

Digitized by Google

ELECTED

1897 Richmond, R., M.D., Brookfield, Woodside, Wimbledon, S.W.

1892 Ridley, Nicholas C., M.B., 27, Horse Fair Street, Leicester.

1900 Riseley, Stanley, Glossop Road, Sheffield.

1897 Rivers, W. H. R., M.D., St. John's College, Cambridge.

1885 *Roberts, Edward, 12, St. John Street, Deansgate, Manchester.

1896 †Roberts, J. R., Major, M.B., care of Messrs. King, King and Co., Bombay.

O.M. *Robertson, D. Argyll, M.D., 18, Charlotte Square, Edinburgh. (*Pres.* 1893-95. V.-P. 1881-2, 1886-9, 1896-9. C. 1895.)

1891 Robertson-Fullarton, Archibald Louis, M.B., C.M., 201, Bath Street, Glasgow.

O.M. Rockliffe, W. C., M.D., 17, Charlotte Street, Hull. (C. 1892-5. V.-P. 1900-3.)

1898 Roe, Arthur Legge, 45, Pryme Street, Hull.

1898 Roll, G. W., M.B., B.C., 7, Upper Wimpole Street, W.

1890 Rolston, John R., 14, The Crescent, Plymouth.

1891 Roper, Arthur Charles, The Shrubbery, Exeter.

1882 †Roth, Reuter E., 42, College Street, Hyde Park, Sydney, New South Wales.

1893 Rowan, John, M.B., 9, Blythswood Square, Glasgow, N.B.

1899 *Roxburgh, A. B., M.B., 7, Henrietta Street, W.

1881 †Rudall, J. T., 61, Spring Street, Melbourne, Australia.

1895 Russell, J. S. Risien, M.D. (S.), 44, Wimpole Street, W. (C. 1900-3.)

1888 †Sanders, Richard C., M.D., Loppington Hall, nr. Wem, Salop.

1884 *Sandford, Arthur W., M.D. (V.-P.), 13, St. Patrick's Place, Cork. (C. 1896-9.)

1881 *Sansom, A. E., M.D., 84, Harley Street, W. (C. 1893-5.)

O.M. Savage, G. H., M.D., 3, Henrietta Street, Cavendish Square, W. (C. 1892-4.)

Digitized by Google

ELECTED

1900 †Sager, D. S., M.D., Brantford, Ontario, Canada.

1891 Schorstein, Gustave, M.D., 11, Portland Place.

1888 Scott, Kenneth, 7, Manchester Square, W.

1901 Scott, G. Melmoth, 16, Palace Chambers, Kalgoorlie, Australia.

1900 Scott-Heyliger, E. D., 89, Preston New Road, Blackburn.

1892 Shannon, John Rowlands, M.D., 20, West 35th Street, New York.

O.M. Sharkey, S. J., M.D., 22, Harley Street, W. (S. 1885-8. C. 1888-91. V.-P. 1900-2.)

1894 Shaw, Cecil E., M.D., 14, College Square East, Belfast.

1883 Shears, Charles H., 19, Upper Duke Street, Rodney Street, Liverpool. (C. 1900–3.)

1883 Silcock, A. Q. (V.-P.), 52, Harley Street, W. (S. 1889-92. C. 1892-5.)

1902 Silva, W. H. de, Grenier Eye and Ear Hospital, Colombo, Ceylon.

1893 Simpson, R. J. S., M.B., care of Messrs. Holt and Co., Whitehall Place, S.W.

1899 Sinclair, A. H. H., M.B., 13, Walker Street, Edinburgh.

1891 Sinclair, Walter William, 3, Arcade Street, Ipswich.

1889 Smith, John, M.D., Brycehall, Kirkcaldy, N.B.

O.M. Smith, Priestley, 95, Cornwall Street, Birmingham. (V.-P. 1887-90; 1898-1901. C. 1883-6.)

1881 Smith, T. Gilbart, M.D., 68, Harley Street, W.

1900 Smith, William E., M.B., 8, Queen Victoria Street, Capetown.

1903 Smyth, Ernest J., Dunseverick, Barnet, Herts.

O.M. Snell, Simeon, 70, Hanover Street, Sheffield. (C. 1884-7. V.-P. 1892-5.)

1901 Snowball, Thomas, M.B., Thorn Hill, Burnley.

1889 Spencer, Matthew H., M.B., B.Ch., 95, St. Mark's Road, North Kensington, W.

1889 Spicer, Wm. T. Holmes, M.B., 5, Wimpole Street, Cavendish Square, W. (C. 1900-2.)

1897 Square, James Elliot, 22, Portland Square, Plymouth.

Digitized by Google

ELECTED

1895 †Stamberg, A. C., M.B., 5, Windsor Terrace, St. Heliers, Jersey, Channel Islands.

1886 Stephenson, Sydney (S.), M.B., 33, Welbeck Street, W. (C. 1898-1901).

1896 Stevenson, Edgar, M.D., 67, Rodney Street, Liverpool.

1893 Stirling, Alexander Williamson, M.D., Atlanta, Georgia.

1887 †Stirling, J. W., M.B., 873, Dorchester Street, Montreal, Canada.

O.M. Story, J. B., 6, Merrion Square North, Dublin. (C. 1885-8. V.-P. 1894-7.)

O.M. †Sturge, W. A., M.D., 15, Rue Longchamp, Nice, Les Alpes Maritimes.

O.M. Swanzy, H. R., 23, Merrion Square North, Dublin. (V.-P. 1880-1, 1889-92, 1900-2. *Pres.* 1897-9.)

1888 *Sym, William George, M.D., 12, Alva Street, Edinburgh.

1883 †Symons, Mark Johnston, M.D., North Terrace, Adelaide, South Australia.

1886 Sympson, E. Mansel, M.D., Deloraine Court, Lincoln.

1898 Tait, Edward Sabine, M.D., 48, Highbury Park, N.

O.M. Tay, Waren, 4, Finsbury Square, E.C. (C. 1880-2.)

1882 Taylor, C. Bell, M.D., Beechwood Hall, Mapperley Park, Notts.

1902 Taylor, Henry J., 62, St. George's Road, Bolton.

1899 Taylor, Inglis, M.B., 16, Harley Street, W.

1891 Taylor, James, M.D., 49, Welbeck Street, W. (C. 1894-7. S. 1897-1900. C. 1900-3.)

1889 Taylor, S. J., M.B., 34, Prince of Wales' Road, Norwich.

1900 Teale, Michael A., 38, Cookridge Street, Leeds.

O.M. Teale, T. Pridgin, F.R.S., 38, Cookridge Street, Leeds. (V.-P. 1880-1.)

1900 Thomas, Frank G., M.B., 2, Brunswick Place, Swansea.

O.M. Thomas, Jabez, Ty-Cerrig, Swansea.

1903 Thomas, R. Russell, 112, Cathedral Road, Cardiff.

1895 Thompson, A. Hugh, M.D., 27, New Cavendish Street, W.

Digitized by Google

ELECTED

1903 Thompson, Arthur H., 1, Pump Court, Temple, E.C.

1885 Thompson, C. Sinclair, The Quay, Bideford, Devon.

1895 Thompson, George W., M.B., 15, Harley Street, W.

1888 Thompson, John Tatham, M.B. (C.), 24, Windsor Place, Cardiff.

1895 Thompson, Robert, M.D., B.S., Dalkeith House, Wharf Street, Brisbane.

1898 Thomson, W. Ernest, M.D., 2, Somerset Place, Glasgow.

1903 Tipper, E. H., 25, Holland Road, Brixton, S.W.

1883 †Tobin, William, 31, Hollis Street, Halifax, Nova Scotia, Canada.

1900 Tomlinson, John H. Belmont, Vicarage Road, Egham.

1895 Toombs, Herbert George, 18, Faraday Mansions, Queen's Club Gardens, West Kensington.

1883 Tooth, Howard H., M.D., 34, Harley Street, W. (C. 1897-1900.)

O.M. Tosswill, L. H., 28, West Southernhay, Exeter. (C. 1896-9.)

1902 †Trilokekar, V. S., 308, Lohar Street, Bombay, India.

1890 Turner, William Aldren. M.D. (C.), 13, Harley Street, W. (C. 1897-1900. S. 1900-3.)

O.M. Tweedy, John (*Pres.*), 100, Harley Street, W. (C. 1884-7. V.-P. 1891-4.)

1898 Tyrrell, F. Astley Cooper, M.B., Royal London Ophthalmic Hospital, City Road, E.C.

1883 Uhthoff, J. C., M.D., Wavertree House, Brunswick Place, Brighton.

1894 Usher, C. H., M.B., 3, Bon Accord Square, Aberdeen.

1888 Walker, Cyril H., M.B., 16, Pembroke Road, Clifton, Bristol.

O.M. Walker, G. E., 45, Rodney Street, Liverpool.

1892 Walker, H. Secker (C.), 44A, Park Square, Leeds.

1901 Walmisley, Nicolas, Hampden Club, Phœnix Street, St. Pancras, N.W.

1900 Wardale, John D., M.B., 8, Eldon Square, Newcastle-on-Tyne.

Digitized by Google

ELECTED

1893 Warner, F. Ashton, 10, Brechin Place, S.W.

1893 Warren, H. Guy S., 205, Macquarie Street, Sydney.

1893 †Weekes, Charles Jones, Lithgow, New South Wales.

1887 Wells, Arthur P. L., M.B., 83, Harley Street, W. (C. 1896-9.)

1885 Werner, Louis, M.B. (C.), 31, Merrion Square North, Dublin.

O.M. West, Samuel, M.D., 15, Wimpole Street, W. (C. 1888-91.)

O.M. *Wherry, G. E., M.B., Corpus Buildings, Cambridge. (C. 1897-1900.)

1895 Whitehead, Arthur Longley, M.B., 31, Park Square, Leeds.

O.M. Williams, R., 82, Rodney Street, Liverpool. (V.-P. 1896-9.)

1894 Williams, W. E., M.B., Portmadoc, Carnarvonshire.

1888 †Willis, C. Fancourt, M.D., Mahableshwar, India.

1900 Wood, C. G. Russ, Hardwick House, Shrewsbury.

1889 Wood, David J., M.B., 41, Grave Street, Cape Town, South Africa.

1903 Wood, Percival, 44, Welbeck Street, W.

O.M. *Woodhead, G. Sims, M.D., 6, Scrope Terrace, Cambridge. (C. 1894-5.)

1899 *Worth, Claud, 138, Harley Street, W.

1890 *Wray, Chas., Bank Chambers, North End, Croydon.

1898 †Wright, Edward Wm., M.D., 115, Montague Street, Brooklyn, New York.

1896 Yabr, M. T., Major, R.A.M.C., St. Ives, Farnborough Road, S. Farnborough, Hants.

Digitized by Google

RULES.

1. Object of the Society.—The object of the Society is the cultivation and promotion of Ophthalmology in the United Kingdom, India, and the Colonies.

2. Constitution.—The Society shall consist of Ordinary and Honorary members. All registered medical practitioners of the United Kingdom, and all legally qualified medical practitioners in India and the colonies, whose qualifications are satisfactory to the Council of the Society, shall be eligible as ordinary members.

3. The officers of this Society shall consist of a President, four or more Vice-Presidents, a Treasurer, two Secretaries, a Librarian, and twelve other members, who together shall form the Council and manage the Society's affairs.

4. Ordinary Members.—Candidates shall be proposed on a form provided for the purpose and signed by three members from personal knowledge. The proposal paper shall be read at one Ordinary Meeting, and the Ballot shall be taken at the following meeting. No election shall take place unless ten members vote, and no person shall be elected who does not obtain four fifths of the votes given.

5. Form of Admission by the Chairman.—Members shall be admitted personally by the following form, after signing their names in the Admission Book, and paying their first annual Subscription. *Form of admission.*—"By the authority and in the name of the Ophthalmological Society of the United Kingdom I admit you a member thereof."

6. Honorary Members.—The Council shall have the power of proposing for election as Honorary members men of dis-

Digitized by Google

tinguished eminence in Ophthalmology, or in the sciences bearing upon it. They shall be elected by ballot in the same manner as Ordinary members at the next meeting. The Honorary members shall not exceed ten in number.

7. Resignation of Members.—Any member may retire from the Society after giving notice in writing to the Secretaries and paying any contribution due.

8. Re-admission of Members.—Any member who has retired from the Society and wishes to rejoin it, must be proposed, balloted for, and admitted in accordance with Rules 4 and 5.

9. Expulsion of Members.—A member can be expelled only at a General Meeting especially called for that purpose, and of which a written notice shall have been sent to every member at least fourteen days previously. At least ten votes must be recorded, and four fifths shall carry the expulsion.

10. Subscriptions.—The Annual Subscription shall be One Guinea, payable in advance in the month of October. Each member on election shall pay an Entrance Fee of One Guinea in addition to the Subscription, but in the case of a member elected at a meeting of the Session subsequent to Easter such member shall not be required to pay a Subscription during the next Session.

11. Arrears.—Any member whose Subscription is six months in arrear shall be reminded of the same by one of the Secretaries, and shall cease to be a member if it be not paid within the current year.

12. Composition Fee for Resident Members. — Any member may on entrance pay a Composition Fee of Fifteen Guineas, and be thereby exempted from paying any further Subscriptions, such member enjoying all the rights and privileges of a Subscribing member. After entrance, the Composition Fee will be according to the following scale:— After less than five payments Fourteen Guineas, after five payments Thirteen Guineas, after ten payments Twelve Guineas, after fifteen payments Eleven Guineas, after twenty payments Ten Guineas, after twenty-five payments Eight and a Half Guineas, after thirty payments Seven Guineas, after thirty-five payments Five Guineas, after forty payments Two and a Half Guineas, and after forty-five payments *nil*.

Digitized by Google

13. Composition Fees for Non-Resident Members.—Any member resident out of the United Kingdom may pay a Composition Fee of Seven Guineas instead of the Annual Subscription, and will then be entitled to receive, post free, a copy of the Society's 'Transactions' each year; but if at any time such member subsequently become a Resident member of the Society, payment of the Annual Subscription shall be resumed at the end of six years from the date of election, or if more than six years have elapsed, from the date of return to residence. The question of further composition shall be decided by the Council. N.B.—The Composition Fee will be held to include the Entrance Fee if paid any time during the First Session.

14. Election of Officers.—The Officers of the Society shall be elected yearly by Ballot at the Annual Meeting. A Balloting list of the names recommended by the Council for election shall be sent to each Resident member, together with the notice of the Annual Meeting. In the event of any name being substituted for any recommendation of the Council, the election shall not be valid unless effected by a majority of those present at the meeting. The President shall not hold office for a period of more than two consecutive years. No other member of the Council, except the Treasurer and the Librarian for the time being, shall hold the same office for more than three consecutive years. Any ordinary member of Council who has been absent from all the meetings of the Council for one session shall not be eligible for election to the Council for the ensuing session.

15. Scrutineers.—Two Scrutineers appointed by the President at the commencement of the Annual Meeting shall receive the lists during the first hour, and report the result to the President, who shall have a casting vote.

16. President and Vice-Presidents.—The President shall regulate all the proceedings of the Society and Council, state and put questions, interpret the application of the laws, and decide any doubtful points. He shall check irregularities and enforce the observance of the laws. He shall sign the minutes of General and Council Meetings. In the absence of the President one of the Vice-Presidents, the Treasurer, or some other member chosen by the meeting, shall perform his duties.

Digitized by Google

17. Secretaries.—The Secretaries shall manage all correspondence, shall attend every meeting of the Society and Council, and take minutes, which shall be read at the following meeting. They shall notify to new members their election. They shall arrange with the President the order of proceedings at all the meetings. They shall have charge of and keep a register of all papers communicated, and shall be the Editors of the 'Transactions.'

18. Treasurer.—The Treasurer shall receive all moneys due to the Society, and make all payments ordered by the Council, keeping an account of all such receipts and payments. He shall keep a printed receipt book for the subscriptions, and every receipt shall be signed by himself and countersigned by one of the Secretaries. He shall present to the Annual Meeting a written Report of the financial state of the Society, signed by himself and by two members of the Audit Committee.

19. Librarian.—The Librarian shall have entire charge and control of the Library. He shall purchase books for the Library as opportunities arise at his discretion out of the grant previously voted for this purpose by the Council. He shall see that all books belonging to the Society are duly entered in the Catalogue, and that the periodicals and pamphlets are from time to time, as occasion may require, suitably bound. It will be his duty to see that the Library Rules are not infringed.

20. Audit Committee.—The President, one of the Secretaries, and two members of the Society nominated by the President at some meeting of the Society previous to the Annual Meeting, shall form a Committee to audit the Treasurer's accounts.

21. Meetings of Council.—The Council shall meet immediately after the meetings in October, January, May, and June, and at such other times as they may be specially convened. Three shall form a quorum. The Council shall determine questions by show of hands (or by Ballot if demanded), the President having in both cases a casting vote in addition to his ordinary vote. The Council shall decide upon all questions relating to the reception of communications, and to their publication in the Society's 'Transactions.'

22. Vacancies of Officers.—The Council shall have the power of filling up any vacancies which may occur in any of

Digitized by Google

the offices of the Society between one Annual Meeting and another.

23. 'Transactions.'—A copy of the 'Transactions' shall be sent to each Ordinary member of the Society whose subscription is not in arrear, and a copy of the 'Transactions' shall be sent to each Honorary member of the Society.

24. Meetings.—These shall consist of Ordinary, Clinical, Special, and General Meetings.

Ordinary Meetings.—The business during the first half-hour shall consist of the discussion of cases and card specimens, after which papers shall be read and discussed. Nothing relating to the laws or management of the Society shall be considered.

Clinical Meetings.—One or more of the meetings in each session may be devoted exclusively to the exhibition and discussion of cases and specimens. The number and dates of such meetings shall be arranged by the President and Secretaries.

The bye-laws and regulations relating to Ordinary and Clinical Meetings will be found on page xxxix.

Special Meetings.—At the discretion of the Council an extra meeting may be arranged in order to hold a discussion upon some subject, of which due notice shall be given, or one of the Ordinary Meetings of the Society may be devoted to this purpose.

General Meetings.—The Annual General Meeting, of which every resident member shall receive one week's notice, shall be convened by special summons; ten shall form a quorum. It shall be held immediately after the Ordinary Meeting in July. The business shall consist in the election of Officers, the presentation and adoption of the Annual Report, and the discussion of any proposed alteration of the Rules, notice of which shall be given in the summons convening the meeting. No alteration in the Rules shall be adopted unless four fifths of the votes are given in its favour.

A Special General Meeting may be called at any time, on one week's notice, by the President or any three members of the Council, or on the requisition of fifteen members of the Society. The nature of the business to be transacted at such meetings

Digitized by Google

shall be specified in the summons sent to each member of the Society, and no other business shall be considered.

Dates and Hours of Meetings.—The dates of meetings shall be, unless otherwise determined by the Council, the third Thursday in October, the second Thursday in November and second Thursday in December, the last Thursday in January, the second Thursday in February, the second Thursday in March, the first Thursday in May, the second Thursday in June, and the second Thursday in July. All but the General, Clinical, and Special Meetings shall commence at 8.30, and shall not be prolonged after 10 p.m., except on the proposal of a member, duly seconded, and carried by a show of hands. The hour of all other meetings shall be determined by the President and Secretaries.

25. Visitors.—Each member may introduce as visitors two members of the medical profession to all but the General Meetings. They shall sign their names in the attendance book, opposite to the name of the member introducing them.

26. Order of Communications.—Communications shall be taken in the order in which they have been sent in to the Secretaries, subject to the discretion of the President. If an author be not present when the time arrives for his communication to be read, it shall be dealt with as the President may direct.

27. Publication of Papers and Discussion.—All papers must be sent to the Secretaries at least one week before the meeting, together with an abstract suitable for immediate publication in the journals. When possible, notice should be given relating to card cases, etc. All papers read before the Society shall be deemed the exclusive property of the Society, and if published elsewhere by the author without the express permission of the Council shall thereby be disqualified for admission into the Society's 'Transactions.' No report of the meetings of the Society may be published by members or others without the sanction of the Council.

28. Committee of Reference.—Six members of the Society shall be chosen annually by the Council to act with the Secretaries as a Committee of Reference, and any communication to the Society may be referred by the Secretaries to two

Digitized by Google

or more members of such Committee of Reference for the purpose of considering the fitness of the communication in question to be read before the Society, or to be published in the Society's 'Transactions.'

LIBRARY RULES.

1. The Library shall be open at the same hours as that of the Medical Society, viz. from 1 p.m. to 6 p.m. daily, except on Saturdays, when it will be closed at 3 p.m.

2. Members will be entitled to read the books belonging to the Society at 11, Chandos Street, between those hours, or to take them out on signing a book provided for that purpose. But any books of extraordinary value may be placed by the Council on a separate list, such books not being allowed to be removed from the Library.

3. A large number of the current periodicals will be accessible to members in the Library. These will not be allowed to be taken out of the Library.

4. A book must be returned at the expiration of a fortnight if wanted by any other member. The Librarian will in such a case write to the member in whose name the book was taken out.

5. If the book be not returned within four days of such notice a fine of 6d. will be charged for each day that the book is retained beyond such days of grace.

6. Instruments and drawings cannot be taken out of the Library except with the express permission of the Council.

7. A member taking out a book will be held responsible for its being returned in good condition.

THE BOWMAN LECTURE.

Resolution of Council, September 18th, 1883.

"That in recognition of Mr. Bowman's distinguished scientific position in ophthalmology and other branches of Medicine, and

Digitized by Google

in commemoration of his valuable services to the Ophthalmological Society, of which he was the first President, the Council shall each year, or periodically, nominate some person to deliver a lecture before the Society, to be called 'The Bowman Lecture,' which shall consist of a critical *résumé* of recent advances in ophthalmology or in such subject or subjects as the Council shall select, or of any original investigation, and shall be delivered at a special meeting of the Society held for the purpose, at which no other business shall be transacted."

BYE-LAWS CONCERNING COMMUNICATIONS.

1. The 'Transactions' shall consist of such communications made to the Society by or through members, as may be deemed by the Council suitable for publication. Also of discussions of importance or interest arising out of such communications.

2. No communication to the Society shall occupy more than twenty minutes, and in the subsequent discussion of it no member shall speak more than once, or for more than ten minutes, without the special permission of the Chairman.

3. All communications accepted by the Society become the property of the Society.

4. Communications are admissible which may have been read elsewhere, provided they have not been published, and are not intended to be published, in whole or in abstract, through another channel.

5. The cost of illustrations shall be borne by the Society so far as, in the opinion of the Council, is consistent with the state of its funds.

6. Reprints of papers may be obtained by authors at their own expense, by arrangement with the printer.

Digitized by Google

REGULATIONS CONCERNING THE EXHIBITION OF PATIENTS AND OF PATHOLOGICAL SPECIMENS BY CARD.

A. Patients must attend not later than 8 p.m., and will be allowed to leave at 9.30. A card, provided by the Society, must be placed conveniently near the patient (unless it is undesirable that it should be read by the patient or friends), and on it must be clearly written an account of the case, *comprising all the particulars intended for publication.* The title only of the case will be announced by the President to the meeting, but the Exhibitor (or his representative) must be present at the meeting, and be willing to read the case and furnish additional details if called upon to do so; the length of such oral communications not to exceed five minutes.

The narration and discussion of Card Specimens shall not occupy more than the first half-hour of the meeting.

B. Pathological Specimens may, at the discretion of the Exhibitor, be shown by card, and will then be subject to the above regulations. It is particularly to be noted that the description on the card must *comprise all the particulars intended for publication.*

REGULATIONS FOR CLINICAL EVENINGS.

1. Notice of cases or specimens should be sent in to the Surgical Secretary as early as possible, but not later than the Thursday preceding the meeting.

2. Cases and specimens may be shown without previous notice if there is time, but not until all on the printed list have been disposed of.

3. The number of cases to be shown by any member, and the total number on one evening to be left to the discretion of the President and Secretaries.

4. A list of the cases and specimens to be sent before the meeting to every member in the kingdom.

Digitized by Google

5. Particulars of each case to be fully written out before the meeting, and given to the Secretaries at the close of the meeting.

6. A short abstract of the case to be written on the card provided for the purpose, and placed by the patient.

7. The narration of a case shall not occupy more than five minutes, and in the subsequent discussion no member shall speak more than once or for more than five minutes.

8. Patients and specimens to be in place and ready by 8 p.m., one of the Secretaries being in attendance.

9. That the meeting for the narration and discussion of cases shall commence at 9 p.m.

10. If the exhibitor or a representative be not present the case cannot be taken.

11. A case which has been shown at one of the Ordinary Meetings may be subsequently brought forward at a Clinical Evening.

Digitized by Google

LIST OF COMMUNICATIONS

BROUGHT BEFORE THE SOCIETY DURING THE SESSION 1902-3.

I. DISEASES OF THE EYELIDS.

PAGE

A case of Favus of the upper eyelid.
By E. T. Collins 1

II. DISEASES OF THE CONJUNCTIVA.

1. Papilloma of palpebral conjunctiva.
By S. Stephenson 3
2. Papilloma of ocular conjunctiva. By S. Stephenson 4
3. Tumour of ocular conjunctiva in patient aged 66 years. ? Epithelioma. By A. Ogilvy 5
4. Melanosarcoma of the upper palpebral conjunctiva.
By H. W. Dodd 7
5. The treatment of Trachoma by X-rays.
By S. Mayou 10
6. Lymphangiectasis of conjunctiva.
By A. F. MacCallan 23

III. DISEASES OF THE CORNEA.

1. Cases illustrating an unusual form of corneal opacity, due to the long-continued application of copper sulphate to the palpebral conjunctiva.
By S. Stephenson 25

Digitized by Google

PAGE

2. Zonular opacity of corneæ. By G. Hartridge 27
3. A case of zonular or ribbon-shaped opacity of the cornea. By C. Blair 29
4. A case of mycosis of the cornea. By L. Buchanan 29
5. A case of primary papilloma of the cornea. By C. W. Dean 31
6. Alveolar sarcoma of the cornea. By E. Donaldson 34
7. Endothelioma of cornea. By W. W. Sinclair and J. H. Parsons 35

IV. DISEASES OF THE IRIS.

A contribution to the study of rheumatic iritis. By F. J. Poynton and A. Paine 39

V. SYMPATHETIC DISEASE.

Sympathetic ophthalmitis with cystic changes in the iris. By W. H. Jessop 46

VI. DISEASES OF THE RETINA AND CHOROID.

1. Central serpiginous choroiditis. By L. Werner 48
2. Two cases of tubercular choroiditis. By W. H. Jessop 50
3. ? Tuberculous choroiditis. By Leslie Paton 63
4. Unusual retino-choroidal changes; ? the result of hæmorrhage, and due to fibrinous deposits in the deeper layers of the retina. By A. Lawson 64
5. Case of detachment of retina. By A. Q. Silcock and A. F. MacCallan 66
6. Numerous instances of night-blindness (retinitis pigmentosa) occurring in five generations, with genealogical chart. By S. Snell 68

Digitized by Google

PAGE

7. Retinitis proliferans and detachment of retina. By G. M. Scott 71
8. Aneurismal dilatations on diseased retinal arteries. By J. Herbert Fisher 73
9. Embolism of central artery of retina in a young girl. By N. C. Ridley 74
10. Obliteration of a retinal vessel (vein) with formation of new vessels. By Rayner D. Batten 75

VII. DISEASES OF THE OPTIC NERVE.

1. Two cases of primary intra-dural tumour of the optic nerve, in one of which the tumour was removed by Krönlein's operation, with preservation of the eye. By L. Werner 77
2. A case of family optic neuritis (Leber's disease) in which perfect recovery of sight took place. By E. Nettleship 108
3. Retro-bulbar neuritis and peculiar appearance of retinal vessels. By W. H. Jessop 112
4. Partial atrophy of the optic nerves caused by lightning. By E. T. Collins 114
5. Primary extra-dural tumours of the optic nerve. By J. Herbert Parsons 116
6. Hyaline bodies (*Drusenbildungen*) at the optic disc. By A. S. Morton and J. H. Parsons 135

VIII. DISEASES OF THE ORBIT AND SINUSES.

1. Dermoid cyst of orbit, causing complete dislocation of eyeball. By H. A. Lediard 154
2. Plexiform neuroma (*Elephantiasis neuromatosis*) of temporal region, orbit, eyelid, and eyeball. Notes of three cases, with histological description by E. Treacher Collins. By S. Snell and E. T. Collins 157

Digitized by Google

PAGE

3. Two cases of ptosis associated with disease of ethmoid and sphenoid respectively. By W. H. Jessop 177
4. Nævus of the orbit; evacuation of the orbit after removal of the eye. By W. T. Holmes Spicer 188

IX. PARASITES.

A case of intra-ocular echinococcus cyst with brood capsules. By L. Werner 193

X. COLOUR-BLINDNESS.

1. The tests for colour-blindness. By F. W. Edridge-Green 206
2. On the necessity for the use of colour-names in the test for colour-blindness. By F. W. Edridge-Green 210

XI. PATHOLOGICAL ANATOMY.

1. Case of early formation of true bone in a shrivelled stump. By L. Buchanan 216
2. Ossification of the choroid. By T. Snowball 217
3. Keratitis, with special reference to the part played by the corneal corpuscles. By L. Buchanan 239

XII. CONGENITAL CONDITIONS.

1. Persistent hyaloid artery. By P. Flemming and J. H. Parsons 242
2. Anophthalmos and microphthalmos in a chick. By E. T. Collins and J. H. Parsons 244
3. Rectangular connective-tissue film veiling the optic disc. By N. Bishop Harman 254

Digitized by Google

PAGE

4. A minimal form of fissura facialis. By N. B. Harman 256
5. A rare form of nystagmus. By E. W. Brewerton 260
6. Two cases of aniridia and one of coloboma of the iris in the same family. By C. Blair and B. Potter 261
7. Congenital malformation of lower eyelids. By F. A. C. Tyrrell 263
8. A child with multiple deformities of the eye, eyelids, etc. By R. W. Doyne 263
9. A case of deformity of the head, and proptosis. By E. Donaldson 264
10. Case of congenital maldevelopment of the cornea and sclerotic. By L. Buchanan 267
11. A case of microphthalmos, etc. By R. W. Doyne 269
12. A case of congenital defect of movement of one eye, associated with a slight degree of enophthalmos. By H. L. Eason 269
13. Coloboma of the optic nerve sheath, with microphthalmos. By L. Werner 272
14. Chorio-vaginal veins in the myope and hypermetrope. By W. E. Thomson and A. J. Ballantyne 273
15. Congenital bilateral pigmentation of the cornea. By W. E. Thomson and A. J. Ballantyne 274
16. Congenital (? and hereditary) development of choroidal tissue in the optic nerves of two brothers. By W. E. Thomson and A. J. Ballantyne 276
17. Crater-like hole in the optic disc. By W. E. Thomson and A. J. Ballantyne 277
18. Pigmented colobomata of the optic discs. By W. E. Thomson and A. J. Ballantyne 277

XIII. INJURIES.

1. Thrombosis of the inferior temporal branch of the arteria centralis retinæ in an eye with a persistent hyaloid artery and vein, ? caused by exposure to direct sunlight. By C. H. Walker 279

Digitized by Google

PAGE

2. Traumatic dislocation of eyeball forwards through the palpebral opening; immediate reduction by taxis; complete recovery. By H. C. Baldwin 281
(Communicated by E. Nettleship.)
3. Traumatic separation of the ciliary body, due to rupture of the pectinate ligament. By L. Buchanan 283
4. Concussion injury; coloboma of disc. By G. H. Goldsmith 285
5. A case in which paralysis of the right sixth and seventh nerves was present at birth in a child delivered by forceps; recovery. By E. Nettleship 287
6. Avulsion of eyeball by midwifery forceps. By S. Snell 294
7. A clinical and pathological account of some of the injuries to the eye of the child during labour. By W. E. Thomson and L. Buchanan 296
8. Notes of a case of dislocation of the eyeball. By J. B. Lawford 319
9. A case of pulsating exophthalmos (traumatic). By G. Hartridge 321
10. Blood in the anterior chamber, with staining of the cornea, simulating dislocation forwards of the lens. By E. Clarke 322

XIV. OPERATIONS, INSTRUMENTS, AND APPLIANCES.

1. Subconjunctival fistula formation in the treatment of primary chronic glaucoma. By H. Herbert, I.M.S. 324
2. A new portable perimeter. By G. Brooksbank-James 346
3I. Appliance for electric warmth to the eye. By E. E. Maddox 346
3II. A new adjustable pocket transformer. By E. E. Maddox 349
3III. A circular-shaped lamp resistance. By E. E. Maddox 350
4. A case operated on for conical cornea. By A. S. Morton 351

Digitized by Google

XV. MISCELLANEOUS.

PAGE

1 *a*. The innervation of the orbicularis palpebrarum muscle. By N. B. HARMAN 356

1 *b*. Associated "jaw-winking" movements. By N. B. HARMAN 369

2. A case of acromegaly with bitemporal hemiopia, showing the changes that have taken place in the visual fields after four months' treatment with pituitary body tabloids. By A. LAWSON 373

3. Report of five cases of glaucoma in which adrenalin caused an increase of tension. By A. F. MACCALLAN 374

4. Tumour in region of yellow spot. By W. H. JESSOP 384

5. Cerebral degeneration with symmetrical changes in the maculæ in two members of a family. By F. E. BATTEN 386

6. Two drawings of normal fundi, illuminated by means of a mercury vapour lamp. By M. S. MAYOU 390

7. Paralysis of the upward movement of the eyes. By S. SNELL 391

8. Intra-ocular hæmorrhage in each eye of a young man; recurrence. By R. W. DOYNE 395

APPENDIX 397

REPORT OF THE COUNCIL (INCLUDING TREASURER'S BALANCE-SHEET) 399

NOTICE TO MEMBERS 402

INDEX 403

Digitized by Google

LIST OF PLATES.

PLATE		FACING PAGE
I.	Fig. 1. A case of favus of the upper eyelid. (E. Treacher Collins.) (Page 1) . . Fig. 2. Corneal opacity. (S. Stephenson.) (Page 25) . . . . Fig. 3. A case of primary papilloma of the cornea. (C. W. Dean.) (Page 31) .	3
II.	Tumour of ocular conjunctiva in patient aged 66 years; ? epithelioma. (A. Ogilvy.) (Page 5)	5
III.	A contribution to the study of iritis. (F. J. Poynton and A. Paine.) (Page 39) .	39
IV.	Central serpiginous choroiditis. (L. Werner.) (Page 48)	48
V.	Fig. 1. Aneurismal dilatations on diseased retinal arteries. (J. H. Fisher.) (Page 73) Fig. 2. Obliteration of a retinal vessel (vein) with formation of new vessels. (Rayner D. Batten.) (Page 75) . . .	73
VI.	Two cases of primary intra-dural tumour of the optic nerve. (L. Werner.) (Page 77) .	77
VII. VIII.	Plexiform neuroma (elephantiasis neuromatosis) of temporal region, orbit, eyelid, and eyeball. (S. Snell and E. T. Collins.) (Page 157)	163
IX. X.	A case of intra-ocular echinococcus cyst with brood capsules. (L. Werner.) (Page 193)	197
XI. XII.	Keratitis, with special reference to the part played by the corneal corpuscles. (L. Buchanan.) (Page 239)	240

Digitized by Google

PLATE		FACING PAGE
XIII.	Anophthalmos and microphthalmos in a chick. (E. T. Collins and J. H. Parsons.) (Page 244)	244
XIV.	Fig. 1. Rectangular connective-tissue film veiling the optic disc. (N. Bishop Harman.) (Page 254) . . . . . Fig. 2. A minimal form of fissura facialis. (N. Bishop Harman.) (Page 256) . .	254
XV.	Fig. 1. Hyaline bodies at the optic disc. (A. S. Morton and J. H. Parsons.) (Page 135) . Fig. 2. Cerebral degeneration with symmetrical changes in the maculæ in two members of a family. (F. E. Batten) (Page 386) .	135
XVI.	Fig. 1. Crater-like hole in optic disc. (E. Thomson and A. J. Ballantyne.) (Page 277) . Fig. 2. Pigmented coloboma of the optic discs. (E. Thomson and A. J. Ballantyne.) (Page 277)	277
XVII.	A clinical and pathological account of some of the injuries of the eye during labour. (W. E. Thomson and L. Buchanan.) (Page 296) .	303
XVIII.	Two drawings of normal fundi, illuminated by means of a mercury vapour lamp. (M. S. Mayou.) (Page 390) . . .	390

Digitized by Google

LIST OF DIAGRAMS, ETC., IN TEXT.

FIG.		PAGE
1.	Mycosis. (L. BUCHANAN)	30
2.	Tumour of optic nerve: before operation. (L. WERNER)	78
3.	,, ,, after operation. ,,	79
4—10.	Plexiform neuroma. (S. SNELL)	158—167
11.	Nævus of orbit. (HOLMES SPICER)	189
12, 13.	Intra-ocular Echinococcus cyst. (L. WERNER)	194, 195
14.	Proptosis. (E. DONALDSON)	265
15.	Visual field. (C. H. WALKER)	280
16—22.	Innervation of the orbicularis muscle. (N. BISHOP HARMAN)	359—364

Digitized by Google

BOSTON MEDICAL
OCT 7 1909
LIBRARY.

REPORTS.

I. DISEASES OF THE EYELIDS.

A case of Favus of the upper eyelid.

By E. Treacher Collins.

(With Plate I, fig. 1.)

History.—John S—, æt. 16 years, a healthy-looking lad, came to the Royal London Ophthalmic Hospital (Moorfields) on January 12th, 1903, on account of an affection of the skin of the right upper eyelid.

He stated that fourteen days previously he noticed a little red pimple, which, after he rubbed it, had become sore. Later other spots appeared.

A source of infection was carefully inquired for, but none could be ascertained. The boy's cat was examined, but it presented no affection of the skin, and its hairs showed, microscopically, nothing abnormal.

Condition when first seen.—On the skin of the outer portion of the right upper lid, about midway between the free margin and the line of the brow, were four circular patches. They were composed of a dry crust, the centre of which was somewhat depressed and black, the margin slightly raised above the level of the surrounding skin, and of a bright, sulphur-yellow colour.

The smallest patch, measuring 4 mm. in diameter, was perfectly round. The largest, 7 mm. in diameter, had a

Digitized by Google

scalloped margin, and looked very much like a piece of lichen. The other two patches were becoming confluent. No hairs could be seen connected with any of them. The surface of all of them was quite dry, there being no discharge. The skin for some distance surrounding the patches was red and inflamed.

Subsequent history.—On January 13th the appearance of the patches was practically unchanged. The water-colour drawing was then made (see Plate I, fig. 1).

Syrup of the phosphate of iron was prescribed, but no local treatment.

On January 22nd the dry crusts had to a great extent disappeared; they had lost their characteristic sulphur colour. The skin of the lid was still inflamed.

January 29th.—The crusts from the eyelid have quite disappeared. Some fresh patches are commencing to form on right lower lid, left side of chin, and back of neck.

Pathological examination.—A portion of one of the crusts, prepared for microscopical examination by Mr. J. H. Parsons, shows a branching mycelium composed of ovoidal segments and numerous spores. A portion of a crust planted on maltose agar gave rise to a growth characteristic of the favus fungus, but somewhat contaminated.

(*Card Specimen. January 29th,* 1903.)

Digitized by Google

Digitized by Google

PLATE I.

Fig. 1 illustrates Mr. E. Treacher Collins's case of Favus of the Upper Eyelid (p. 1).

Fig. 2 illustrates Mr. Sydney Stephenson's cases of Staining of the Cornea by Copper Sulphate (p. 25).

Fig. 3 illustrates Mr. C. W. Dean's case of Primary Papilloma of the Cornea (p. 31).

Digitized by Google

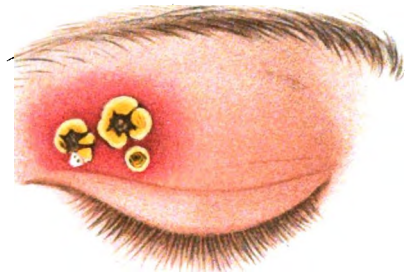

M. H. Brooks, del. Fig. 1.

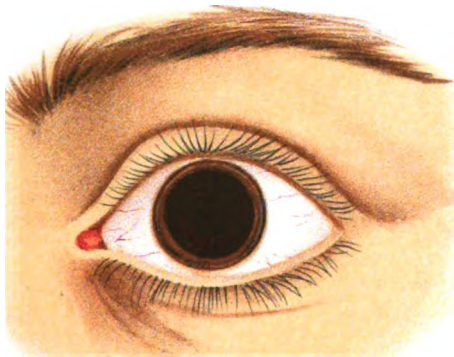

A. W. Head, del. Fig. 2.

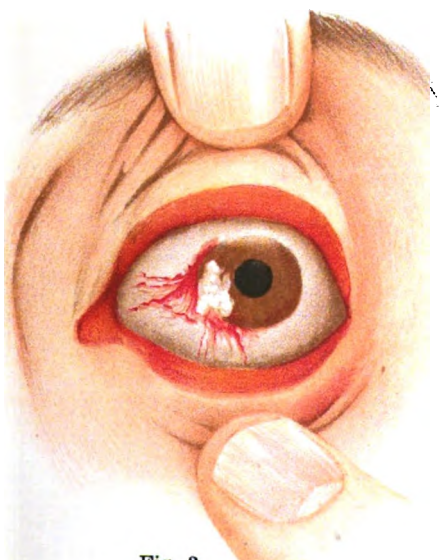

P. Nairn, del. Fig. 3.

Bale & Danielsson, Ltd.

Digitized by Google

Digitized by Google

II. DISEASES OF THE CONJUNCTIVA.

1. *Papilloma of palpebral conjunctiva.*

By Sydney Stephenson, M.B.

Charles R—, æt. 48 years.

Personal history.—Suffered from gonorrhœa fifteen years ago, but denies syphilis. States that he enjoys good health, except that he is subject to chronic bronchitis in the winter. Scrofulodermia in neck.

History of eye affection.—The patient states that he noticed "a tiny wart" upon his right upper lid five years ago. The growth has been cut off on three or four occasions. He complains that the affected eye is always running with water, especially when out of doors. He has noticed a growth in his mouth for about the same time.

Present state.—R.: a strawberry-like growth, of red colour, is to be seen projecting from the palpebral fissure at the junction of the inner third and the outer two-thirds of the upper lid; it is perhaps the size of a small pea. The eye looks "weak" and is watery. Upon everting the upper lid, the growth is found to arise from the upper tarsal conjunctiva, a few millimetres from the free edge of the lid; it is not adherent to the intermarginal space, which it merely overlaps. A similar but much smaller growth arises from the tarsal conjunctiva at about the junction of the outer third with the inner two-thirds of the upper lid. It is sessile, and has no outlying piece projecting beyond the lid itself. Lastly, there are several small

Digitized by Google

growths of similar nature situated about the semilunar fold and the inferior punctum lacrymale. Broadly speaking, all the growths may be described as reddish, granular, and papillated. It is to be particularly noted that a papillomatous growth, showing macerated epithelium, is present on the right side of the hard palate, about half an inch from the last molar tooth of the upper jaw. In transverse diameter it is equal to about three-eighths of an inch.

Pathological examination of the growth (by Mr. R. Moorsom Wood).—The sections show that the tumour is a papilloma. It consists of a mass of branching processes running in various directions, so that in the sections they are cut at various angles. Each branching process is made up of delicate strands of connective tissue supporting the numerous blood-vessels which run into each process. The free surfaces of the processes are covered by several layers of large epithelial cells, the superficial layers of which are of stratified epithelium; the inner layers are more cubical, and the innermost layer rests upon a definite basement membrane. (*May 7th*, 1903.)

---

2. *Papilloma of ocular conjunctiva.*

By Sydney Stephenson, M.B.

Henry B—, æt. 45 years, attended Mr. R. W. Doyne's out-patients at the Royal Eye Hospital on May 18th, 1903, complaining of his left eye. The patient was a plasterer by occupation, and in the course of his work had on several occasions got sand, mortar, lime, etc., into the affected eye. Some six weeks after a slight injury of this sort the patient had noticed "a small red speck" in his left eye. This was about two years ago, since when the appearance has become more marked.

Digitized by Google

Digitized by Google

PLATE II.

Illustrates Mr. A. Ogilvy's case of Epithelioma of Ocular Conjunctiva (p. 5).

Digitized by Google

Adlard & Son, Imp.

Digitized by Google

Digitized by Google

Present state.—L.: extending from the inner canthus to the lower inner edge of the cornea is a bunch of red material. On everting the lower lid, several grouped papillomata are seen in the ocular conjunctiva, and one outlying mass is visible in the outer half of the same membrane. The growths that lie beneath the lid are flattened, presumably as the result of the pressure to which they are exposed by reason of their position. On the other hand, those that lie in the palpebral fissure are more prominent, and one at least is distinctly papillated. Several small conjunctival vessels meander amongst the growths composing the main mass.

Pathological report.—The specimen showed the usual structure of a papilloma, *i. e.*, a mass of finger-like processes composed of layers of stratified epithelium, with a small amount of connective tissue, carrying blood-vessels, running into each process.

(*Card specimen. June 11th,* 1903.)

---

3. *Tumour of ocular conjunctiva in patient aged 66 years; ? epithelioma.*

By A. Ogilvy, M.D.

(With Plate II.)

Patient was first seen December 18th, 1902, when he complained of what seemed to be an ordinary pterygium at inner side of left cornea. This had existed for two or three months. Advice was sought because he thought the "pterygium" was more inflamed than usual, and his friends believed it was encroaching on the cornea. Sulphate of zinc drops were used to lessen inflammation, at first with

Digitized by Google

success. Later on it again became inflamed, and on January 30th, 1903, it was dissected from the cornea and turned back, leaving a space of sclerotic about 3 mm. diameter exposed. This healed up in the usual way, but out of the cicatrix a small granulation grew about the size of a large pin-head, but white in colour. This was thought to be an ordinary granulation, and was snipped off on March 7th, 1903. The granulation tissue reappeared in a few days, and grew rapidly till it was 4 mm. in diameter and about 2 mm. in thickness. Second growth removed on April 12th, 1903, and from it microscopic sections were made. The base was carefully pared away until there was apparently no trace of the growth left. Notwithstanding this, the tumour reappeared within a week, and has gone on until now, when it measures 15 mm. by 12 mm. by 3 mm. Tumour is sessile, hard, very few vessels; it encroaches on cornea for 2 mm.; edges slightly overlapping. There is very little interference with eyeball. Vision = $\frac{5}{6}$ $\bar{c}$ + 2·5 J. 1. There is scarcely any pain, and no glands are infiltrated. Chronic dacryocystitis of old standing.

The patient's right hand and arm are covered with warts, and at first it was thought he had infected the wound from one of these, hence the diagnosis of papilloma.

He is being treated with sodium arsenate in large doses, and X-rays applied locally to the tumour, but up to the present (one month) without any marked result, unless that the centre of the tumour appears to be breaking down, or at any rate to be getting thinner.

The section showed epithelial cells, but no cell nests.

The sequel to the case will be published later.—A. O.

(*Card specimen. June 11th*, 1903.)

Digitized by Google

4. *Melanosarcoma of upper palpebral conjunctiva.*

By H. Work Dodd.

This patient, a woman æt. 83 years, was admitted into the Royal Free Hospital complaining of a lump in the left upper eyelid. She first noticed it there "as a little thing" about six weeks before she came up to the hospital. In the beginning there was no pain, but after about three weeks, as the growth became larger, pain developed. There was also a slight discharge. There is no family or personal history bearing on the condition.

On admission.—The left upper eyelid is bulged forward by a growth about the size of a hazel-nut. There is a dark patch, about half an inch in diameter, apparently due to the growth showing through the skin of the eyelid in its middle part. The skin is quite free from the growth. There is neither redness, nor œdema, nor tenderness. On raising the upper eyelid, a growth can be seen on its under surface, which is soft in consistence, somewhat jelly-like in appearance, dark and vascular, bleeding readily on manipulation. The eyeball is nearly hidden by the growth, but its movements do not appear to be limited. There is no glandular enlargement nor any evidence of secondary growths. The patient has several wart-like growths about her body. Being of opinion that the tumour was malignant, I decided to remove the whole of the contents of the orbit, including the upper lid to the eyebrow, but leaving a little of the lower lid *in situ*.

This operation I subsequently performed, and the patient recovered quite satisfactorily. About a fortnight later, my house surgeon, Mr. Cunning, skin-grafted the orbit after the manner of Thiersch, and in a few days this graft had adhered everywhere.

Digitized by Google

Report by Mr. L. Woodcock, *Pathologist, Royal Free Hospital.*

Macroscopic Report.—The tumour is seen to protrude between the upper eyelid and eyeball; it is about the size of a large hazel-nut, measuring $\frac{3}{4} \times \frac{3}{8}$ inch; the skin of the upper eyelid is movable over the tumour. It is attached to the under surface of the upper lid, $\frac{1}{2}$ an inch from the fornix, and $\frac{1}{8}$ of an inch from the free margin of the eyelid (antero-posterior section in mid-line).

The unmounted section shows that it is stalked. The tumour is rather soft in consistence, with a smooth surface, which is somewhat friable below. Parts of the tumour are coal-black, parts are colourless, and parts are reddish, owing to areas of hæmorrhage.

Microscopic Report.—Microscopically the anterior and lower free surface of the growth is seen to be covered with conjunctival epithelium (traced in various sections); this consists in some places of cubical cells, in others of flattened cells, two or three layers thick. The conjunctiva is not traceable posteriorly over the tumour, and appears to be replaced by a fine connective-tissue capsule. The tumour has a large extent of free surface, and is attached in front to the upper border of the tarsal plate, and by dragging on this attachment has doubled it over into a horseshoe shape.

The tumour cells are seen right up to the edge of the tarsus, but do not infiltrate it. Posteriorly it is attached to the connective tissue underlying the orbicularis muscle. It has not infiltrated any of the tissues of the eyelid, but has isolated itself by means of a stalk. It is divided in antero-posterior section into two parts by a connective-tissue strand; a posterior part, composed of large, round, oval, and polygonal cell elements, set in a fine stroma; the nuclei are vesicular, containing one or more nucleoli. These cells contain no pigment, but there are extravasations of blood between them. The anterior part is pigmented, and consists of masses of epithelial-like sarcomatous

Digitized by Google

cells, with no definite cell outlines, and small round-cells. These cells contain vesicular nuclei of very varying shapes and sizes. The pigment consists of brown and black amorphous granules, coarse and fine, which lie in the cell protoplasm, a clear space being left for the nucleus. The cells which contain the pigment are of very various shapes, large, round, and oval, and many are fusiform, with long branching processes, which are continuous ($\frac{1}{12}$ oil immersion) with a fine network, on which are set refractile granules and fine pigment granules. These cells correspond to the "chromatophores" described by Depué. The pigment is iron-free, *i. e.*, sections stained with potass. ferrocyanide and hydrochloric acid give no Prussian-blue reaction. It is therefore not hæmosiderine, or altered blood-pigment, but true melanin.

Remarks.—Primary sarcoma of eyelid is rare; according to Norris and Oliver, there are forty-five cases recorded in literature; according to Cappellini (*Annali di Ottalmologia*, 1900) thirty cases, ten of which are melanotic. Four of these originated from the palpebral conjunctiva.

Van Duyse (*Annales d'Oculistique*, tome lxxviii, 1887) quotes four cases as arising from palpebral conjunctiva. (1) That of Horner, reported in *Klin. Monatsbl. f. Augenh.*, 1871, tome ix. Patient æt. 64, tumour a melanosarcoma, pedunculated on right upper eyelid. Tumour spherical, size of walnut, with smooth surface, and soft in consistence. The stalk is the size of a little finger, the front surface of which is partly covered with a Meibomian gland-layer. . . . . On cross-section the tumour is partly colourless, partly grey-brown. The cells are partly fusiform, partly round and polygonal (*vielgestaltig*). Extravasations of blood throughout tumour. (2) That of Talko. From upper eyelid—non-pigmented small spindle-celled sarcoma—*pedunculated*. Reported in *Klin. Monats. f. Augenh.*, t. xi, 1873. (3) That of Chisholm. Patient æt. 5. Tumour size of cherry, non-pigmented, inserted into fornix by *short stalk*; recurred in three months.

Digitized by Google

Reported in *Annales d'Oculistique*, t. lxxxv. (4) That of Ceppi. A round-celled sarcoma, size of large nut (composed of two or three distinct lobes), which was free and mobile in all its extent, and only adherent at its summit to the palpebral conjunctiva. (5) Lastly, van Duyse's own case. Patient æt. 48. Melanosarcoma size of haricot bean—spindle-celled.

Van Duyse deducts from the above cases—

(1) That of the few sarcomata described as arising from the palpebral conjunctiva most are pedunculated, and remarks that other sarcomata when arising from skin or mucous surface take on a papillary form.

(2) That these tumours attain a considerable size before extending to the tissues anterior to them.

The fact that the tumour shown (*a*) is pedunculated, (*b*) that it has sought the free surface, leaving the skin, orbicularis muscle, and tarsal plate intact and healthy, points to its origin from the palpebral conjunctiva.

(*June 11th*, 1903.)

---

5. *The treatment of Trachoma by the X-rays.*

By Stephen Mayou.

Whilst watching the clinical and histological changes which take place in rodent ulcer* and lupus of the eyelid under X-ray treatment, and finding no serious injurious effect on the globe or other structures, it occurred to me that it might be possible to apply this form of tissue stimulation to other diseases of the eye, more especially to trachoma and corneal opacities. With that idea a case of severe bilateral trachoma was, in April, 1902, admitted

* *Transactions of the Pathological Society*, 1902.

Digitized by Google

to King's College Hospital under the care of Mr. L. V. Cargill, who kindly handed it over to me for treatment.

After twenty-four exposures to the X-rays the disease disappeared, and the patient remains well up to the present date. This case was shown at this Society last June.* Encouraged by this case I treated some fifteen others, upon which I read a paper before the Röntgen Society in December, 1902.† Since that date four successful cases have been published by Mr. Sydney Stephenson and Dr. Walsh,‡ to the former of whom I had the honour of explaining the *technique* of the treatment as carried out in my first case.

I also know of one or two other unpublished cases in which the treatment has been successful.

In order to obtain the best possible result from any form of treatment it is essential to know the exact pathology of the disease which is being treated, and also the action on both normal and diseased tissues of the agents used. In treating trachoma by X-rays we therefore fall short to some extent in both directions. The pathology of trachoma, so far as it has at present been investigated, is well-known, but before going on to its treatment some of the effects of X-rays on tissues may be briefly mentioned.

An electric spark is extremely rich in ultra-violet rays. X-rays are produced by allowing an electric spark to pass through a vacuum between two platinum poles; from the antikathode are given out rays which have the peculiar property of not being refrangible, and therefore their wave-length cannot be measured; but, according to Jackson, there is every reason to believe that their wave-length varies; this is also borne out by their effect on the tissues. It is now almost beyond a doubt that the rays which produce inflammatory changes in the tissues are not those which penetrate the body, and by which skiagrams are

* *Transactions of the Ophthalmological Society*, 1902.

† *Archives of the Röntgen Society*, Jan., 1903.

‡ *Medical Press and Circular*, March, 1903.

Digitized by Google

taken, because—First, high vacuum tubes which have the most penetrating power have least effect on the tissues, and *vice versâ*; and secondly, although there are marked changes in the superficial tissues of areas exposed, there seem to be no changes in the deeper tissues.

With regard to the effect of X-rays on healthy living tissues exposed to their action, the most notable change produced is an irritation, which is entirely superficial, and does not seem to affect much beyond the main vessels supplying the skin; the capillaries of the area also become dilated, and there is an enormous exudation of leucocytes. This inflammatory change may be anything from a mild leucocytosis to an actual gangrene, according to the amount of exposure. It seems to be brought about in exactly the same way as by other forms of stimuli—chemical, mechanical, electrical, or thermal,—and the first three degrees of burns as described by Dupuytren compare admirably with the various degrees of so-called dermatitis produced by X-rays.

But the application of X-rays differs from all these other forms of stimuli in being painless; this may be due to the fact that the stimulus is very slight although prolonged, or it may be that the nerve-endings in the skin cannot appreciate it. The inflammation produced differs also in that it is more persistent than in an ordinary burn, and the smaller vessels of the part become permanently dilated after prolonged exposure. The changes do not make themselves apparent till from one to three weeks after exposure, and therefore care must be taken not to over-expose the part before reaction fully sets in. These changes are intensified and more rapidly brought about by the simultaneous application of irritants, such as copper sulphate, etc.; and, conversely, if a part is already irritated or inflamed, its reaction to X-rays is much greater. This will account for the enormous leucocytosis seen around the epithelial cells in rodent ulcer cured by this method, and also the same thing is seen to occur around

Digitized by Google

the nodules in trachoma, the rodent cells and trachoma nodules acting as irritants.

To come next to the effects of X-rays on the eye, taking instances of prolonged exposure.

In a case of rodent ulcer shown at this Society last year in which, owing to the contraction causing ectropion of the lower lid, the globe was exposed for eight months to the action of X-rays, ten minutes' exposure four times a week being given, no ill effect on the media, iris, or fundus could be detected, the vision remaining $\frac{6}{9}$ throughout the treatment. In another case of rodent ulcer involving the margin of the lid, which was exposed for two and a half months, averaging three times a week for eight minutes, no effect on the globe was noted, although it was examined frequently, the vision remaining $\frac{6}{6}$ throughout the treatment; this is a year ago, and the eye still remains healthy. Two other cases similar to these have been examined and no change found.

In all the above cases an acute conjunctivitis was produced, and this is also seen among men employed in X-ray work, but it is easily prevented in them by the use of lead-glass spectacles. The conjunctivitis was very acute in some instances, and was often of the purulent variety. Nearly all the eyelashes fell out, owing to an inflammatory change round the hair-follicles, but came again readily after cessation of the treatment. With the amount of exposure required to cure trachoma, however, neither of these effects need be produced.

Fuch and Kreidel,* in 1896, showed that there was no bleaching of the visual purple by X-rays; possibly this might have been expected, seeing that the photographic action of X-rays is dependent on the fluorescence they produce. Since the tubes at that date were probably not so powerful as those now in use, I have recently made somewhat similar experiments on rabbits and frogs.

In the case of the rabbits, the animals were kept in the

* *Centralblatt für Physiologie*, Leipzig, Wien, 1896, Bd. x, S. 249.

Digitized by Google

dark for four hours, and then killed with $CHCl_3$, and both eyes were enucleated in a dark room under a ruby light. One eye was then exposed to the action of the X-rays for half an hour (8 amp., 3-inch spark-gap) at a distance of six inches, the eye being covered by a black cloth so as to screen off the light rays. Both eyes were put for three to five minutes in iced saline solution to inhibit the bleaching of the visual purple. The anterior halves of both eyes were then removed and evaginated on the finger tip, and examined by an electric arc lamp, such as is used in the Finsen treatment of lupus; there was no bleaching of the visual purple found in either eye. A small scratch was made on the surface of the retina of the eye that had not been exposed to the X-rays, so that by bleaching of the visual purple through the injury a comparison of colour could be made; the visual purple took about one minute to disappear under the influence of the light.

In the case of the frogs, the eyes were similarly enucleated and exposed. The entrance of the optic nerve was then button-holed, and the anterior half of the globe removed, the retina being withdrawn with the vitreous, mounted in saline solution on a slide without a cover-glass, and examined with the microscope. No bleaching of the visual purple was seen, but it disappeared slowly under the influence of the light in from twenty minutes to half an hour.

At the present time trachoma is cured by applying some form of irritant to the lid, either by chemical means such as copper sulphate or corrosive sublimate, or mechanically by rolling, brushing, or other operative methods. These irritants must act in one of two ways:

1. Simply by the reaction they set up, partly causing a leucocytosis and subsequent cicatrisation of the nodules, and partly by mechanically removing the diseased tissues.

2. By direct action on the organism causing the disease, if such organism be present.

Taking the former of these, the method commonly adopted is the application of copper sulphate or some mild

Digitized by Google

caustic. At each application the epithelium of the conjunctiva is damaged, and although the trachoma is cured, an excessive amount of scar tissue is left, and thickening of the epithelium is seen in almost all cases so treated.

As regards rolling, brushing, and other operations, they have the additional advantage of removing the actual diseased tissue, but it is generally recognised that they are only suitable for certain cases, and that even in those cases the cure is not generally complete unless they are followed by some form of caustic to keep up the irritation started by the operation.

In X-rays we have a method of setting up a leucocytosis with the absolute minimum of destruction to epithelial and other tissues; and, further, we have a means of producing an inflammation, varying from a very slight leucocytosis to an actual gangrene of the part, which, with due care and experience, we have under almost perfect control.

Not knowing the organism which causes trachoma (if such organism exist) we cannot say whether the irritants which are used in its treatment, or X-rays, have any effect on it. But we have in X-rays a method of producing leucocytosis in any degree, from that corresponding to a mild application of perchloride of mercury up to that induced by jequirity; and, further, this leucocytosis is much more prolonged than in any method formerly adopted, and the destruction of tissue is not nearly so great.

Although granules disappear very rapidly under X-rays, operative methods, which have the additional advantage of removing the diseased tissue, may be preferable to some extent, except that the patient has to undergo an operation, but such operations can be followed by X-rays to complete the work in preference to one of the other irritants now in use. But operation should never follow X-ray treatment without considerable interval, owing to the great reaction which is set up.

In the first case the method adopted was to cover the whole face, with the exception of the affected eye, with a

Digitized by Google

metal mask.* The upper lid is everted, and the lower lid pushed up so as to cover as much of the cornea as possible, but in bad cases of pannus the cornea is left exposed; I have never had any trouble with the globe following X-ray treatment.

The operator's hands are protected with bismuth ointment and cotton gloves, a separate pair of which is kept for each case.

The patient is seated about nine inches from the anode, with a moderately soft tube and a current of 6 amp. Four minutes' exposure is given for four to six successive days, depending on the case. If there be much injection or the case be an acute one, four is generally sufficient. A week's rest is then given, and, if no reaction be set up, the patient is exposed three to five times a week until there is a slight increase in the photophobia, which shows that the patient is beginning to react. About this time the granules begin disappearing from the lids. Exposures are carried out until they disappear. When the granules have disappeared, all treatment must be stopped, as it requires some weeks for the infiltration set up by the X-rays to settle down, and it is difficult to tell whether the disease is absolutely eradicated, as the lid remains injected for some time after treatment has ceased.

The final result to the lid is most satisfactory. Instead of the white, puckered conjunctiva gained by other methods, a supple, non-contracted, non-scarred conjunctiva, with no obliteration of the fornices, unless they are already gone before treatment, is gained, similar to the soft, supple scar in the skin produced by this form of treatment in rodent ulcer, as compared with the dense cicatrix of excision.

As regards the effect on pannus, it often clears with great rapidity, especially if recent, and it is a common thing for patients to say that they see more clearly from almost the first exposures. But even dense corneal

* Since then I have discarded the mask altogether, as now the patient is never exposed sufficiently to get any reaction in the skin.

Digitized by Google

opacity will often clear considerably, and in one case of extensive destruction and cicatrisation of the cornea following thirty years of trachoma, in which at the commencement of treatment the patient could only see shadows, in two months she could count fingers three feet away.

Another peculiar point is the amount of exposure required by different patients. Sometimes the granules begin to disappear from almost the first exposure; others require eight or ten or more exposures before showing signs of reaction.

As regards the cases suitable for treatment, the most satisfactory are the subacute and chronic cases, and of course the earlier they seek treatment the more rapid and satisfactory the result. These patients will stand more frequent exposure than any others; acute diffuse infiltrations with thickening of the lids and much photophobia require more careful exposure, extending over a much longer period. Old-standing cases in which the lid trouble has almost disappeared, but in which there is much opacity of the cornea, will often improve considerably under exposures of long intervals after the first reaction, which should be mild.

The chief advantages of this treatment are—

1. There is considerably less deformity of the lid after treatment.
2. It is practically painless treatment.
3. Pannus clears more thoroughly.

The chief disadvantages are—

1. All patients do not react well to X-rays.
2. It is difficult to say when to cease treatment.*

I have added as an appendix an abstract of the notes of the first nine cases treated by this method, for one of which I have to thank Mr. A. D. Reid, assistant radiographer to King's College Hospital. Of these eight rank as trachoma, the ninth case being one of corneal

* This was especially marked in the first few cases treated, some of which recurred, but cleared up under further treatment.

Digitized by Google

opacity following the disease. Of the eight cases of trachoma, five have entirely cleared up. One case, although clearing up, recurred and could not attend for further treatment. Two cases reacted only slightly to X-rays, but the corneal trouble improved greatly. The granulations also improved, but have not entirely disappeared.

I have to thank Mr. Cargill for his kindness in sending me cases, and also for his opinion on them during and after the treatment.

Appendix.

Case 1 (abstract from *Ophthalmological Society's Transactions*, 1902).—E. G—, æt. 14 years, female.

Possible source of infection.—One sister with weak eyes.

Duration.—Left eye five years. Right eye four and a half years.

Previous treatment.—Has been attending various eye hospitals during that time without improvement. Admitted to King's College Hospital April 5th, 1902.

Condition.—Both eyes.—Photophobia and ptosis well marked. *Left eye.*—Upper lid and fornices covered by large flat granules. Well-marked scarring in region of sulcus subtarsalis. Cornea entirely covered by thick fleshy pannus, except in d. and i., which was ulcerated. *Right eye.*—Lids and fornices, granules not nearly so marked. Pannus in upper third of cornea only.

Left eye treated with X-rays from April 11th, 1902, to May 1st, 1902. Fourteen exposures, 5 minutes, 4 amp., granules had gone from the lids. Right eye, which had been treated by $CuSO_4$, had not improved to the same extent, although the better eye. Eight more exposures given. Pannus much improved. Remained well till June 14th, when there was a slight recurrence, which cleared under four more exposures to X-rays, and has remained well since the end of June. On comparing the lower fornices of the two eyes it will be seen that the

Digitized by Google

left shows less sign of contraction (although by far the worse eye), the pannus having cleared to a far greater extent in comparison with the right eye. Ptosis remains. (Patient shown.)

Case 2.—E. P—, 30 years, male. Source of infection not known.

Previously treated for trachoma of right eye, which is now well.

Left eye has been treated with $CuSO_4$ for eighteen months previously; symptoms first appeared in 1899. Slight photophobia and ptosis. Large flat granules over surface of upper lid and fornices; pannus over upper third of cornea. X-ray treatment from July 17th, 1902, to October 10th, 1902. Fourteen exposures, 3 minutes, 4 amp., "low tube." Granules showed signs of improvement after 4 exposures. Patient remains well. (Patient shown.)

Case 3.—S. C—, 28 years, German Jewess. Source of infection not known. Both eyes previously treated for two years at various hospitals with $CuSO_4$. Some photophobia and ptosis in both eyes.

Right eye: few large granules, no pannus, some scarring in sulcus subtarsalis; not much obliteration of fornices. Left eye: well-marked granules in superior fornix and upper lid; not much obliteration of fornices.

X-ray treatment from October 15th, 1902, to November 4th, 1902. Six exposures, 4 minutes, 4 amp., "low tube." All the granules had gone, but the lids still remained injected. Discharged. Returned January 19th, 1903. Slight recurrence in the right eye, which is now nearly well.

Case 4.—A. B—, male. Right eye: well-marked trachomatous granules in superior fornix and upper lid. Pannus upper third of cornea. Not much obliteration of fornices. Intense photophobia.

Digitized by Google

X-ray treatment from January 5th, 1903, to February 2nd, 1903. Twenty-one exposures given. Granules gone; pannus almost entirely cleared. Lids remain somewhat injected. Remains well. Photophobia disappeared after six exposures.

Case 5.—E. W—, æt. 50 years, female. Source of infection not known. "Weak eyes for some years."

Treated previously for one month with $CuSO_4$. No improvement. Intense photophobia.

Both eyes: obliteration of fornices well marked, especially lower. Large flat granules, with much infiltration of the lids; pannus upper third.

X-ray treatment from October 1st, 1902, to January 5th, 1903. Twenty-one exposures, 4 minutes, 4 amp., "low tube." Improvement began after fourteen exposures. Remains well.

Case 6.—A. A—, æt. 17 years, male. Source of infection from sister, who also has trachoma.

Both eyes: four years' duration. Steadily getting worse after three years' treatment at two ophthalmic hospitals.

Diffuse thickening of both conjunctivæ; few large granules; pannus upper half both corneæ; much ulceration; intense photophobia.

X-ray treatment June 9th, 1902, to July 9th, 1902. Thirteen exposures. Much improvement; granules and photophobia gone; ulcers healed; pannus clearing. Discharged. February 10th, 1903.—Returned with well-marked recurrence in both eyes, but could not attend for further treatment.

Case 7.—E. K—, æt. 20 years. Source of infection not known.

Right eye two years' duration; left eye seven months. Both treated previously with $CuSO_4$.

Both lids and fornices covered with granules. Ptosis

Digitized by Google

and photophobia. Well-marked scarring; fornices obliterated. Diffuse superficial haze throughout both corneæ. Very slight vascularisation.

X-ray treatment July 15th, 1902, to February 6th, 1903. Forty-one exposures, 4 minutes, 4 amp. The granules have nearly gone from the lids, and the corneæ have cleared considerably. This case, together with the following one, is remarkable for the small amount of reaction set up by X-rays. (Still under treatment.)

Case 8.—C. D—, æt. 14 years, male. Supposed to have been infected at Surrey School. Duration three years.

Both lids and fornices covered by granules; fornices obliterated. Diffuse haze through both corneæ. Not much vascularisation.

X-ray treatment July 19th, 1902, to February 1st, 1903. Twenty-two exposures. Although cornea was much improved, the lids did not improve to any great extent. Showed practically no reaction to X-rays.

Case 9.—C. C—, æt. 44 years, female. Old trachoma in both eyes of thirty years' duration. Sight much worse during last eight years.

Typical scarring of both lids; entropion; obliteration of fornices. Leucomatous corneæ. Right eye: vision before treatment, shadows only. Dense leucomatous cornea with superficial vascularity. Twenty exposures of four minutes, extended over four months. Cornea cleared considerably. Vision, fingers at three feet.

(*March 13th*, 1903.)

The President (Mr. William Lang) said he had not applied the X-ray treatment very extensively, although he had used it on one case. Unfortunately the treatment had to be discontinued before a cure resulted, but the condition improved very rapidly while the treatment was proceeding; even in the first day or two the pannus cleared up very rapidly. One eye was much worse than the other, but the

Digitized by Google

bad eye which was treated with X-rays soon became as good as the other which was being treated with perchloride of mercury.

Mr. L. V. CARGILL said he had followed Mr. Mayou's treatment in his (Mr. Cargill's) patients, and could say that he had not overstated the case. One favourable point was the rapidity with which apparent cure was obtained, three to six months' treatment being as beneficial as ordinary treatment in from eighteen months to two years. Secondly, the apparent cure was obtained with less scarring than with ordinary treatment, even by escharotics without operative measures. Thirdly, the painlessness of the treatment was an important fact. The rapidity with which the pannus cleared up was remarkable, and the method was well worthy of trial in cases of dense corneal opacity which resisted other measures.

Mr. SYDNEY STEPHENSON'S experience of the treatment extended to thirty-five cases, five of which had been alluded to by Mr. Mayou, and were published in the columns of the medical press a few weeks ago. He thought the method of treatment an admirable one on the whole, and he could endorse what Mr. Mayou had said with regard to painlessness and practical freedom from complication. He had never seen complications of any moment, except thinning of the eyelashes and loss of hair in the eyebrows, and once dermatitis. Cases had recently been treated without shielding the face in any way, and the nurse's fingers had not been rubbed with bismuth ointment. In his opinion, the best treatment was perhaps by the high-frequency current. He had satisfied himself that the results had been better since he had used this method. He everted the eyelids and applied the high-frequency current directly to the palpebral conjunctiva by a glass and sealing-wax electrode. He had seen trachoma cured in five such sittings, lasting ten minutes each time, and extending over a fortnight. Among the disadvantages mentioned by Mr. Mayou was the difficulty of knowing when to stop treatment. But he (Mr. Stephenson) did not regard

Digitized by Google

that as a special disadvantage attaching to that particular treatment. It applied to every treatment of trachoma, as there was no uniform standard to which all cases of trachoma could be brought by treatment. The only thing to do was to stop the treatment and wait before deciding whether the case was cured or not.

---

6. *Lymphangiectasis of conjunctiva.*

By A. Ferguson MacCallan.

Linden W—, æt. 16 years, under the care of Mr. Waren Tay, at Moorfields, was born in South Africa, and has lived in that country all his life. He states that his left eye exhibited its present features at birth, although less markedly. He has never had erysipelas. When the patient was six years of age, spontaneous hæmorrhage, mingled with some watery discharge, occurred from the eye; this phenomenon was constantly present, and was exhibited during a period of twenty-one months; it was arrested by the use of a lotion and of medicine ordered by a medical man. Five years ago, after treatment by electrolysis, an abscess formed, which was lanced by a surgeon; the scar of the incision persists.

Present condition.—There is marked fulness of both upper and lower lids on the left side near the inner canthus. This is due to the intervention between the tumour and the globe of an abnormal amount of tissue, and is not the result of proptosis of the eyeball. There is ptosis due to thickening of the upper lid; the movements of the globe are normal. There is much thickening or deposition of new tissue between the integument and the tarsus in both upper and

Digitized by Google

lower lids. At the posterior margin of each lid is seen a single row of tiny grape-like vesicles. The lower fornix is occupied in its whole extent by a subconjunctival tumour. Its surface is studded with small vesicles, some of which contain blood and some a clear fluid. The tumour is best seen by everting the lower lid. The caruncle and the ocular conjunctiva in its neighbourhood are thickened. Beneath the upper lid, which cannot be everted, two pedunculated tumours are situated, similar to but smaller than the sessile tumour in the lower fornix.

The fundi appear to be normal. The vision with suitable correcting glasses is perfect.

A small portion of the growth was excised for pathological examination, and a report is appended. The operation was followed by much subconjunctival and subcutaneous hæmorrhage, relieved by the application of ice. The hæmorrhage has not been entirely absorbed.

Microscopical examination (by Mr. J. H. Parsons).—The epithelium varies greatly as to the number of layers in different parts, being reduced to two or three cells in some places, and increased to ten or fifteen in others. It is full of mucous cells, having the usual characteristics. It is very little infiltrated with leucocytes. The striking feature in the subepithelial tissue is the large number of widely-dilated spaces. These are very definitely lined with a single layer of endothelium. Many of them are empty; others contain a hyaline coagulum which stains faintly with eosin, and yellow by van Gieson's method. Only a few contain red corpuscles, and these are so scanty in number as to be probably due to manipulations during preparation. The trabeculæ of connective tissue between the spaces are richly supplied by blood-vessels. They are also infiltrated irregularly with leucocytes, and aggregations of these are found in places beneath the epithelium. There can be no doubt that the spaces are widely dilated lymph-spaces, the condition being one of lymphangiectasis. (*November 14th*, 1902.)

Digitized by Google

III. DISEASES OF THE CORNEA.

1. *Cases illustrating an unusual form of corneal opacity, due to the long-continued application of copper sulphate to the palpebral conjunctiva.*

By Sydney Stephenson, M.B.

(With Plate I, fig. 2.)

For some years I have been familiar with a rather curious form of corneal opacity, met with exclusively in children who were, or had been, under treatment for trachoma. The opacity generally appeared as a reddish-brown or rusty-coloured arc lying in the cornea near the upper or the lower part of the limbus, occupying much the same position as a commencing *arcus senilis*.

It is only recently that I have succeeded in tracing the corneal opacity to what appears to be its cause, namely, the long-continued application of copper sulphate to the palpebral conjunctiva. The conclusion has been arrived at on the following grounds:—(1) the change was found only in eyes the conjunctiva of which had been treated by "bluestone;" (2) the longer the treatment the more pronounced the opacity; and (3) scrapings from the affected cornea gave the characteristic chemical reaction of copper, *viz.*, (*a*) a faint brown tinge on the addition of potassium ferrocyanide, and (*b*) a faint blue colour on the addition of caustic potash and ammonia.

Characters of the opacity.—The opacity usually takes the form of a faint, diffuse, smoky dulness, covering, at an advanced stage, the whole of the cornea, excepting a

Digitized by Google

narrow peripheral ring 0·5 mm. to 1 mm. wide. The upper and the lower part of this disc are more accentuated than the other portions, so that two rather conspicuous crescents, often of a greenish or rusty colour, are formed. The upper of these arcs is usually the better marked. On a casual examination of the cornea, these may be the only changes noticed. They give a very characteristic picture, resembling no other corneal condition with which I am acquainted. The opacities, which appear to be of a superficial nature, are best seen by focal illumination. Considering their position, they interfere little with sight.

The following facts regarding this "copper staining" (as I suppose we may term it) may not be altogether devoid of some little practical interest. On a particular date in November, 1902, the eyes of 147 inmates of the Ophthalmic School at Hanwell, W., were examined with a view of ascertaining in what proportion the changes existed. The pupils were dilated, and the corneæ examined by focal illumination. Male and female children, whose ages ranged from four to sixteen years, were included in the list. Finally, it should be added that copper sulphate had been applied to the palpebral conjunctiva of all the children, the exact number of applications varying from as few as 3 to as many as 2195.

Amongst these cases, the cornea was normal in this particular in 57 (38 per cent.), and affected in 90 (61 per cent.). As regards the latter, the corneal changes were "slight" in 55, "moderate" in 16, and "marked" in 19 patients. In the first group, copper had, on the average, been applied 844 times; in the second group, 877 times; and in the third group, 1178 times. In the unaffected children, on the other hand, the average number of times copper had been applied was only 379. To put the matter in another way: the average for unaffected cases was 379, while for affected cases it stood at 912, the proportion between the two figures being as 6 is to 13.

(*December 11th*, 1902.)

Digitized by Google

The CHAIRMAN (Mr. W. Lang) said the cases were most interesting, and he thought the cornea was capable of taking up a good many stains. Many years ago, after using a solution of quinine for an ulcer, he noticed a fluorescent appearance throughout the cornea, which he attributed at the time to the absorption of the quinine crystals carried through the circulation. He supposed such cases as Mr. Stephenson's showed that the cornea had a special proclivity for picking up the sulphate of copper crystals. Perhaps it would be worth while magnifying the cornea with Zeiss's corneal microscope to see if any crystals could be discovered. He did not know whether Mr. Stephenson had done that.

Mr. SYDNEY STEPHENSON replied that he had not examined the cornea with a Zeiss microscope, but he suggested that the material was cuprous oxide, or, possibly, an albuminate of copper.

---

2. *Zonular opacity of corneæ.*

By GUSTAVUS HARTRIDGE.

MRS. B—, æt. 34 years, attended at the Westminster Hospital on April 4th, 1902, complaining of defective vision.

She gave the following history:—she had always had good health; she had been married sixteen years and had nine children, seven of whom are living and healthy, one died at the age of two and a half, and one was born dead; no miscarriages.

After the birth of the eighth child both eyes were inflamed for some weeks, but she had no special advice about them.

Digitized by Google

The failure of vision commenced gradually ten years ago.

Present condition.—R. V., counts fingers at 1 mètre. T. n. L. V. $\frac{6}{60}$ No. 1 Sn. T. n. Posterior synechiæ in both eyes. Well-marked zonular opacity across each cornea; no marked anæsthesia of cornea.

(*Card specimen. May 7th*, 1903.)

Mr. Adams Frost said he understood the defect of vision was considerable, and asked whether it was accounted for by the condition of the cornea. He noticed numerous posterior synechiæ, but there was no history of any acute inflammatory attack. He therefore thought it probable that choroidal changes existed. In his experience, it was very unusual to find that condition of cornea except in an eye which was diseased.

The President (Mr. William Lang) said it was a very well-marked example of the defect. He agreed with Mr. Frost's observation that it was probably secondary to iritis, probably associated with choroiditis and cyclitis. It was scarcely likely to have been a primary affection of the cornea in such a young patient. One saw somewhat similar conditions in older patients without apparently any choroidal or uveal change. He believed scraping would be attended by a good result; he had scraped one or two such cases with great satisfaction. The cornea in the present case was so clear above the band that a better result might be obtained by iridectomy.

Mr. Hartridge, in reply, said he had mentioned the synechiæ in the notes, and he had no doubt there was choroiditis as well. The corneal opacity would not account for the great defect of vision.

Digitized by Google

3. *A case of zonular or ribbon-shaped opacity of the cornea.*

By CHARLES BLAIR.

WILLIAM CAVE, æt. 72 years, presents on each cornea a transverse band of opacity, composed of whitish, superficially situated dots. It has a chalky appearance, and is apparently immediately beneath the epithelium. The epithelium is intact over it, and the surface of the cornea does not appear roughened over the deposit. In the right eye it extends from the outer border of the cornea to the centre of the pupil; and in the left from the outer border of the cornea to near the inner edge of the pupil. A similar opacity is commencing on the inner side of each cornea.

Very little change has taken place since it came under observation two years ago. On the left side the opacity has extended further over the pupil, but that on the right does not seem to have appreciably altered.

The eyes are otherwise quite sound.

R. V. $\frac{6}{36}$, H.m. 2·5 D. = $\frac{6}{6}$ partly. J. 1 $\bar{c}$ + 6 D. sph.

L. V. $\frac{6}{60}$, H.m. 2·5 D. = $\frac{6}{9}$ partly. J. 1 with difficulty $\bar{c}$ + 6 D. sph.

The patient is a house decorator, and has always been accustomed to blow away the dust before painting.

(*Card specimen. December 11th*, 1902.)

---

4. *A case of mycosis of the cornea.*

By LESLIE BUCHANAN.

(With Fig. 1.)

G. R—, æt. 54 years, was struck on the right eye with a piece of straw fourteen days before admission to the Glasgow Eye Infirmary. He had suffered considerable pain, and the eye was much congested. There was a small

Digitized by Google

but deep and purulent ulcer at the lower and outer part of the cornea, surrounded by a zone of inflammatory infiltration. The ulcer extended in spite of treatment, and there was hypopyon of small amount at various periods. The ulcer gradually became covered by a greyish, sloughy mass with sharply-defined edges and a dull surface. This mass increased in size by spreading upwards, and

FIG. 1.

ultimately covered the central area of the cornea. In its later stages it appeared to be raised above the surface of the cornea. Part of the slough-like mass separated at the primary ulcer, and the cornea became clear; but the remaining part, which was ultimately about 4·5 mm. in diameter, continued to extend, and the hypopyon increased greatly until the eye was excised fifty-six days after the injury. There was considerable pain and much congestion of the eye throughout the whole course of the affection.

Digitized by Google

Histological examination of the cornea showed that the slough-like mass was, indeed, necrotic corneal tissue penetrated by a densely felted mycelium (*see* Fig. 1). The general characters and one small portion of a fructification indicate that the growth is an aspergillus, but what variety it is cannot be stated definitely.

Remarks.—There are about sixteen cases of mycosis of the eyeball on record. One only of these is from the United Kingdom, *i. e.*, that by Dr. Reid, of Glasgow.

The growth has been known to penetrate into the interior of the eye in three cases (Reid's, Schirmer's, and Nobbe's).

In the diagnosis the principal points are injury with something connected with agriculture, sloughy ulcer with hypopyon running a slow course, and the presence of a sharply-defined, greyish-coloured slough with a dry or dull surface. Culture experiments are necessary to establish the diagnosis and to identify the organism.

(*July 3rd*, 1903.)

The PRESIDENT (Mr. William Lang) did not remember to have recognised a case of mycosis of the cornea. He inquired why it was necessary to enucleate the eye.

Dr. BUCHANAN, in reply, said the case was not under his charge, and therefore he could give no details on this point.

---

5. *A case of primary papilloma of the cornea.*

By C. W. DEAN.

(With Plate I, fig. 3.)

AMONG the curiosities of surgery are certainly tumours primarily arising from the cornea, very little being said of

Digitized by Google

them in the standard text-books. I therefore make no apology for adding to the list of those already reported.

Swanzy says that "primary tumours of the cornea are extremely rare. Yet a very few cases of papilloma, epithelioma, and fibroma are recorded as taking their origin in the cornea." In his book Berry discusses dermoid cysts and fibromata of the cornea, but does not mention papillomata. The well-known manual of Fuchs includes them as among the greatest of rarities, but beyond stating that isolated cases of primary papilloma, fibroma, myxoma, and sarcoma have been recorded, says little about them. Prof. De Schweinitz says, "Tumours of the cornea are very rare, and include the growths which develop from the epithelium—epitheliomata—or invade it by extension from the neighbouring tissues—sarcomata. A few instances of fibroma, papilloma, and primary sarcoma have been reported." In Haab's *Atlas of External Diseases of the Eye*, papilloma is not mentioned, nor can I find the name in Nettleship's book. The *Handbook of Ophthalmic Surgery*, of Carter and Adams Frost, is equally silent; but the latter ophthalmologist reported in the year 1893, in the *Transactions of the Ophthalmological Society*, a case of primary papilloma of the cornea occurring in an old man, the diagnosis being verified by microscopic examination.

The case I am about to record, whether the tumour be held to have arisen primarily from the cornea or not, is of great rarity.

J. R—, a fisherman æt. 53 years, with good general health, consulted me in August, 1901, on account of a tumour which was growing on the inner side of the left cornea. He said that it had existed for about four years; that it commenced as a minute speck on the "clear" part of the eye over the brown, not on the "white" of the eye; and that it had gradually increased in size, principally towards the pupil.

I drew a rough sketch of an eye, and asked him to make a mark on the exact spot where he thought the

Digitized by Google

growth originated. The fac-simile of this drawing shows that the mark lay wholly within the cornea.

When first noticed, the tumour was smaller than the mark on the sketch, but it steadily increased, and the patient used to wonder whether it would grow inwards on to the conjunctiva, or outwards towards the pupil, in which latter eventuality he argued that his sight would be ultimately lost. It did grow outwards, and therefore he sought advice.

On August 30th Mr. T. H. Bickerton saw the patient with me, and the eye was minutely examined. The growth was irregular in shape, distinctly warty in character, whitish in colour, and in size equal to a flattened pea. It was situated on the lower and inner quadrant of the cornea, to which structure it was inseparably connected; it was not possible to insert a probe beneath it at any point. Its inner border slightly overlapped the edge of the cornea, seeming to push the conjunctiva before it for a little distance, and to be connected with it; but the main part of the growth was inseparably incorporated with the cornea, and extended nearly to the pupillary margin. The cornea immediately surrounding the growth was infiltrated and hazy. Under high magnification, five or six fine synechiæ could be seen at the inner pupillary margin, with pigmentation of the capsule of the lens. Left pupil $2\frac{1}{2}$ mm., and the outer half of pupil reacted to light. Right pupil 4 mm. R. V.$=\frac{6}{6}$ and J. 1. L. V.$=\frac{6}{0}$ and J. 14. The vitreous was clear and the fundus normal.

The tumour was removed by the aid of cocaine. It was shaved off the cornea with a Critchett's knife until the clear tissue could be seen beneath. The eye was dressed with atropine and boric ointment, and made an uninterrupted recovery. On September 20th it was almost well, the cornea being quite transparent and the media clear.

On November 8th vision had improved from 0 to $\frac{6}{9}$. With +·5 D. sph. he could read $\frac{6}{6}$ imperfectly; J. $2\frac{1}{2}$ could be read easily, whereas before operation J. 14 was the

Digitized by Google

utmost he could make out. The media were clear with the exception of the pigmented spots mentioned previously, and, as before, the fundus was normal.

The tumour was submitted to expert microscopical examination, and the report states that it is "papillomatous, with much heaping up of horny epidermis." The site of the papilloma can now hardly be detected except by using a strong convex lens, when two opaque spots show where Bowman's membrane had been penetrated by the cell-infiltration, but the small cells in the deeper layers that were noticed before removal have quite disappeared.

(*July 3rd*, 1903.)

---

6. *Alveolar sarcoma of the cornea.*

By E. Donaldson.

(Supplementary report.)

In Volume XV, p. 90, of the *Transactions of the Ophthalmological Society*, I recorded a case of alveolar sarcoma of the cornea. I now add some further notes.

The growth was removed by scissors on March 2nd, 1895. On the 6th July, 1895, at the inner margin of right cornea in the horizontal meridian, there was a return of the growth, which had the same gelatinous-looking appearance as before, and measured 2 mm. in diameter. This little speck I burned thoroughly with the actual cautery. On December 10th, 1895, there was no return, and the vision of the right eye was $\frac{5}{5}$. A slight opacity existed at the seat of operation, and there were no enlarged blood-vessels on the eyeball. On May 17th, 1897, I heard by letter, in reply to questions, that the patient was in good health, and that the growth on the eye had

Digitized by Google

not returned. Early in January, 1903, I wrote for further information, but failed to get a reply.

(*May 8th*, 1903.)

---

7. *Endothelioma of cornea.*

By W. W. Sinclair and J. Herbert Parsons.

Twelve years ago Miss C— was under the care of Sir Anderson Critchett, to whom we are indebted for the early history of the case. At that time there was, writes Sir Anderson, "a small growth at the outer side of the corneo-scleral margin of the right eye. It was not larger than a hemp-seed, but it looked to be of such a suspicious character that, after consultation with Mr. Jonathan Hutchinson, I eradicated it by a thorough application of the galvano-cautery. Five years later there was a recurrence of a similar growth just above the site of the former one, and this was treated in a similar way, as were two more which appeared at intervals of about three years."

Notes by W. W. S. (May 27th, 1902).—Right eye shows no congestion. There is a soft, grey, gelatinous-looking, circumscribed mass at the upper part of the cornea, slightly raised above the corneal level. Fine vessels pass into the grey mass, which shows numerous white dots of denser opacity. Fluoresceïn stains only the lower edge of the patch. Curiously, a distinct stain appears at the lower edge of the cornea, where it looks normal. There is a faint old nebula over the unaffected part of the cornea.

During the next two months the patch grew very slightly indeed, but at each visit small areas of fluoresceïn staining showed on the apparently normal cornea, each

Digitized by Google

time in a new position. There was no visible ulceration, nor could I detect loss of epithelium.

On January 9th, 1903, I found the patch considerably larger, more vascular, and a good deal more raised above the corneal level. The growth measured 6 mm. vertically, and 6·5 mm. horizontally. There was no tenderness, nor any general congestion of the globe.

On January 16th I carefully cut the growth away entire with a keratome. It cut easily and softly, leaving astonishingly clear cornea behind, giving one the impression that it grew from the superficial layers of the epithelium. The operation, done under cocaine, was absolutely painless, and was followed by no reaction whatever.

I saw the patient on February 26th. V. = $\frac{5}{24}$. At the lower-outer part of the cornea, beyond the limit of the growth removed, is a small greyish area, very slightly raised above the general level. Here, and also on the site of the growth, the magnifier shows a few minute grey dots, which are superficial and resemble the dots observed on the growth.

Clinically, the growth did not appear to penetrate deeper than the epithelial layer, and certainly it did not penetrate beyond the surface layer of the true corneal substance.

Pathological report by J. H. P.—Transverse sections of the growth are plano-convex in shape. The deep surface everywhere passes through growth, and no normal corneal lamellæ are seen. The convex surface is covered by epithelium, which is flattened, varies greatly in thickness, and is absent near the periphery on one side. The cells resemble the rapidly-growing superficial epithelium of inflammatory conditions; there are no cubical basal cells, but there is no suggestion of epithelial infiltration of the deeper tissues.

The growth consists of masses of epithelioid cells arranged in an alveolar manner, enclosed in capsules of spindle-celled fibrous tissue. This tissue stains red with van Gieson, and fibrillæ pass between the outer cells of the

Digitized by Google

masses, but the larger central parts are devoid of any definite intercellular stroma.

The epithelioid cells are probably endothelial in origin. They vary greatly in size and shape; many show karyokinetic phases, and others atypical nuclear changes. The aggregations also vary in size. They are mostly oval, and smaller ones in places invade the epithelium, recalling the conditions found in congenital nævoid growths.

There is some peripheral lymphocytic infiltration, which does not much invade the growth masses, but is most marked where there is ulceration of the superficial epithelium.

Remarks by J. H. P.—There can be little doubt that this growth is an endothelioma, and that it originated in the limbus, and is not a true autochthonous corneal growth. There are faint indications of *débris* of red corpuscles in a few of the alveoli, and this points to blood-vascular endothelium as the origin of the cells.

I have had the opportunity of examining sections of Donaldson's sarcoma of the cornea (*Trans. Ophth. Soc.*, vol. xv, p. 90). The arrangement of the cells is very similar, and the same diagnosis and origin (*i. e.*, from the limbus) are probable, but the endothelial character of the cells is less marked.

An investigation of the literature * of primary sarcoma throws great doubt upon the origin of such tumours from the corneal tissues. It is obvious that the blood-vessels are in all cases derived from the limbus. Many of the tumours are of very vascular, or endothelial, or perithelial type. It is probable that they all originate in the limbus, and invade the cornea secondarily; but often burrow under the intact epithelium of the periphery of the cornea, and, on coming to the surface, resemble autochthonous corneal growths. (*Card specimen. March 13th*, 1903.)

N.B.—This communication was illustrated by microphotographs of the growth.—EDITOR.

* *See* Lagrange, *Tumeurs de l'œil*, vol. i, p. 208.

Digitized by Google

Sir ANDERSON CRITCHETT said he first saw the case described twelve years ago, and then there was an exceedingly small growth not larger than a hemp-seed. Its characteristics were peculiar, so much so that he suggested a consultation with Mr. Jonathan Hutchinson, and the conclusion arrived at was that it might possibly be endothelioma; at any rate, they were sure the sooner it was eradicated the better. He thoroughly removed it, going deeply into the tissue. He kept the lady under careful observation, but there was no return for at least four years. The growth then returned at a spot a little above the former site. He again treated it, this time by the galvano-cautery, altogether on four different occasions. At length, as she was going to live at Ipswich, he handed her on to a Member of the Society who lived there. The patient's age when first seen was 42 years, and was now 54 years.

Digitized by Google

Digitized by Google

PLATE III.

Illustrates Drs. Poynton and Paine's contribution to the Study of Iritis (p. 39).

FIG. 1.—Experimental rheumatic iritis (D) produced by intra-venous inoculation of a rabbit. Under low magnification. The black mass represents the diplococci on the anterior surface of the iris lying in the exudation.

FIG. 2.—The same, more highly magnified, to show the diplococci in the exudation.

Digitized by Google

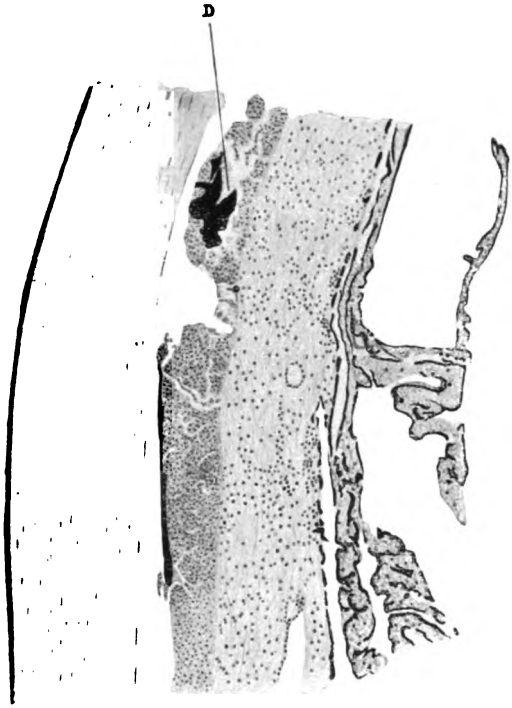

FIG. 1.

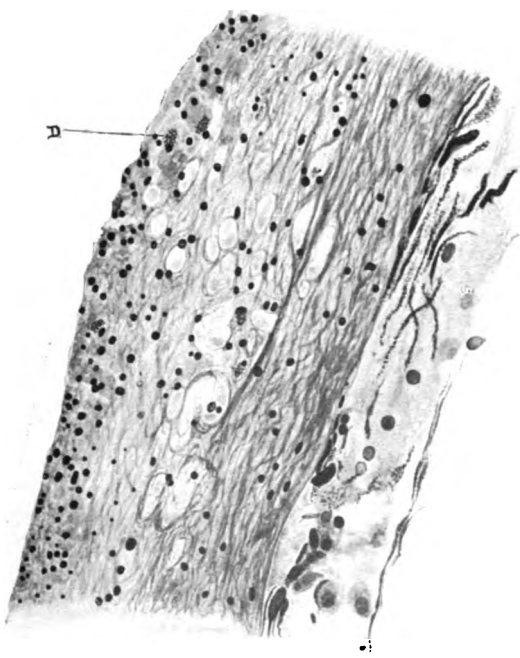

FIG. 2.

Digitized by Google

Adlard & Son, Imp.

Digitized by Google

IV. DISEASES OF THE IRIS.

A contribution to the study of Rheumatic Iritis.

By F. J. Poynton, M.D., and Alexander Paine, M.D.

(With Plate III, figs. 1 and 2.)

Introductory.

Before we commence this paper we must define our position to-night. We do not pretend to that skilled knowledge of irido-cyclitis which would be asked of an expert, but have—when investigating the subject of rheumatic fever—observed certain facts which may be of interest to ophthalmic surgeons, and which in this spirit we bring before you on this occasion.

For us rheumatic iritis is rather an incident in a general infection than a disease, and for our purpose it matters little whether it is rare or frequent in its occurrence. The question, as it presents itself, is sufficiently simple: Can a micro-organism which is a cause of rheumatic fever produce iritis as it does endocarditis, pericarditis, arthritis, pleuritis, and subcutaneous nodules?

For the ophthalmic surgeon the subject is much more complex, involving points in treatment and refinements in diagnosis and management to which we need not now allude. For him it is a disease of first importance; for us it is, as we have said, an incident in a general infection.

The clinical position of Acute Rheumatic Iritis.

Among ophthalmic surgeons we believe there is some divergence of opinion as to the frequency and occurrence of acute rheumatic iritis, though there appears to be little doubt that it is a rare, but not unknown event—a

Digitized by Google

statement which we would venture to support with such experience as we have ourselves had. Further support of its rarity was supplied in January, 1903, by Macrae, in the *Journal of the American Medical Association*, who noted its occurrence only once in 270 cases of rheumatic fever.

A good example of the condition was published in the *British Medical Journal* for March 7th, 1903, by Mr. F. C. Forster, of Lowestoft, and in addition Mr. Forster kindly sent us in a letter some further details, which we have his leave to quote. It may perhaps be remembered that it was the case of a girl, æt. 12½ years, who developed, after a definite chill, tonsillitis and arthritis. Then followed chorea, and later iritis of the right eye and endocarditis. In his letter Mr. Forster writes as follows:—"The iritis came on very suddenly when she was recovering from chorea. The right eye alone was affected; the pupil was altered in shape, and a naturally brown eye assumed a yellow tinge. . . . There was the usual marked congestion (especially circumcorneal), with great pain and photophobia; the pain was both topical and supra-orbital. . . . The iritis relapsed twice, and I feared that some posterior synechiæ would eventually lead to diminution of vision. . . . Recovery was eventually good. Rheumatic iritis," he adds, "is, of course, not common in children, but I have met with few more typical than the one under discussion. Syphilis, gonorrhœa, and trauma may certainly be excluded as causes in this particular case."

This seems to us a clear example of acute rheumatic iritis of unusual severity. Such examples as we have seen have been very transient.

Among those who are opposed to the acceptance of acute rheumatic iritis, much importance is attached to the gonorrhœal infection. Even if this may have occurred some years before, they attribute an iritis of a rheumatic type to that cause. In passing we would venture to point out the well-known fact that rheumatic symptoms are most liable to occur in those subjects of gonorrhœa who have suffered

Digitized by Google

previously from rheumatic fever; also that the diplococcus of the gonorrhœal infection was one of the earliest known of this type of micro-organism, and its recognition established in text-books on hard and fast lines, which with more mature experience are perhaps a little too hard and fast; and, lastly, that the rheumatic infection equally as much as the gonorrhœal is liable to lurk in the system for long periods. Both diseases may theoretically be causes of iritis. Both linger in the system. We are thus in agreement with Mr. Lawford's opinion on the imperfection of this *proof* of the gonorrhœal origin of many cases of iritis as expressed at the British Medical Association meeting in August, 1901.

The Object of the Communication.

The object of our communication is to show that acute iritis may result in rabbits from experimental inoculations with a diplococcus or micrococcus which is a cause of rheumatic fever.

Other observers—for example, Birch-Hirschfeld—have produced septic panophthalmitis by inoculations from cases of septic endocarditis, but in our two cases the micro-organism was isolated, first, from a case of ordinary rheumatic fever in a child, and, secondly, from a case of malignant endocarditis of rheumatic origin, and in neither animal did there result septic panophthalmitis.

The cases we will detail immediately, but we first emphasise the fact that these inoculations were intravenous—into the auricular veins of rabbits,—and not local—into the eye. Had they resulted from local inoculations we should not personally have attached any importance to them.

The Investigation.

Case 1.—In 1899 a boy æt. 9 years, who was suffering from morbus cordis, developed, while under observation, active rheumatism—that is to say, arthritis,

Digitized by Google

pericarditis, and subcutaneous nodules. Death resulted from pericarditis. From the pericardial fluid, which was clear but contained also flakes of exudation, minute diplococci were isolated. They were also demonstrated in films of the pericardial fluid, in which they grew in chains. The necropsy showed the usual results of rheumatic fever in childhood—there was no suppuration.

The first rabbit inoculated intra-venously with the pericardial fluid died on the ninth day of arthritis, pericarditis, and broncho-pneumonia. The second died on the twentieth day with arthritis and pericarditis. The third recovered. The fourth was killed on the tenth day, and suffered from arthritis and mitral endocarditis. The fifth was killed on the ninth day, and suffered from pericarditis, pleurisy, endocarditis, pneumonia, and arthritis. The sixth developed choreiform movements, and was killed. The seventh died of malignant endocarditis. The eighth died, on the tenth day, of pericarditis and endocarditis with an infarct in the left lung. It was this one that developed iritis of the left eye. The ninth developed chronic rheumatic arthritis; and then we lost the strain, failing to recover the organisms from the exudation. Thus it will be seen that of a series of nine animals only one developed iritis. There was nothing unusual about the inoculation, but the animal was a feeble one. On the fifth day there was some lacrymation ; this continued for two days, and then followed injection of the conjunctival vessels, discoloration of the iris, and considerable exudation into the anterior chamber. It should be clearly stated that the appearance was not like that of an hypopyon, and after death the fluid was not opaque and yellow, but a little cloudy, although, as will be seen, it contained vast numbers of the micro-organism. The condition in no way resembled one of septic panophthalmitis. It was an easy matter to grow the micro-organism again from the fluid in the anterior chamber, and it showed the usual characters. The next rabbit inoculated developed chronic arthritis.

Digitized by Google

Under the three microscopes there are shown—

(1) A film of the exudation.

(2) A section of the iris under a low power showing the exudation, fibrino-cellular in character, on the anterior surface of the iris.

(3) The same under a high power showing the micrococci in the exudation.

The anterior surface of the iris, after removal, was seen to be dotted over with small, raised, white areas.

The minute description of the changes is given with the drawings placed beside the microscopes.

Since that investigation we have repeatedly studied the illness produced in rabbits by the injection of this micrococcus, and although we have from time to time noticed lacrymation and slight conjunctivitis, we have only once met with iritis again, and that with a culture obtained from the malignant type of rheumatic endocarditis.

CASE 2.—A boy æt. 13 years, in December, 1900, was admitted under Dr. Lees to St. Mary's Hospital for heart disease. He had suffered two years before from an attack of rheumatic fever. The present illness had commenced insidiously. Mitral and aortic disease were discovered; the boy went from bad to worse, and died rather unexpectedly in January, 1901.

General pericardial adhesion, malignant mitral and aortic endocarditis, and a splenic infarction were found. There was no suppuration. Two hours after death we isolated from the cardiac valves a minute diplococcus.

Intra-venous inoculations were again made.

Rabbit No. 1 died of malignant mitral endocarditis with iritis.

„ „ 2 „ pericarditis and endocarditis.

„ „ 3 „ pericarditis and endocarditis.

„ „ 4 „ pericarditis.

„ „ 5 recovered.

It is remarkable and interesting that in a considerable number of investigations we have only met with iritis

Digitized by Google

twice; and that Fritz Meyer, who has made extensive experiments with animals with a similar organism, does not mention its occurrence. Nor, to our knowledge, have Dr. Ainley Walker and Dr. Beaton met with it. It must, I think, be a rare occurrence, as in man.

There is still a great gap in our knowledge. For no one, so far as we are aware, has isolated this organism from a case of rheumatic iritis in man and produced rheumatic fever in animals. We have waited in vain for such an opportunity for three years, and bring this forward in the hope that someone may complete the chain of evidence.

(*April*, 1903.)

The PRESIDENT (Mr. William Lang) expressed the thanks of the Society to the authors for their valuable paper. He did not regard rheumatic iritis as a common affection, but asked if the plastic exudation which was frequently seen in gonorrhœal iritis was also characteristic of the presence of micro-organisms. He had never attempted to extract the lymph found in the anterior chamber in the early stage of the affection, but would like to hear whether the authors would expect to find micro-organisms in the exudation a short time after gonorrhœa, as, if so, it would be an inducement to extract the lymph and to cultivate the organisms.

Mr. HARTRIDGE asked whether we might expect to find rheumatic diplococci in cases of undoubted gonorrhœal origin. Ophthalmic surgeons were very familiar with gonorrhœal iritis, but cases of rheumatic iritis were extremely rare; he had not seen acute rheumatism with iritis at all. Were gonorrhœal cases specially predisposed to rheumatism?

Mr. HOLMES SPICER asked whether the ordinary bacterial methods of detection were sufficient.

The PRESIDENT asked whether Dr. Paine had had an opportunity of making a cultivation from a so-called gonorrhœal iritis exudation. He could provide him with a case from which exudation could be obtained.

Digitized by Google

The AUTHORS, in reply, said that if gonorrhœal iritis were caught in the early stage the organisms would be likely to be found, but not in large numbers. In later stages the organisms would not be present, because the mere fact of adhesions forming would show that resolution had taken place, and that the organisms had been destroyed. Where there was a recurrent attack, they would regard it as a case in which the organisms had become latent and encysted. The point brought forward in the paper was whether all the cases of iritis which followed after gonorrhœa some time before were really gonorrhœal, and whether possibly some of them were not rheumatic. It was extremely difficult to be sure of gonorrhœal infection. There were certain tests for the organism, but experimental results with the organism had been negative, and it was very difficult to settle whether the organism was the gonococcus or not. The distinction would appear from the books to be simple, but often it was a very difficult matter. But when one considered the analogy of gonorrhœa to rheumatism, some of the cases assumed to be gonorrhœal might turn out to be rheumatic. Possibly, as suggested by Mr. Hartridge, both organisms might be found in the same case. In reply to Mr. Spicer, when the diplococcus was present they did not think there was difficulty in finding it, because it reacted to the stains in the ordinary way, and grew on the ordinary media. They did not think there was more difficulty in staining the diplococcus of rheumatism than that of gonorrhœa or other diseases; but it was difficult to preserve the virulence. The organism was frequently put into beef-tea, and in that substance its virulence diminished, and experiments afterwards yielded no results, and no one could say what organism it was. The authors would be pleased to avail themselves of getting some exudation from a case of assumed gonorrhœal iritis.

Digitized by Google

V. SYMPATHETIC DISEASE.

Sympathetic ophthalmitis with cystic changes in the iris.

By Walter H. Jessop.

W. P—, æt. 16 years. Nine years ago a pitchfork was driven into his right eye; he was not seen by a doctor for the accident, but has been blind in the right eye ever since. He never remembers that his left eye was inflamed till two months ago, when it began to run with water and to ache; at the same time his right eye became painful and bloodshot. He also noted he could not see so well with the left eye, and the vision has steadily got worse. He is a healthy-looking, well-nourished boy.

Right eye.—Lids slightly red and swollen; conjunctival and scleral vessels congested; eyeball shrunken and squared, T. — 3; tender; cornea small, opaque, and towards centre a yellowish, horizontal, degenerated patch. V. = no p. l.

Left eye.—Photophobia; eyeball very tender; lids normal; conjunctival vessels congested, slight circumcorneal zone; cornea, numerous posterior punctate spots; iris, thickened, spongy, and honeycombed appearance; cysts stretched and atrophied in places; pupillary margin depressed and irregular. Pupil, under atropine, dilates to a fair size, but is somewhat square in shape from posterior synechiæ.

At periphery of the iris are, to outer side, two rounded limited swellings, about 2·5 mm. by 2 mm., and raised about

Digitized by Google

1 mm. from surface of iris and covered with thinned iris tissue; they can be seen by shifting the light about as semi-transparent swellings; to nasal side are two smaller swellings of iris. Tension normal. V. $\frac{6}{36}$, + 1·5 $\frac{6}{12}$.

Right eye was excised and found to be an atrophied globe.

(*Card specimen. November 14th*, 1902.)

Digitized by Google

VI. DISEASES OF THE RETINA AND CHOROID.

1. *Central Serpiginous Choroiditis.*

By L. WERNER.

(With Plate IV, figs. 1 and 2.)

THE patient, a healthy lad æt. 15 years, was seen for the first time on May 13th, 1885. A fortnight before he noticed that vision of R. was dim and objects looked smaller with it. He attributed this to playing hand-ball in strong sunlight. During the game he had temporary scotomata frequently. V. = $\frac{6}{60}$. Has an ill-defined, relative, central scotoma. Holmgren's Test II doubtful, as he selected some of confusion colours. Emmetropia.

Oph.—At the M. L. is a circular patch presenting a "pepper-and-salt"-like appearance, composed of pale yellow spots mixed with pigment, the whole surrounded by a bluish-green zone of haziness, pointed above, due to retinitis, or, more probably, retinal œdema. The retinal vessels, even the smallest, were, however, quite distinct in this zone, and I could obtain no parallax or difference in refraction (Plate IV, fig. 1). L. normal, V. = $\frac{6}{6}$.

He has one sister who is healthy, and has always been well himself. Is an orphan. Thinks his father died of phthisis. No evidence of syphilis.

Treatment.—Mercurial inunctions for a fortnight, followed by Potass. Iodid. On June 9th, about three weeks later, the following changes had taken place:—the hazy zone had disappeared, but the choroidal changes were progressing in an irregular manner, extending in some directions more than in others; the atrophy was

Digitized by Google

Digitized by Google

PLATE IV.

The figures illustrate Mr. L. Werner's case of Central Serpiginous Choroiditis (p. 48).

Digitized by Google

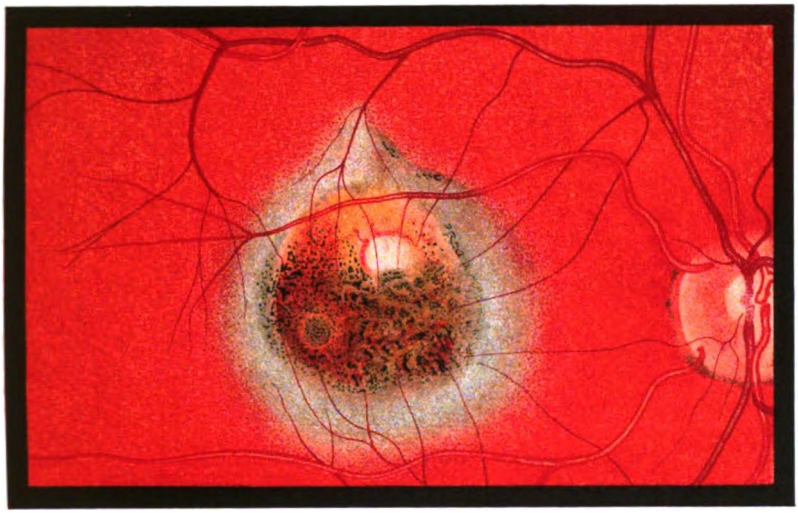

Fig. 1.

L. Werner, del.

Fig. 2.

Bale & Danielsson, Ltd.

Digitized by Google

PLATE IV.

The figures illustrate Dr. L. Werner's case of Central Serpiginous Choroiditis (p. 48).

Digitized by Google

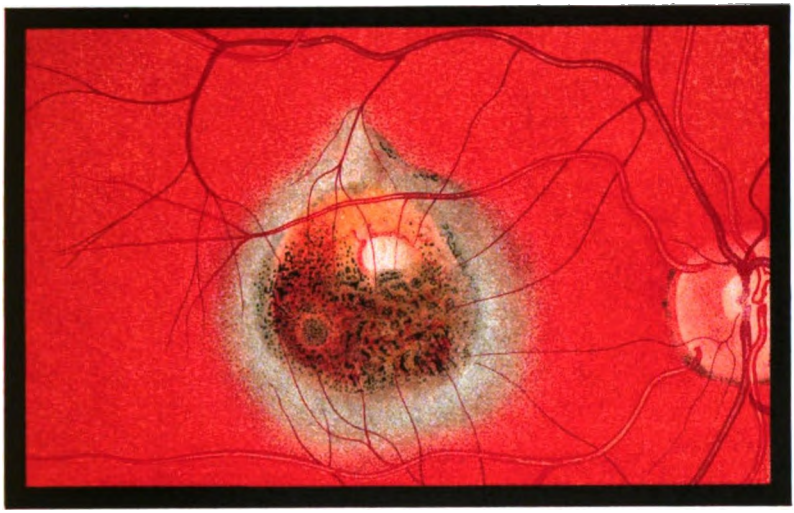

Fig. 1.

L. Werner, del.

Fig. 2.

Bale & Danielsson, Ltd.

Digitized by Google

Digitized by Google

superficial, and only here and there a few of the larger choroidal vessels became visible. There was only one small white patch above the M. L., which appeared early, and can be seen in both drawings. V. much improved, = $\frac{6}{9}$.

On June 24th, at the time when the second drawing was made, V. was still $\frac{6}{9}$. Failed in Test II Holmgren. Still micropsia; people seemed further away and thinner when seen with R. Saw bright dazzling spots before him, which he had noticed all along. Field normal, except a doubtful central scotoma.

Oph.—Appearances as in second drawing (Plate IV, fig. 2). Patch of choroiditis very large, and extending beyond sup. and inf. temporal arteries, reaching close to the sup. temp. vein; but changes still superficial in character.

Outline of diseased area very irregular, especially at inner and outer sides. Two small circular patches of healthy choroid are enclosed in the diseased portion, one below and the other to the temporal side. Close to the lower border is a white, indistinct exudation united to the main portion by a narrow neck. This appears to be the only part showing signs of activity at present. An atrophic triangular patch and two pigment spots have also developed separately near the terminal branches of the lower temporal vessels.

Patient was last seen on September 18th. V. = $\frac{6}{6}$, colour vision normal, still micropsia, dazzling spots only visible to him in strong sunlight, faint central scotoma not definable.

Oph.—Central patch of choroiditis unaltered, but a large butterfly-shaped area of atrophy, mostly superficial, has grown out from the indistinct hazy patch which existed below. It contains an island of healthy choroid equal in size to the optic disc. This new area of disease is united to the old one by the narrow neck mentioned before. Unfortunately the patient could not wait to have another drawing made.

Remarks.—I have called this "serpiginous choroiditis"

Digitized by Google

for want of a better name, as it indicates the manner in which the disease extended, creeping over the surface, and having a tendency to enclose portions of healthy choroid by the extension and coalescence of processes. I have failed to find any description of this form of choroiditis in the large text-books. In the *Transactions* of this Society, vol. vii, pl. iv, is an example of a somewhat similar condition described by Critchett and Juler, but it surrounded the disc, and it was not seen during the active stage. Vision also was much worse than in the above case. As stated, the patient attributed the origin of the affection to the action of sunlight, but, so far as I am aware, such extensive lesions have never been observed from the action of strong light.

(*Card specimen. June 11th*, 1903.)



2. *Two cases of tubercular choroiditis.*

By W. H. Jessop.

I have brought these two cases before the Society owing to their rarity; I have never before observed undoubted cases of tubercular choroiditis, except in acute miliary tuberculosis or tubercular meningitis.

Case 1.—Alma S—, æt. 9 years, was admitted on October 29th, 1901, into the ophthalmic wards of St. Bartholomew's Hospital.

On October 17th she was taken away from school owing to the eye watering much. 21st.—Burning sensation in right eye. 23rd.—Mother noted right lower lid unnaturally prominent. 24th.—Mother noticed swelling (size of pea) on outer side of ocular conjunctiva of the right eye, which has increased in size up to to-day.

During the summer months of the last three years, both

Digitized by Google

eyes have been subject to periodical attacks of "inflammation," lasting a few days and then recovering completely. The child has never complained of any defect of vision or other eye trouble. No history of blow on eye. Two years ago first showed signs of an obvious constitutional tuberculous infection. One year ago swelling in neck, which burst and has since been discharging; one year ago swelling in episternal notch, which was lanced; six months ago a discharging sinus in right upper arm; one month ago swelling on dorsum of right foot. The local foci have been treated elsewhere by "scraping," and the constitutional by fresh air, iron, and cod-liver oil.

Family history.—Father and mother well, and no chest symptoms. There were two children; the other, a boy, died at eighteen months of age, of tubercular meningitis.

Present condition.—Patient is a bright, thin, pale, tuberculous-looking child, whose growth is out of proportion to her age. Heart natural; chest slightly more prominent on left side. *Lungs.*—Slight flattening of right apex, which is also duller on percussion than left, and air entry is diminished.

Beneath ramus of right jaw is a scar, about two inches long, which still discharges watery material. In episternal notch, on right arm and right knee, are scars; on dorsum of right foot is a fluctuating swelling, covered by desquamating brawny skin.

R. — Lids normal in appearance and movements. *Conjunctiva.*—On lower-outer side, and covered by the ocular conjunctiva, is a yellowish-white, painless, smooth, non-fluctuating, round swelling, which is adherent to adjacent sclerotic. Its upper border nearly touches the limbus of the cornea, and the swelling becomes much more visible on the patient looking upwards, and the overlying conjunctiva has several vessels on it; the surrounding conjunctiva is congested. The measurements of the swelling are—height 10 mm., breadth at base 12 mm. by 17 mm. Cornea, anterior chamber, and pupil normal. T. — 1; V. $\frac{5}{60}$.

Ophthalmoscope.—The media are clear; the optic disc

Digitized by Google

cannot be seen, as it is concealed by a swelling covered by the retina. Two separate, non-vascular, spherical, steep detachments of the retina are to be seen extending about four discs' breadth downward from the optic disc. The temporal one covers the disc, and is the steeper; it is darkish-grey in colour, spherical in shape, and about 3 mm. in height. The nasal one is shallower, broader, greyish-white in colour, extending upwards nearly to the level of the yellow spot. The upper part of the retina is normal. There is no myopia, and no changes in the vitreous.

L.—Lids, conjunctiva, and cornea normal. V. $\frac{6}{9}$, $+1{\cdot}5\ \frac{6}{6}$. Tension normal; fundus normal.

Progress and treatment.—On November 5th, as the external swelling had gradually increased in size, under chloroform an attempt was made to dissect the mass as a whole from the sclerotic; but this was impossible, so it was removed down to the sclerotic, which was much thinned but not perforated. The scleral surface was scraped with a Volkmann spoon. The swelling had thick walls, and the central portion consisted of thick, caseating, yellowish pus. As a result, the walls gradually subsided to the level of the sclerotic, leaving slightly exuberant granulations, which were cauterised.

Microscopical and bacteriological examination (by Dr. Drysdale).—The walls of the abscess were very thick, but no giant-cells or bacilli were found. The caseating material from abscess was quite sterile. A guinea-pig was inoculated with caseous material on November 5th, and died on the 30th. A local abscess at seat of inoculation (thigh) had formed, and contained tubercle bacilli. The inguinal glands on same side were caseous, and contained tubercle bacilli; no visceral tubercles found.

Treatment and progress (continued).—November 4th.—T.—1. V. $\frac{1}{60}$ partly. Cannot count fingers at 6″.

7th.—Small sclerotic slough.

15th.—*Ophthalmoscope.*—R. Two separate retinal detachments. One light grey, shallow, extending halfway up the nasal part of fundus, = + 7. Another, at lower

Digitized by Google

part, is darker and steeper, = + 15, occupying the temporal half of retina. O. D. not seen. R. V. large, moving objects at 6″. Sees best on looking up and in. T. −1.

December 3rd.—Two posterior synechiæ to be seen at lower temporal aspect of pupillary margin of iris.

4th.—Now one synechia only.

6th.—R. V. $\frac{3}{60}$.

18th.—The site of external tubercular swelling still pinkish-red; no signs of sclerotic slough. T. −1.

Right eye.—Cornea normal, pupil dilated regularly under atropine; lens capsule, one or two small pigment spots. No vitreous opacities.

Ophthalmoscope.—The upper part of disc can be seen, but the lower is covered by the nasal steep detachment, which is still steel-grey in colour, and on it are four yellowish (lichen-colour) spots. The temporal detachment is white in colour, and not so steep; there are no other changes to be seen in the retina or any vitreous opacities.

January 3rd.—*Ophthalmoscope.*—Right eye. The detachments of retina are gradually sinking down from the disc; the white temporal one is about 2 O. D.s' breadth from optic disc, and overlapped by the nasal swelling. The nasal detachment is connected with the lower edge of disc and inferior nasal vessels by a triangular white band of thickened retina.

January 27th, 1902.—Was admitted again into the ward for complete and thorough examination. Her general health was much improved.

Right eye.—Conjunctiva in region of old wound is scarred, and in one place shows a cyst-like cicatrix, which appears to be filled by two or three separate small white bodies about the size of a pin's head (? tubercular). Cornea clear; anterior chamber normal; iris rather dull; pupil acts normally. *Ophthalmoscope.*—Right eye. Optic disc pink, edges distinct; on either side of and extending up to edges of disc is considerable white-yellow effusion into

Digitized by Google

retina with soft edges. This effusion extends on nasal side about 5 O. D.s' breadth, and on temporal side about 2 O.D.s' breadth; it is soft and flocculent-looking. The retinal vessels are distinct in all their course. The large retinal detachments have dropped further down to the periphery, and are distinctly separate from one another; the temporal is still white, and the nasal blue-grey. From O. D. and inferior nasal vessels there extends a broad white band to nasal swelling; from temporal side of disc is a white band with blood-vessels on it going to temporal swelling, and there is also a third band extending to the periphery between the detachments. These bands seem to be thickened or displaced processes of retina due to the gradual displacement of the two round detachments.

February 12th, 1902. — *Ophthalmoscope.* — A great change has taken place. The large patch of effusion at nasal side of O. D. has nearly disappeared, but there is much more effusion on temporal side; the steep round detachments have moved somewhat to temporal side, but are still very peripheral; there are still the yellowish lichen spots on steeper detachment.

September 24th, 1902.—Has been some time at Margate, and is much better in general health; weight, 5 st. 8 lbs. R. V. $\frac{6}{24}$.

November 25th.—Has had several small abscesses—two in neck, one at bend of leg, one in calf, and also in arm.

January 28th, 1903.—R. V. $\frac{6}{24}$. *Ophthalmoscope.*—Right eye. O. D. a little pink, the edges distinct, especially at temporal side; vessels normal. At temporal side of O. D. and outwards for 3 O. D.s' breadth are spots of soft, white, retinal effusion and some cholesterin spots. Above and to nasal side are also a few of the soft spots; from lower temporal side, and also from below, are two folds of retina extending to a white swelling, and then passing on to the swellings at the periphery.

April, 1903.—Patient has been very well lately, and looks much more healthy. No active foci of disease. R. V. $\frac{6}{18}$ partly. L. V. $\frac{6}{6}$. Fundus and media normal.

Digitized by Google

Field for white contracted, but equally and about 20°. Tension normal. Right optic disc edges a little indistinct above and below; the retinal arteries are normal, with rather broad light streak; the veins are normal. On outer side of O.D., and also above and below, are several soft, greyish-white spots extending 1½ O. D.s' breadth from O. D., and also some cholesterin spots. About 1 O. D. from O. D. below is a white swelling (+ 10 D.), and extending from this to periphery is a white retinal streak or fold. At periphery are remains of original two round detachments, and also in places some atrophied choroidal patches and slight pigmentation. Except for this slight pigmentation, there are no pigment changes in fundus.

Case 2.—Miss B—, æt. 23 years, seen with Dr. Sutherland on January 13th, 1900, came complaining that whilst sitting in front of a gas fire everything became blurred and misty below with right eye. Has never worn glasses nor had any trouble with eyes before. Four years ago had a suppurating mammary cyst in which tubercle bacilli were found. There is a marked family history of phthisis, as mother and two maternal uncles died of phthisis. Dr. Sutherland found no signs of tubercle in the lungs or elsewhere.

Present condition.—Right eye.—V. $\frac{6}{18}$. Does not see so distinctly below and to outer side of the centre of vision; red, especially, not so well seen here, but no absolute scotoma. Lids, conjunctivæ, cornea, anterior chamber, iris, pupil, lens, and vitreous normal.

By ophthalmoscope.—Just above the optic disc is a soft, yellowish-white, slightly raised (+ 2) swelling beneath the retinal vessels, which curve over it; the edges of the swelling are soft. The optic disc looks a little pink, but is otherwise normal; there is no sign of fresh pigment or of changes elsewhere in the fundus.

Progress and treatment.—Patient was kept in bed and given small doses of mercury for three days, and the general health kept up by feeding.

Digitized by Google

January 14th.—Right eye. Swelling in retina the same, but retina a little œdematous near the swelling. Says she sees a small dark spot before right eye.

30th.—Patient says that the dark spot before right eye is much less apparent. *Ophthalmoscope.*—R. The swelling is apparently flatter, and the edges of disc are more distinct. V. $\frac{6}{18}$. J. 8 at 30 cm.

February 4th.—Patient much better in general health. *Right eye.*—V. $\frac{6}{6}$ one letter. J. 1, few words at 30 cm. *Ophthalmoscope.*—The patch of effusion is less and scarcely raised; the edges of optic disc still rather blurred.

27th.—R. V. $\frac{6}{6}$ all but two letters. *Ophthalmoscope.*—R. Still patch above, but no signs of swelling; edges of disc nearly clear.

March 23rd.—Patient does not complain of seeing the dark spot. R. V. $\frac{6}{5}$ partly. *Ophthalmoscope.*—Upper part of optic disc still hazy, and superior veins a little dilated. Over region of former patch the retina is greyish, and has want of transparency.

February 25th, 1902.—R. V. $\frac{6}{5}$; L. V. $\frac{6}{5}$. No scotoma, and patient says everything is quite clear with right eye.

Ophthalmoscope.—R. The retina above the disc has still a semi-opaque look, but this is simply slight thickening of the retina. Vitreous quite clear.

February 20th, 1903.—Condition the same.

Remarks.—These two cases are especially interesting, as they have been under observation from the commencement of the ocular lesions. I think there cannot be the slightest doubt of the lesions being tuberculous in each case. In Case 1 the sclerotic mass was proved to be tubercular, and the child had also several other tubercular foci. In Case 2 the tubercle bacilli found in the mammary cyst showed evidence of the disease, and the ophthalmoscopic appearances were characteristic. Both cases were in females, and in each one eye only was affected.

In Case 2 the ocular signs have completely cleared up,

Digitized by Google

and the changes in Case 1 are gradually doing so. The vision and field of vision in Case 2 are normal, and in Case 1 have improved from P. L. to $\frac{6}{18}$ partly. Case 1 has been under observation for 18 months, and Case 2 for 3 years and 4 months.

As to the sequence of the intra-ocular changes in Case 1, the first observed were two large whitish masses, to begin with, obscuring the disc; this taken in conjunction with the scleral mass, and a slightly lowered tension, suggested that the sclerotic might have been perforated, and by this means the interior of the eye invaded. This, however, proved not to be so. These masses, which were rounded and raised, gradually sank downwards, and from the disc a greyish-white, fibrous-looking, sheath-like band proceeded. This became elongated as the greyish detachment moved towards the periphery; two other fibrous bands appeared, and on either side of disc a soft whitish effusion appeared, more marked at nasal side. This effusion gradually became less on nasal side and increased at temporal side, the original mass moving towards temporal side, and still more peripheric; gradually the effusion round disc became absorbed, leaving soft small patches, and some small cholesterin patches. A patch of detachment was left between O. D. and peripheral changes, and the two lines of stretching were still left. There were never any vitreous changes or marked pigmentation.

In Case 2 the small choroidal mass gradually became absorbed, leaving no marked traces beyond a slight layer at upper part of O.D.

The points I think these cases chiefly emphasise are the almost complete absence of pathological pigmentation, the absence of new vessels (seen by ophthalmoscope), and the absence of vitreous opacities. In Case 1 there was a tendency to *minus* tension. Another point is the complete resolution of the tubercular mass in Case 2, and also the little effect observable by the ophthalmoscope in the fundus of Case 1 after the masses of tubercle had moved towards the periphery.

Digitized by Google

In a recent very interesting paper * by Dr. George Carpenter and Mr. Sydney Stephenson on "Tuberculosis of the Choroid," the authors sum up their experience from notes of 42 unselected cases of acute miliary tuberculosis and tubercular meningitis, in which 21 were found with tubercle of the choroid (50 per cent.), and from 119 cases of chronic tuberculosis, in which 11 (9·24 per cent.) were affected.

Such large percentages, especially in chronic tubercular cases, is a fact of the highest importance as far as diagnosis is concerned. In cerebral tumours of a tubercular nature it is especially important.

Since 1880, when I was house-physician at the Royal Chest Hospital, I have examined numerous cases of acute miliary tuberculosis and tuberculous meningitis, but have rarely seen choroidal tubercles by the ophthalmoscope in my cases—roughly speaking, I should say in about 2 to 5 per cent., and then only a few hours or days before death.

As to choroidal changes of a tubercular nature in cases other than acute miliary or tubercular meningitis, I have observed only these two cases.

In conclusion, I would ask for information from Members of the Society on the subject of diagnosis in such cases, and also as to the frequency of choroidal tubercle. Is it a fact that by the ophthalmoscope in cases of tubercular choroiditis there is little tendency to pigmentation or scarring of the retina, and that vitreous opacities and new vessels are conspicuous by their absence? (*May 8th*, 1903.)

Mr. Sydney Stephenson said Mr. Jessop had referred to the paper by Dr. George Carpenter and himself, in which, amongst other things, it was brought out that chronic surgical tuberculosis was, in a considerable proportion of cases, associated with choroidal tubercle. As

* *Reports of The Society for the Study of Disease in Children*, vol. i (1901), p. 169.

Digitized by Google

far as he remembered, they made out that nearly 10 per cent. of such cases showed choroidal changes. The figures dealt with in that paper were only about 100; since then, however, they had been extended considerably, but there was but little difference in the percentage. Therefore they had come to the conclusion that where the actual diagnosis of tubercle was uncertain, it was advisable to examine the eyes with the ophthalmoscope. With regard to the ophthalmoscopic diagnosis of tubercle, he believed Mr. Jessop's statement to be borne out by clinical experience. He only remembered one case of definite tubercle of the choroid which was associated with vitreous opacities, and in that case there was reason to believe that the ciliary body was also affected with tubercle, so that very likely the vitreous opacities were derived from the ciliary body. The absence of pigmentation was certainly a sign of some importance in the earlier cases of tubercle. But in some cases, apparently of long standing, pigmentation became rather a marked feature, especially in the form of rings or circles around the patch. From Mr. Jessop's description he would think that clinically there was little doubt that the two cases described by him were examples of tubercle of the choroid. At the same time, it was necessary to remember that neither had been confirmed pathologically.

Mr. JULER asked what treatment Mr. Jessop employed; did he inject anything into the subconjunctival tissue? He had seen a case recently which was under the care of Mr. Stephenson, in which a boy apparently had tubercular trouble in the fundus, and seemed to be cured by the subconjunctival injection of saline solution of cyanide of mercury, 1 in 5000.

Mr. JOHNSON TAYLOR asked whether the open-air treatment was good for such cases. He would like to hear how the late cases in which there was decided pigmentation could be distinguished from cases of congenital syphilis which were suffering from choroiditis.

Mr. HOLMES SPICER said he understood Mr. Stephenson

Digitized by Google

to say the cases were those of "surgical tuberculosis," and he would like to hear his definition of that term. The cases described were very rare to him (Mr. Spicer), and he did not know whether he had been in the habit of considering those which were tubercle as something else. Perhaps Mr. Stephenson could bring some such cases to the Society for Members to see.

Mr. SYDNEY STEPHENSON, in reply, said by the expression "surgical tuberculosis," as he understood it, was meant such common tuberculous affections as enlarged glands in the neck, lupus, chronic inflammations of joints, and so on. He did not defend the expression, but he thought it would convey a meaning to most people. Of course, those choroidal conditions described by himself and Dr. Carpenter were rare if they were not sought for. His cases were obtained in a very simple way. When his attention was drawn to the frequency of acute tuberculosis of the choroid, he took the trouble to obtain at a children's hospital the names of many children whose cases had been diagnosed as tuberculous glands or joints or lupus; and he got more than 100 such children to come to the hospital. He dilated their pupils with a mydriatic, and made a careful ophthalmoscopic examination. His figures were derived mainly from that source. As to whether it was easy to tell the difference between specific and tuberculous choroiditis, theoretically it might be very difficult, but practically one must judge by the antecedents and concomitants of the case. In the cases of obsolescent tuberculosis described by himself and Dr. George Carpenter, the lesion, as a rule, was solitary, fairly large, and situated in the central part of the fundus. It often took the form of a more or less circular lesion containing one or more pigment rings, and very seldom indeed was associated with outlying changes in the shape of peripheral choroiditis. That offered a contrast to the ordinary cases of specific choroiditis, in which the changes were, as a rule, more marked in the periphery than in the centre of the fundus, and were distinctly multiple.

Digitized by Google

Again, in tuberculosis cases there was a family or personal history of tubercle obtainable. He remembered a woman, about 53 years of age, who came to him to be examined in the ordinary way for her refraction. In the course of the examination, such a lesion was discovered in the fundus of one eye. As soon as he saw it, it suggested to his mind that it might be tuberculous, and he ascertained that thirty years previously she had been under treatment at Brompton Consumption Hospital on account of what she called "threatened consumption." On further examination, he found she had signs of old consolidation of the left apex of one lung; and it therefore seemed to him reasonable to conclude that the lesion in her fundus was a tuberculous one. Clinically it was reasonable to suppose that his diagnosis was correct; and he reminded the Society that of the large number of cases published by himself and Dr. George Carpenter, more than half were confirmed pathologically and bacteriologically, but these were mainly cases of more or less acute tuberculosis of the choroid. The difference of opinion, he thought, was in respect of the so-called cases of obsolescent tubercle of the choroid, which owing to the very nature of the cases, can seldom be submitted to pathological examination.

Mr. JOHNSON TAYLOR said he was not alluding to the solitary lesions, but in the paper referred to Mr. Stephenson and Dr. Carpenter spoke of a fair number of patches at the periphery, pigmented, and when he read that paper he thought that those cases seemed like the old-fashioned cases of hereditary syphilis. He did not refer to large patches in the yellow-spot region with a good deal of exudation, but those cases in which later on pigmentation was rather a feature.

Mr. SYDNEY STEPHENSON, in further reply, said in the paper referred to it was pointed out that the authors did not come across the text-book form of tubercle of the choroid—those in which there were a number of lesions; they were nearly always solitary and somewhere in the

Digitized by Google

neighbourhood of the optic disc, whether they were cases of acute or chronic tuberculosis of the choroid.

Mr. JESSOP, in reply, said he was glad to have heard the discussion, partly because he had not been able to hear Mr. Stephenson's original paper, and therefore did not see the cases. He had looked through that paper, and in one case which was said to be tubercle there was a perfectly white patch in the sclerotic, bordered by deep pigment. Looking at those cases, and another which Mr. Stephenson mentioned in the paper—one which he, Mr. Jessop, thought was almost always a change due to congenital syphilis,—he thought they were the only cases which had been demonstrated in the paper all through. In regard to Case 1, which Mr. Spicer saw many times at St. Bartholomew's Hospital, if there was ever extreme pigmentation after tubercle it should have been seen. There were masses 4 mm. high, apparently filled with caseous material, which simply settled down after moving about under the retina, and left very little trace behind. In the other case, which was slighter, there was no pigmentation. It was known that miliary tuberculosis showed no pigmentation. Those who had been attached to consumption hospitals knew that a great many of the children with hereditary syphilis contracted phthisis, and he wished to know whether those cases could be truly said to be tubercle. The question of pigmentation was the chief one he wanted cleared up. He had not tried toxin treatment in these cases. He was in the habit of sending tubercular cases to Margate when practicable. He had seen subconjunctival injections employed in France and in Germany. The injections seemed at first to produce an enormous exacerbation, but then the condition seemed to quieten down and ultimately to get well.

Digitized by Google

3. ? *Tuberculous choroiditis.*

By Leslie Paton.

Arthur P—, æt. 8 years, was brought to Mr. Gunn's clinique on June 3rd. History of not being able to see out of left eye. Has had squint since two or three years of age. Mother first noticed that he was blind four months ago.

Present state.—Left pupil does not react to direct light stimulus, but reacts consensually. Fundus shows a swelling of white translucent appearance obscuring the disc, with coils of blood-vessels running over the surface. A distinct parallactic movement of these vessels over the deeper parts of swelling, as if there were some transparent fluid separating the vessel layer from the deeper parts of the swelling. At the lower part of the swelling there is a dark pigmented patch seen dimly through the swelling. The top of the swelling seen with + 4·5 D. In the neighbouring parts of the fundus there are small areas of white exudation and larger areas of pigmentary disturbance. Projecting into the vitreous in front of the swelling is a greyish veil coming to a point.

There are enlarged glands in the neck. Mother has had seven children, of whom this is the second youngest. There was one miscarriage after first child was born. The other children are healthy.

June 17th.—The swelling seemed a little greater, *i. e.*, over + 5 D.

July 1st.—The swelling does not project further into vitreous, but has extended horizontally in the nasal direction above, and there seems to have been a greater development of vessels in that direction. The pigment at the lower part seems clearer.

(*Card specimen. July 3rd*, 1903.)

Digitized by Google

4. *Unusual retino-choroidal changes; ? the result of hæmorrhage, and due to fibrinous deposits in the deeper layers of the retina.*

By Arnold Lawson.

The history of this case throws no light on the changes observed in the right fundus. Patient does not know how long the eye has been defective. There is no history of injury, and the past and family history of the boy is good. The patient is 9 years of age.

R. V. / L. V. $= \frac{6}{6}$ easily. Jaeger 1.

The fundus is largely occupied on the outer side by a large white *plaque*, over which the retinal vessels course. The affected area has a peculiar soft woolly appearance, and at the extreme outer periphery of the fundus the *plaque* gradually shades off into hæmorrhages, which are abundant. The inner outline of the affected area is highly mottled, and many cholesterin crystals may be seen. The disc is fluffy and the vessels tortuous, and around the disc, but chiefly on its outer side, there is a general area of œdema and whitish exudation, which is bordered on the outer side by an area in which the fundus reflex is much darker, and which passes into the mottled fringe lining the large white *plaque* already alluded to. It may be noted that the inner margin of the large white area is irregular, and this is obviously caused by the changes commencing in connection with the main trunks of the central retinal artery, so that where there are no large vessels the outline of the affected area exhibits an indentation.

Just below and to the outer side of the disc may be observed a roughly circular patch rather larger than the papilla, which is distinctly raised, and presents some speckled black pigment on its surface.

Digitized by Google

The condition at first sight is suggestive of albuminuria; but the other eye is healthy, and the urine has been examined several times and has always been found quite normal, with a specific gravity of 1020. With a view of ascertaining whether the boy was in all respects healthy, I took him into Hospital for a fortnight, and he was carefully watched and thoroughly examined, with the result that no derangement of any organ could be detected, and the boy was reported to be perfectly sound in every respect. The other eye is quite normal in every way.

I believe the condition is probably analogous to the so-called retinitis circinata, and that the white patch is mainly due to the extensive deposition of fibrin.

(*Card specimen. December 11th,* 1902.)

The CHAIRMAN (Mr. William Lang) said Mr. Lawson's case was extremely important. There was a good deal of swelling in the periphery, and it reminded him of a case which he watched carefully for some months many years ago. Eventually he excised the eye and found a sarcoma. It was a formation running along the surface, not heaped up in the ordinary way. It was accompanied by exudation and hæmorrhages. He thought it most important that Mr. Lawson's case should be kept under careful observation.

Mr. W. H. H. JESSOP asked if there was any history of tubercle in the case. He had a case almost exactly like it, in which the tubercle had been going on for the last nine months, and he had been watching the changes all through. There was great detachment, and more hæmorrhages and pigmentation in Mr. Lawson's case than in his own.

Mr. LAWSON, in reply, stated there was no evidence of tubercle in his patient, who had been thoroughly examined.

Digitized by Google

5. *Case of detachment of retina.*

By A. Q. Silcock and A. F. MacCallan.

A. H—, æt. 32 years, a glazier by occupation, came to the Royal London Ophthalmic Hospital on August 19th, 1902, complaining of defective vision in the right eye.

History.—The vision of the right eye became dim about three or four months ago. He has had no pain. There is no history of injury to the eye. No specific history can be obtained; there is a liability to chest complaints in his family.

Present condition.—In the lower and outer part of the fundus of the right eye the retina is detached over a considerable area. The retina, where detached, is partially opaque; it does not vibrate with movements of the globe. The highest part of the detachment can be seen with a + 8 D. lens. At the inferior limit of the detachment the slope from the normal fundus to the detached area is steepest. The temporal limit of the detachment cannot be made out. Near the temporal border of the detachment are some spots of pigment, probably choroidal. On the steep inferior edge of the detachment there is a pigmented spot, which differs in character from the other pigment spots in that it appears to be at a deeper level; in its neighbourhood several small hæmorrhages are seen. Between the second branch of the superior temporal vein and the disc is a small hæmorrhage. This is now in the course of absorption, but was of considerable size a fortnight ago. The vitreous is clear. V. = $\frac{6}{16}$. The visual field shows a peripheral limitation, most pronounced in the upper-inner quadrant. L. V. = $\frac{6}{6}$. Fundus normal.

Remarks.—The man has had antisyphilitic treatment

Digitized by Google

for two months, during which time his vision has remained the same. (*Card specimen. October 16th*, 1902.)

Postscript.—The eye was excised. Pathological report by Mr. J. Herbert Parsons is as follows:

The globe was hardened in ten per cent. formol, frozen and bisected in a direction nearly sagittal, but slightly down and out.

Macroscopic examination.—There is an oval tumour extending down and out from the macula, the long axis (in this direction) being 10 mm., the short axis 8 mm. The upper edge is about 2 mm. above the level of the macula. There is a simple detachment of the retina, rather larger in size, below the tumour. Here the subretinal space contains an albuminous coagulum. The surface of the tumour is mottled grey; its edges are black. There is an oval patch on the temporal side, 4 mm. behind the ora serrata and about 8 mm. above the horizontal meridian. It is about 2 mm. long (vertically) and 1 mm. broad, deep reddish with a lighter centre, and surrounded by a grey line. It will be seen that this is far removed from the growth and in front of the ophthalmoscopic field.

Microscopical examination.—Cornea, a. c., iris, and lens normal. The tumour is a typical spindle-celled melanotic sarcoma of the choroid. The pigment is irregularly distributed, and is well-marked at the edges of the growth.

The small anterior patch was cut separately. It consists of an area of fibrous degeneration of the retina. The choroid beneath is intact. The retina in the centre is reduced to a shred of fibrous tissue. At each side remnants of the nuclear layers are seen amongst the fibrous tissue, which is thicker. Here there is on each side a mass of proliferated pigment-cells on the inner aspect of the tissue, closely adjoining the nerve-fibre layer on one side. A little further out the retinal layers are intact except the rods and cones, which also become normal a very short distance further out. This patch was

Digitized by Google

probably the result of a small hæmorrhage at some previous time, and most likely was quite independent of the tumour. It is of importance in that, if it had been visible ophthalmoscopically, it would have been evidence against the diagnosis of a choroidal tumour.

(*Card specimen. October 16th*, 1902.)

Mr. E. NETTLESHIP thought the case was one of choroidal tumour; and although the absence of a sharply defined boundary was a somewhat unusual feature, the solid appearance of the mass, its steady though slow increase in spite of treatment (as he understood from Mr. MacCallan, the house surgeon) by mercury for six weeks past, and the absence of opacity of the vitreous, were all against its being of gummatous or other non-malignant nature.

The CHAIRMAN (Mr. W. Adams Frost) also offered some remarks upon the case.

---

6. *Numerous instances of night-blindness (retinitis pigmentosa) occurring in five generations, with genealogical chart.*

By SIMEON SNELL.

RICHARD T—, æt. 46 years, came to the out-patient department of the Sheffield Royal Infirmary on October 28th, 1902, complaining of failing eyesight. It was ascertained that he had never been able to see properly at night, and that since childhood he had found it difficult to go about in the dark. He had never seen the stars. His eyesight had been fairly good during the daytime, though gradually failing, until six years ago, when it began to become worse more rapidly. For the last $2\frac{1}{2}$ years the patient had been altogether unable to do his work. He could not now find his way about even in daylight, and

Digitized by Google

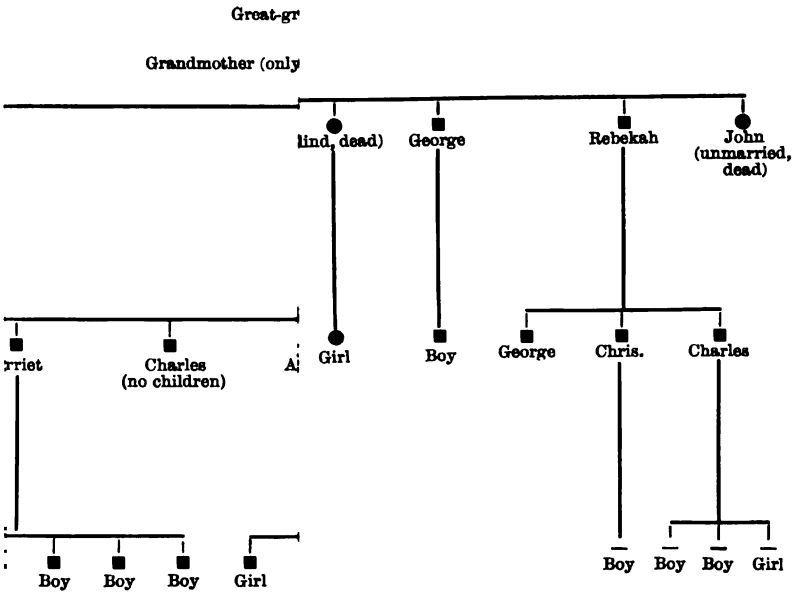

o, however, died in early infancy.

Digitized by Google

Digitized by Google

had to be led. V. = R. $\frac{2}{60}$, L. $\frac{1}{60}$. The ophthalmoscope disclosed a typical picture of retinitis pigmentosa, the pigmentation being especially marked at the periphery of the retina, but not reaching as near the papilla as is often seen in such an advanced stage of the disease; the discs were white and waxy-looking. In each eye there was posterior polar opacity of lens. The field of vision in each eye was restricted to the fixation point, the right being a trifle the better of the two.

The particular interest of the case centred in the fact that he was a member of a family in which large numbers were similarly afflicted with night-blindness. This fact was well recognised in the family, and our patient was remarkably well acquainted with all the branches of his family, and quite familiar with those who were or were not afflicted. He was accompanied on his visits to me by his sister, who was normal-sighted, and with his and her assistance the following remarkable genealogical tree was constructed.

In some instances, when the number of children in a family was at all in doubt, the sister obtained the correct information by letter. I believe the chart to be very exact. It is true that the patient is the only one,* except the sister who is normal-sighted, who has been examined by me, but the history of the family is unfolded in such a way as to leave no doubt, I think, as to the other members being similarly afflicted. Here I must record the assistance Miss Norah Lenwood, M.B.Edin., has rendered me in working out this interesting family history.

It will be observed, on reference to the chart, that it commences with the patient's great-grandfather; nothing is known of any previous ancestor, and no legend exists of any one earlier than he having suffered from night-blindness. Our patient is unaware who this great-grandfather married, but he thinks it was not a blood-relation.

* Since this was written, I have seen two others, *viz.*, Edward, son of Harriet, and one of his daughters (Clara). In each the condition was typical.

Digitized by Google

It is known that he went stone-blind and died in old age. He left a daughter, an only child,* who suffered from night-blindness, and became blind at thirty. She left six children —four afflicted and two not. It is through her that the numerous family the chart represents is descended. Her husband was not a blood relation, nor is there any evidence of consanguinity in any of the marriages. It is interesting to note that the hereditariness of the night-blindness descends in all instances without a break; no generation is skipped over, and it runs equally through the female and male lines. There is, moreover, no instance apparently of an unafflicted son or daughter by the grandmother having transmitted the malady to his or her children or grandchildren. Out of the total of 71, including the great-grandfather and grandmother, 29 were afflicted and 42 not. Fifteen of the afflicted were females and 14 males. The patient is the father of 11 children; 8 are afflicted and 3 are normal-sighted. Six of the former are boys and two girls. His father had an equally large number of children, 5 being afflicted and 6 not.

The night-blindness appears in all the instances to have shown itself in early childhood—as soon, indeed, as the boy or girl began to walk about. At about the age of forty or rather more, in some instances younger, those affected have become practically blind.

(*November 14th*, 1902.)

The CHAIRMAN (Mr. A. S. Morton), in discussing Mr. Snell's paper, said he thought it was very interesting on account of the large family history, and especially interesting in the absence of any history of consanguinity. He had his own doubts as to how far consanguinity was a cause of retinitis pigmentosa. In asking systematically about consanguinity in a large number of cases, he had been struck by the infrequency of such a history.

* I have been informed that she (the grandmother) had one sister, who died in early infancy.

Digitized by Google

7. *Retinitis proliferans and detachment of retina.*

By G. M. Scott, M.D.

D. J. S—, æt. 29 years, gold miner, unmarried, came on February 9th, 1902, complaining of loss of vision in R. Three months previously he had first noticed that a "dark shade" would come down over the R. for a few moments at a time; this was most noticeable when lying down.

R. V. = $\frac{3\cdot5}{24}$; no improvement with glasses.

L. V. = $\frac{3\cdot5}{5}$, $\bar{c}$ − 0·50 D. = $\frac{3\cdot5}{3\cdot5}$.

Pupil reactions normal. Tension: R. − 1; L. ?−.

R. fundus.—The disc obscured by a large, floating, star-shaped growth extending some way into the vitreous. In the anterior part of the lower-outer quadrant was a large hemispherical projection, with bright double-contoured edge, and with a "shot silk" appearance at one spot.

L. fundus.—Inner edge of O. D. slightly blurred; a small, old hæmorrhage in upper-outer quadrant; the details of the fundus in the same part best seen with + 5 D.

There was no appearance suggestive of hydatid in R.

The patient denied having had syphilis, and there was no history of a blow. Heart and lungs sound. Urine, no albumen or sugar.

When seen again on March 18th, 1902, the excrescence from the R. O. D. had increased in size. The entire O. D. was hidden by the outgrowths which appeared to spring from it, and which projected far forward into the vitreous, one of them almost touching the back of the lens. They might be compared to tissue-paper that had been crumpled in the hand, although whether the longitudinal marks were due to wrinkles or to minute vessels

Digitized by Google

it was impossible to determine. In each of the projections there were one or two darker lines which were certainly arteries or veins. There were also streaks and dots in the anterior part of the vitreous unconnected with the O. D. The projection in the lower-outer quadrant now had two outgrowths springing from it.

The patient refused all treatment, excepting that he took a mixture containing iodide of potash.

On September 30th, 1902, the patient again presented himself, stating that the L. had suddenly gone blind two days previously. V. = P. L. only. The ophthalmoscope showed a total detachment of the retina, a floating grey mass being the only thing visible behind the lens. *R.*—All the floating, feathery outgrowths had disappeared excepting the long, thin one from the upper part of the detachment. The O. D. is pale, the outline not sharp, and the retina around shows pigmented spots. Arteries and veins are much shrunken. The projection in the lower-outer part now no longer has the appearance of a distended bladder, but shows the ordinary aspect of a simple detachment of the retina, with wavy surface not much in advance of the choroid, and wavy vessels. T.—2. Vision not recorded; but the man found his way to my consulting room unassisted.

I very much regret that I was unable to watch this interesting case more closely and to treat him more energetically, but he absolutely refused to go into hospital, and it was only after writing to him frequently that he was induced to pay me a second visit.

(*June 11th*, 1903.)

Digitized by Google

Digitized by Google

PLATE V.

FIG. 1 illustrates Mr. J. Herbert Fisher's case of Aneurismal Dilatations on Diseased Retinal Arteries (p. 73).

FIG. 2 illustrates Mr. Rayner D. Batten's case of Obliteration of a Retinal Vessel (Vein), with Formation of New Vessels (p. 75).

Digitized by Google

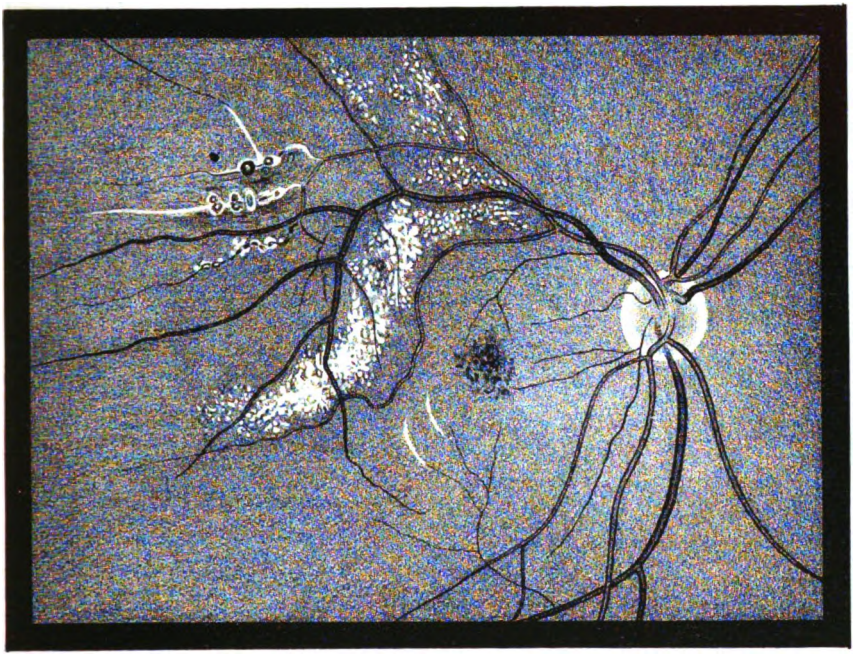

Fig 1

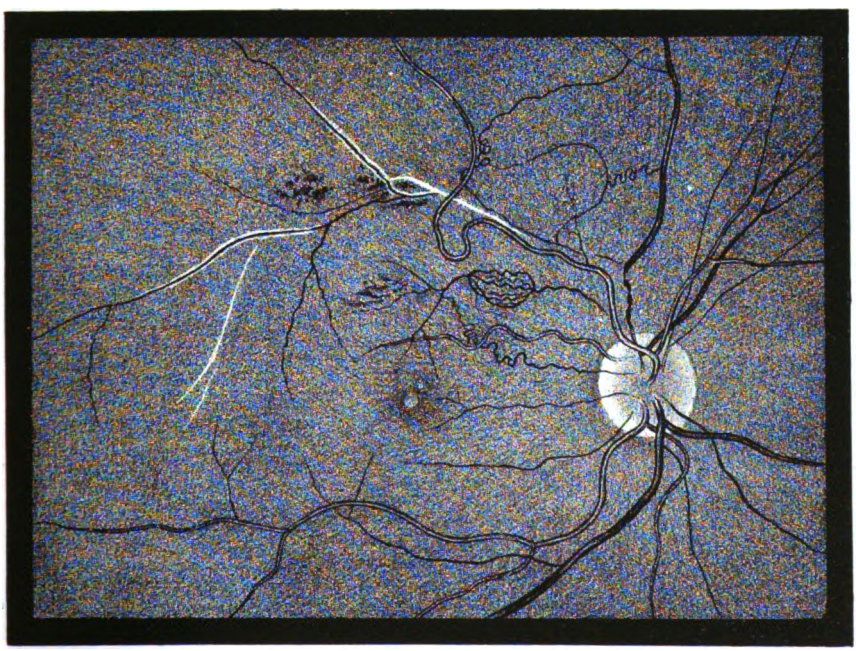

Fig. 2.

Digitized by Google

Allard & Son

Digitized by Google

8. *Aneurismal dilatations on diseased retinal arteries.*

By J. Herbert Fisher.

(With Plate V, fig. 1.)

A. Q—, æt. 13 years, male, came to the Moorfields Hospital on December 6th last, the vision of the eyes having been found defective.

His father died of phthisis; his mother has had ten children, of whom five died under two years of age; but the history does not strongly suggest inherited syphilis, and the patient himself shows no stigmata.

Rheumatic fever when æt. 5 years; when æt. 7 years was in-patient at Children's Hospital, Hackney, for cardiac trouble.

Boy is thin and poorly nourished; urine is normal; heart enlarged and dilated, especially to the left; heart-sounds weak; the first over the mitral area is replaced by a long, soft, systolic murmur.

R. V. $\frac{6}{24}$ badly; L. $\frac{6}{12}$ badly. Under atrop.: R. + 1·0 D. cyl. = $\frac{6}{24}$ well; L. $\frac{+\ 0{\cdot}5\text{ D. sph.}}{-\ 3{\cdot}5\text{ D. cyl.}} = \frac{6}{6}$.

Ophthalmoscopically.—R. Some white, glistening, retinal change forms a large *plaque*, not quite homogeneous, immediately beyond the macula in an upward and outward direction; to the outer side of this are two diseased arteries, in places of great brilliance, whose coats show a series of small local dilatations of aneurismal character; the aneurysms are closely set, rendering the arteries beaded, and number three or four on each. There are patches of white retinal degeneration in the temporal and upper nasal peripheries, and in the latter situation can be found one or two further examples of aneurismal swellings on arteries. The veins generally are conspicuously moniliform in calibre. L. fundus normal.

Digitized by Google

Progress.—December 20th, 1902.—The changes are progressive. The second row of aneurysms is more distinct, and each swelling is now surrounded by a grey haze.

January 3rd, 1903.—A few flecks of reddish colour near the diseased arteries appear to be hæmorrhages.

10th.—The aneurysms of the second row are now almost as well-defined as those of the first; a third row parallel to and below the others is now becoming a conspicuous feature on an arterial branch before scarcely visible.

24th.—No material change since last examined. The patient's general condition has improved since taking cod-liver oil the last six weeks.

(*Card specimen. January 29th*, 1903.)

---

9. *Embolism of central artery of retina in a young girl.*

By N. C. Ridley.

Alice L—, æt. 17 years. Six weeks ago patient, who seemed in good health, was frightened by the fainting of a friend in the street. She discovered immediately after that she could not see with the left eye.

Previous history.—Has had rheumatic fever and chorea; also psoriasis.

Condition on first examination (three days afterwards).—R. normal. L. Vision limited to perception of light over a small area to outer side. Fundus.—The whole retina, including disc, hidden to a great extent by pale exudation, both in substance of retina and on its surface. The only normal-looking area is the space between the disc and macula. Vessels are not diminished in size, but are rather more curved than normal. Macula itself is dark red with a feathery extension inwards, looking like a hæmorrhage.

Digitized by Google

Present condition.—The exudation has gradually disappeared till now it is present only in lower part. The vessels have gradually and uniformly contracted. The macula presents the appearance of old choroido-retinitis with atrophy. The disc has become paler. Vision has improved slightly. Patient can count fingers at 1 ft. to outer side.

Dr. Sevester reports a systolic murmur at the apex, due to mitral regurgitation; lungs normal; urine normal.

Remarks.—The case is of interest because of—(1) the youth of the patient (the source of the embolus is probably a vegetation on the mitral valve); (2) the peculiar history of the occurrence, leading one to expect, before examination, a mere temporary neurosis.

(*Card specimen. December 11th*, 1902.)

10. *Obliteration of a retinal vessel (vein) with formation of new vessels.*

By Rayner D. Batten.

(With Plate V, fig. 2.)

Mrs. S. D—, æt. 68 years. R. V. = $\frac{6}{36}$; L. V. = $\frac{6}{18}$.

Right eye.—The temporal branch of the upper retinal vein appears obliterated and converted into a white streak in the greater part of its course; towards the periphery it appears patent, but as a red streak with a white border. Above and below the obliterated vein there are numerous changes in the retinal vessels, with formation of new vessels. Some smaller vessels appear to anastomose. There are various small hæmorrhages. One vein (?) breaks up into numerous small vessels, which again unite and continue their course as a single vessel.

Digitized by Google

Left eye.—There is very marked beading of veins and constriction of veins where crossed by the arteries. The macular region is occupied by a large circular patch of superficial choroidal atrophy.

The patient has been under observation since 1901. Urine: no sugar; no albumen.

(*Card specimen. June 11th,* 1903.)

Digitized by Google

Digitized by Google

PLATE VI.

Illustrates Mr. L. Werner's paper on Two Cases of Primary Intra-dural Tumour of Optic Nerve (p. 77).

FIG. 1.—Remains of degenerated nerve shown at apex of triangle above, and tumour tissue below; both lie within the dural sheath.

FIG. 2.—Section through tumour inside nerve sheath, showing whorled arrangement of cell groups. × 400.

FIG. 3.—Shows the general appearance of the new growth, the stroma of fibrous tissue radiating outwards from the pial sheath, which is seen to the left and below, with a portion of the optic nerve. × 20.

FIG. 4.—Transverse section through nerve alone, showing increase of connective-tissue elements. A portion of pial sheath is visible to the left and the central artery to the right. × 20.

Digitized by Google

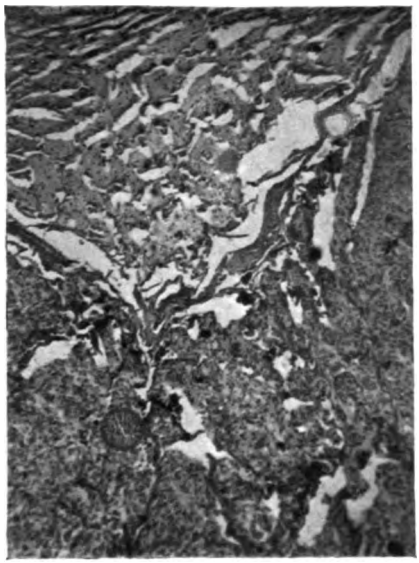

Fig. 1 (Case 1).

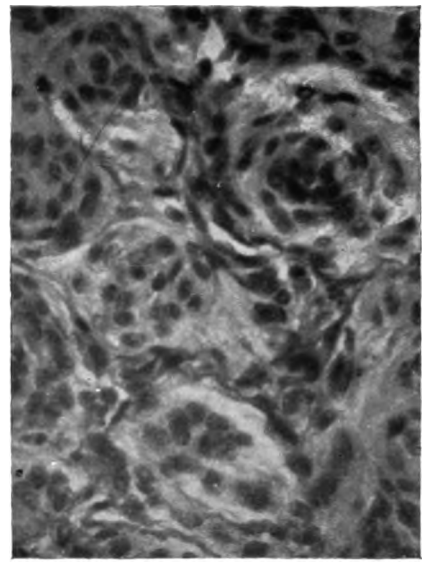

Fig. 2 (Case 1).

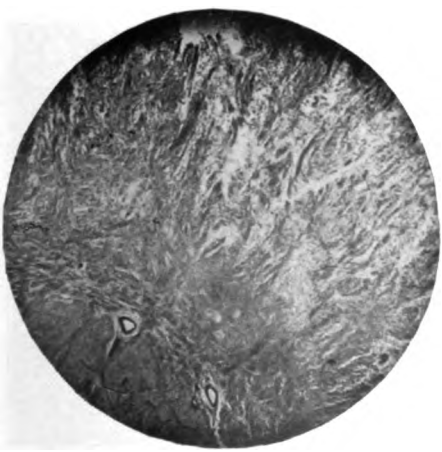

Fig. 3 (Case 2).

Fig. 4 (Case 2).

Adlard & Son, Imp.

Digitized by Google

Digitized by Google

VII. DISEASES OF THE OPTIC NERVE.

1. *Two cases of primary intra-dural tumour of the optic nerve, in one of which the tumour was removed by Krönlein's operation, with preservation of the eye.*

By L. Werner, M.B. (Dublin).

(With Plate VI, and Figs. 2 and 3 in text.)

Three cases of this rare affection have come under my observation. One, which has recently been published, was under the care of Mr. Swanzy (29).* The other two are described in this paper. They are all primary intra-dural tumours.

Case 1.—Patient, a stout, healthy woman, æt. 45 years, was admitted to the ophthalmic ward of the Mater Misericordiæ Hospital in June last. Her family and early personal history revealed nothing of importance bearing on her present illness.

Twelve months before admission she noticed a slight swelling above the inner canthus of the left eye, which gradually began to protrude. She suffered no pain, with the exception of a burning sensation in the eye for the past fortnight, since when the protrusion has increased. She never had any headache or vomiting, nor did she ever see double.

The exophthalmos is very marked; the left eye is 2 cm. in advance of the right (Fig. 2). The displacement is chiefly in the direction of the axis of the orbit,—that is to say, forwards and somewhat outwards. There is also a slight downward displacement. Allowing for the position of the eye, the freedom of movement is considerable. The eyelids are normal in colour; the upper one is enlarged

* I am greatly indebted to Mr. Swanzy, who kindly lent me several journals and pamphlets, and also to Dr. W. G. Sym, of Edinburgh, for a copy of the *Austral. Med. Gazette* containing Pockley's case.

Digitized by Google

and covers the upper part of the cornea, but it possesses very little power of movement. The lower lid is pushed vertically downwards by the eye, which projects beyond it and renders it completely immovable. The exposed conjunctiva over the lower part of the eye is hyperæmic

FIG. 2.

Case 1. Tumour of optic nerve.

and œdematous, and covered with dry yellow crusts. It is impossible to feel any tumour in the orbit, but this may be due partly to the timidity of the patient, who shrinks from even gentle manipulations. The orbital margins are normal. No pulsation or bruit. The patient made no remark about her sight, and did not know that the eye was almost blind. V. = p. l. Optic disc white, atrophic; retinal veins a trifle larger than in the right eye, which is normal. The left pupil is very slightly larger than the right, and only acts consensually. Tension normal.

Digitized by Google

The diagnosis in this case presented no difficulty. The painless development of the proptosis, the direction of the displacement, the comparative freedom of movement, the difficulty of feeling any tumour, combined with atrophy of the optic nerve, all pointed to the presence of a growth

FIG. 3.

Case 1, after operation. Tumour of optic nerve.

within the muscular cone, or, practically, a tumour of the optic nerve.

I decided to remove the tumour by Krönlein's method, and to preserve the eye, although it was blind.

On the day of the operation (June 12th, 1902) I was annoyed to find a small purulent infiltration near the lower exposed margin of the cornea. However, it did not alter my decision, and I had no cause to regret it. The patient was prepared in the usual way for operation. The side of the head was cleansed and shaved, and an aseptic

Digitized by Google

dressing applied the night before. When the patient was anæsthetised, a solid tumour could be felt with the greatest ease behind the eyeball.

The skin having been washed with ether, followed by corrosive sublimate, a semicircular incision was made, commencing at the temporal ridge about 1 cm. above the level of the orbital margin, passing downwards in front of it, and curving backwards along the zygoma. The centre of the incision lay midway between the outer canthus and the margin of the orbit. The periosteum, having been divided along the latter, was separated from the outer wall and floor as far as the spheno-maxillary fissure. The external angular process of the frontal bone was chiselled through at its base, and the bony incision prolonged downwards and inwards through the thin outer wall of the orbit to meet the spheno-maxillary fissure. In the same way, the frontal process of the malar was divided as far as the anterior limit of the fissure. The triangular piece of bone thus isolated was then turned back, still retaining its connection with the soft parts. The orbital periosteum having been divided horizontally and pushed aside, a large tumour became visible behind the eyeball, apparently growing from the under surface of the optic nerve. The tumour having been separated from the surrounding soft parts with the finger and the handle of the scalpel, the small portion of the nerve uniting it to the eye was cut close to the latter. Posteriorly the tumour filled up the apex of the orbit, and the scissors passed through the growth. The remainder was removed in two or three pieces, one of which was covered with smooth capsule on its posterior surface, but no trace of nerve was seen.

After removal of the tumour the eye could easily be pressed into its normal position, but, owing to hæmorrhage, it still had a little tendency to protrude. The cavity of the orbit was dusted with iodoform, and sutures were inserted in the skin flap. The eyelids were also closed with sutures, and dressings applied.

The progress of the case was most satisfactory. There

Digitized by Google

was no rise of temperature, and no swelling. The dressings were removed from the eye alone on the third day, as I was uneasy about the condition of the cornea. The lids were slightly œdematous, the eye immovable, and although the cornea was generally cloudy and quite anæsthetic, the infiltration had not increased. The dressing over the wound was adherent to it, and was taken off only on the fifth day, and the incision was found perfectly united. Subsequently I snipped off a fold of œdematous conjunctiva, which had been formerly exposed below. When the patient left hospital on July 17th, the eye had receded, the cornea although quite healed was anæsthetic, movements of the eye were returning, especially in the vertical plane, but there was still ptosis.

I saw the patient again a few days ago, and the eye was almost on the same level as the other (Fig. 3); it was normal in size and shape. T. — ? Cornea perfectly clear except for a faint nebula below, but still anæsthetic. Bulbar conjunctiva below also anæsthetic; the rest normal. No loss of sensation in the temporal region. Ptosis still complete. Mobility of the eye in the vertical plane very fair; only a trace of outward movement, none inwards. Some degree of divergent strabismus. The scar is freely movable and reduced to a narrow line. Margin of orbit quite regular.

Owing to some exudation in the pupillary area, the result of iritis, which occurred at the time the cornea was infiltrated (before operation), I was not able to get a clear view of the fundus. The only thing to be seen was some pigmentation in the shape of large irregular masses.*

I propose to remedy the ptosis and strabismus, and to give the patient, I hope, a very respectable eye, which will be free from the annoyances of an artificial one. She expresses herself as being greatly pleased at the result of the operation, and has not taken any notice of the scar.

* A very interesting account of the intra-ocular appearances and retinal circulation following on division of the optic nerve is given in Schlodtmann's paper (48).

Digitized by Google

Macroscopically the tumour is globular in shape. It measures 3·5 cm. in breadth by about 4 cm. long (when entire). It is enclosed in a capsule formed by the sheath of the optic nerve, of which it appears to be an expansion. The capsule is thin and peels off readily, leaving a smooth surface, which is slightly nodular. A portion of the optic nerve, 2 cm. in length, lies in a groove on the upper surface of the tumour. It is conical in shape, somewhat larger than normal in front, but widens out posteriorly, where it becomes lost in the tumour. Here the transverse diameter is 11 mm. Before removal the tumour felt rather hard, but when the tension was diminished by the division of the capsule it felt very much softer. The cut surface appeared to the naked eye pinkish white and finely granular.

Microscopy.—The specimen was submitted to Dr. E. G. McWeeney, pathologist to the hospital, who kindly made the following report:

"The tumour consists of medium-sized cells of indifferent type, with fibrillated protoplasm and ill-defined borders, so that accurate measurements are impossible. Their nuclei are oval or spindle-shaped, 4 μ to 7 μ in diameter. They take on the basic strain pretty deeply, and almost equally throughout, so that little or no intra-nuclear structure can be discerned. Traces of a nucleolus are, however, visible in some of the nuclei. Mitoses are not numerous.

"The general aspect of the cells is unquestionably mesoblastic or sarcomatous, and where they are oval in shape and lie parallel to each other, as is often the case, the section might readily pass for one of small spindle-celled sarcoma. The differences between this tumour and ordinary sarcoma are as follows:—(1) Complete absence of intercellular stroma; (2) grouping of the cells in rounded, oval, or irregular clusters, which are demarcated by strands of connective tissue which does not penetrate between the cells, an arrangement highly suggestive of carcinoma. This alveolar grouping of the cells is not universal. It is best marked towards the periphery, especially where it infiltrates the sheath of the optic nerve.

Digitized by Google

"A very remarkable feature of the cell groups is their tendency to assume a globular or whorled arrangement, like the coats of an onion (Plate VI, fig. 2). This depends altogether on the curved and flattened appearance of the nuclei, and their regular concentric arrangement. The boundaries of the individual cells composing these groups can hardly be seen at all. In the centre of the cell whorls no corpus amylaceum or other nuclear body can be made out.

"The stroma of the tumour consists of a delicate fibrillar connective tissue with elongated nuclei. As already mentioned, it divides up the tumour-cells into groups of various shapes and sizes. It does not seem to carry the blood-vessels, which are, indeed, very scanty both in number and size. Such vessels as are met with seem to come into direct apposition with the tumour-cells. They are so few and small that one is forced to conclude that the neoplastic cells must have been bathed in highly nutritive and well-oxygenated lymph, as they show no signs of necrosis or degeneration.

"Although the sections were cut from various parts of the tumour in such a way as to include the nerve, both transversely and longitudinally, it was not possible to determine the point of origin of the tumour, nor to establish its histogenesis, any further than it was confined within the dural sheath. A perpendicular transverse ('frontal') section of nerve and tumour, where the former ran in a sort of groove on the upper surface of the latter, shows that what appears to be the nerve is in reality almost entirely composed of tumour tissue lying within the pial sheath. The nerve tissue proper is reduced to a flattened band not more than a millimetre thick and two millimetres wide, raised up on the tumour tissue and compressed against the upper part of the pial sheath. This part of the nerve has become split up into isolated groups of disorganised nerve-fibres, in most of which Weigert's nerve stain, after careful mordanting, failed to reveal any cylinders or myelin sheaths. The

Digitized by Google

nerve section is studded with round or oval nuclei of doubtful nature, the outline of the corresponding cell being invisible. Another part of the nerve, beyond the tumour and closer to the eye, showed numerous bundles of nerve-fibres with myelin sheaths and (seemingly) axis-cylinders. The component bundles were widely separated by dilated lymph-spaces.

"Coming finally to the question of nomenclature, the tumour is undoubtedly of mesoblastic origin and richly cellular. It is therefore, according to the present system of classification, a sarcoma. Some of the larger cells are of endothelial appearance, but the majority are too fibrillated and indefinite in outline to be termed endothelia. We must therefore adhere to the term sarcoma, and as the most typical parts of the growth display a well-marked segregation of the cells into groups, we must term this an alveolar sarcoma. The concentric arrangement of the cells is so marked a feature that I think it ought to be drawn attention to *ab initio*, and I therefore term this interesting tumour 'an alveolar sarcoma of the optic nerve with concentric cell groups.'

"The above description is based on serially cut, 5 μ thick, paraffin sections of formol-fixed material."

This tumour, therefore, according to the above description, is a sarcoma which exhibits an aveolar structure and a tendency to the formation of cell-whorls. Now both of these peculiarities are found in the endotheliomata. Moreover, the absence of laminated calcareous bodies, etc., does not exclude endothelioma, which may show no evidences of degeneration until a late stage. The only serious objection which Professor McWeeney raised against its being an endothelioma was the appearance of the cells, some of which in the section presented an endothelial character, but the majority of which were elongated and fusiform. Even this objection may not hold in the present case, as it has been demonstrated in several instances that cells which appeared in sections to be spindle-shaped, when examined in teased preparations

Digitized by Google

were found to be in reality flat and endothelial-like; so that until such an examination has been made, the question as to whether this tumour is an endothelioma or not cannot be decided. I may say that Dr. McWeeney quite agrees with this view of the question.

Case 2.—Patient, a little girl æt. 5 years, was admitted to the National Eye and Ear Infirmary in July, 1884, under the care of Dr. Fitzgerald, who kindly allowed me to publish the case. Fourteen months before she was brought to hospital, the right eye became divergent and then gradually began to protrude, until finally she could no longer close it. No pain. Tumour palpable above. Well-marked optic neuritis. The eye was enucleated on July 12th, 1885, with the anterior portion of the tumour attached to it. The rest was removed separately. In the course of a week a dusky swelling and induration of the upper lid and cheek took place.

On July 29th the child was anæsthetised, and on examination the inner surface of the upper lid was found to be infiltrated with a greyish substance, which extended into the orbit and occupied a large portion of it. The upper lid was divided vertically and scraped, and the orbit cleaned out, and chloride of zinc applied. A yellow slough gradually separated. A bad prognosis was given, and a fortnight later the child was removed from hospital by her Mother.

Macroscopically the portion of tumour which was removed with the eye was encapsuled. It was somewhat flattened in front, and attached to the eye by a small piece of apparently healthy nerve 3 mm. in length. A transverse horizontal section of the eye and tumour showed that the larger portion of the latter was to the outer side of the nerve, which could be plainly seen passing through it. The transverse diameter of the tumour measured 15 mm. Its posterior surface, where it was divided during the operation, presented a delicate radial striation, passing outwards from the pial sheath to

Digitized by Google

the capsule of the tumour, which appeared to be formed by the dural sheath.

Microscopical structure.—A transverse section, 8 mm. from the eye, at right angles to the axis of the optic nerve, shows the latter in the centre enclosed in the pial sheath. The greatly enlarged intervaginal space is occupied by the tumour proper, and external to it is the dural sheath, only a portion of which is visible, the remainder having separated in making the section.

In the nerve the supporting connective tissue is greatly increased in thickness, even in its finest ramifications (Plate VI, fig. 4). The nuclei are also greatly increased in number. The spaces previously occupied by the nerve-fibres are empty, and show little or no sign of axis-cylinders. The lymph-spaces are dilated. The central vessels are normal, a fact which is rather unexpected, considering that they must have passed through the tumour. The ophthalmoscope had already shown that they were pervious.

The pial sheath, which shows no breach of continuity, is much thickened, and may be said to consist of two layers. The inner, which is well-defined towards the nerve, is loose in texture, as if the fibres were separated by œdema; whereas the outer is composed of dense, closely interwoven fibres, and forms what might be termed the base from which the tumour springs.

The new growth in the intervaginal space is fibro-cellular in structure. It consists of a framework of fibrous tissue, between which are irregular and anastomosing spaces filled with a network formed chiefly by the elongated processes of fusiform and branching cells. Many of the fibrous bundles can be seen arising from the outer portion of the pial sheath, and passing in a radial manner towards the surface, but none can be traced as far as the dural sheath. Numerous other bundles are cut across obliquely and transversely. No exudation is visible in the spaces (Plate VI, fig. 3).

The dural sheath is also much thickened, and presents an appearance similar to the outer portion of the pial

Digitized by Google

sheath, except that it contains a few myxomatous-looking patches. There are some of these even on the outer surface, as if the tumour were making its way through the sheath.

I only possess one imperfect specimen of the secondary growth. The sections were made in 1885, and I could not find the rest. The tissue removed seems to consist of connective tissue and fat in a state of inflammation, with newly-formed blood-vessels, and traces of the myxomatous type of structure occurring in the original tumour.

This tumour evidently belongs to the connective-tissue group, as will be mentioned later on, and springs from the pial sheath of the nerve. It corresponds to the cases known as fibro-myxoma or myxo-sarcoma. In many of these the presence of mucin has not been demonstrated, and some authors believe that the myxomatous appearance is the result of œdema.

This patient, who is still alive, had an operation performed a few years ago to enable her to wear an artificial eye.

Krönlein's operation.

The resection of the outer wall of the orbit in order to reach the orbital cavity, now known as Krönlein's operation, was first performed by him in 1886 for the removal of a dermoid cyst, and a description of the operation was published in 1889. In 1893 Braunschweig removed a tumour of the optic nerve by this method, and was the first ophthalmic surgeon to practise it. It has been performed many times since, but, strange to say, never in the United Kingdom, and only once in the colonies—namely, by Pockley (16). In his case the tumour was dissected from the sheath of the optic nerve. The neuritis which had existed previously disappeared, and vision was restored to $\frac{5}{12}$.

An admirable and complete monograph on this operation was published by Domela-Nieuwenhaus (2) in 1900. As his paper appeared in a work on general surgery, I hope I may be excused for treating the subject in some detail here.

Even the very limited experience of one operation has

Digitized by Google

been sufficient to convince me of its superiority over the usual methods of procedure, and will encourage me to adopt it in future should the necessity arise. This operation is by no means difficult, and it possesses many advantages.

The surgeon can see and explore the condition of affairs in the orbit before interfering with its contents, and can then decide how he will proceed, and whether it is advisable to preserve the eye or not. If he decides to retain it, he can do so with confidence in the result. The eyeball is not subjected to any rough handling or separated from its connections to the extent which is necessary in Knapp's operation; consequently, its nutrition is scarcely interfered with. The recovery of the cornea in my case, although it had commenced to suppurate and was at the same time anæsthetic, is a striking proof of the accuracy of this statement. Further, it may be added, the conjunctival sac is not opened, and the risk of infection from this source is avoided.

The operation as performed in this case differed in a few minor details from the description given by Knapp in Norris and Oliver's text-book. A probe was not passed into the spheno-maxillary fissure as a guide. The external rectus was not divided, but pushed upwards with the periosteum, which was divided below it. Periosteal sutures and a drainage-tube were omitted. That these precautions are unnecessary, as a rule, is shown by the fact that healing occurred by first intention, and the orbital margin was left absolutely free from deformity. Finally, the lids were sutured together to protect the cornea.

There are a few important points in the *technique* of the operation which I would like to refer to. In the first place, the wedge of bone removed should be as large as possible, and therefore the orbital margin should be divided close to the bases of the two processes which unite to form it,—that is to say, above the fronto-malar suture, and close to the zygoma below. If the height of the orbit be 35 mm., the base of the bony wedge should be about 33 mm. Further, the oblique incision should

Digitized by Google

pass as far backwards as possible and meet the sphenomaxillary fissure some distance from its anterior extremity. Nieuwenhaus recommends the passage of the elevator or a blunt probe 1 cm. backwards along the fissure as a guide to the direction of this incision, which should never be made last, otherwise the thin lamina of bone, not having sufficient support, will splinter under the chisel. It is advisable to use a small chisel (one 5 mm. broad was employed in my case). It is better to have an edge ground on one of the sides, and the sharp angle thus formed should be chiefly used. The strokes of the mallet must be short and rapid. A circular electric saw was used by Krönlein in one of his operations for the horizontal bony incisions with success. I tried a small cranial saw, but did not find it as easy to work as the chisel.

The operation in all cases has been essentially the same, but some minor modifications have been suggested. For instance, Parinaud and Roche (2) have recently adopted a different incision, for the purpose of hiding the scar as much as possible. They make a rectangular incision which allows the flap to be raised from behind forwards. It consists of a vertical incision in the hairy scalp in the temporal region, and two others starting from its extremities and running horizontally forwards, the lower one along the zygoma, and the upper ending in the eyebrow.*

A useful addition to the ordinary method of making the flap consists in making a further incision along the upper or lower margin of the orbit, as the case may be.

Again, with the object of enlarging the space afforded by Krönlein's operation, Czermak (35) proposed to remove the malar bone as well, but he never performed it on the living. Recently, however, Gangolphe (15) resected the malar bone, which he calls the external orbital tripod, in order to reach the cavity of the orbit. Rollet (13) also performed this operation in a remarkable case, which is worth

* It is not necessary to describe here the attempts or proposals which have been made to gain access to the orbit by resection of the inner or upper orbital walls. They are suitable only for very special cases.

Digitized by Google

mentioning. The patient suffered from exophthalmos accompanied by severe pain. Internal treatment failed to give relief, but the operation cured him completely, although a minute examination revealed nothing abnormal in the orbit. The cure was attributed by the author to the relief of increased intra-orbital tension due to some obscure cause, possibly the action of toxins.

I now come to the main point of this subject—namely, the results afforded by this operation, and the indications for its use. As regards the results, I shall not trouble you with statistics further than to mention the fact that only one death has occurred up to the present out of some seventy cases in which the operation has been performed, the fatal result in this case being due to the intracranial growth of the tumour, symptoms of which had existed before the performance of the operation. The progress of the patients has been good in all cases, except in two, in which slight suppuration occurred. The danger to life, therefore, is practically *nil*.

The scar in the temporal region is non-adherent and not very noticeable, and the orbital margin is free from deformity. The eye is normal in size and appearance, and in good position. Slight enophthalmos has been noticed in a few cases, which was disappearing while the patient was under observation. The ptosis and defective mobility of the eye, which generally occur immediately after the operation, gradually diminish. The upper eyelid regains its normal position and mobility in a large majority of the cases, while the ocular movements are fully, or almost fully, restored in two-thirds of the cases. Loss of power in the external rectus, which exists in most cases, even when the muscle has not been divided, is the only muscular lesion directly connected with this method of operating, and it is probably due to exudation or to adhesions at the outer part of the orbit. The most of the damage to the muscles occurs in removing growths at the apex of the orbit, where the former arise, but some of it may also be brought about by the

Digitized by Google

tumour previous to operation. The cornea becomes quite clear and regains its sensibility. Rarely, a faint nebula persists. In cases of partial anæsthesia, it is the outer portion which is affected. Vision, except in cases in which it was necessary to divide the optic nerve, was either saved or improved; most frequently the latter.

Indications for Krönlein's operation.—This operation is specially suitable for retro-bulbar affections in which retention of the eyeball is not contra-indicated. The various affections for which it has been performed, according to Nieuwenhaus, may be briefly summed up as follows:—(1) Cysts and tumours of all kinds; (2) injuries and foreign bodies; (3) retro-bulbar abscesses; (4) pulsating exophthalmos. He also states that it has been proposed for Graves's disease, posterior sclerotomy, tapping the sheath of the optic nerve, and, finally, for diagnostic purposes.

Since Niewenhaus published his paper I find that the optic nerve-sheath has been opened with good result by Foster (4), and Rohmer (25) has tried to remove the ciliary ganglion for absolute glaucoma by this method.

It must, I think, be admitted that the operation is justifiable in most of the conditions mentioned, and that in the remainder it facilitates considerably the access to the structures which it is desired to reach, whatever the opinion may be as to the efficacy of operative interference in the particular diseases. Tumours at the inner side of the orbit are of course more difficult to reach, but unless they are near the surface Krönlein's operation still maintains its superiority.

There are, however, some conditions in which the advisability of opening up the temporal fossa and producing a solution of continuity in the bone is at least doubtful—for instance, in diffuse infiltrating growths and in orbital cellulitis. The danger to the sight is so great, however, in the latter case, that, if the usual deep incisions do not give speedy relief, this operation should be undertaken. A drainage-tube should of course be inserted in these cases, and the bone should be replaced only partially at first.

Digitized by Google

Primary Tumours of the Optic Nerve.

In a paper published in 1895, Finlay (36) collected 117 cases of tumour of the optic nerve, but 15 at least of these were not primary. Again, in 1901 Byers (1), in an excellent monograph, tabulated 102 cases of primary intra-dural tumours and gave references to 32 others, which were also primary growths, but either extra-dural or doubtful as regards their exact point of origin in the nerve. As well as I could ascertain, 22 cases have been recorded since, making a total of 156.

In spite of this, tumours of the optic nerve are extremely rare in any individual clinique. Two in 388,000, according to Treacher Collins and C. Devereux Marshall (37), represented the ratio to other eye diseases in Moorfields. Bullar, of Montreal, saw 3 in 50,000. In the National Eye and Ear Infirmary, Dublin, the proportion is 2 in 46,000.

As regards the *age* of the patients, I find that in 117 cases 99, or 84 per cent., occur in the first twenty years of life.

With reference to *sex*, there were 67 females to 46 males in a total of 113 cases, or 59 per cent. of the former to 40 per cent. of the latter, showing a distinct preponderance of females.

In 111 cases the left eye was affected 57 times and the right 54.

The *signs and symptoms* of optic nerve tumours are so well-known that it is unnecessary to deal with them here. I shall refer to one only—namely, the direction of the displacement of the eye.

In two of the cases which I saw the proptosis was associated with a slight downward deviation. There is no note of the direction of the proptosis in the other.

According to Byers (1), in 58 per cent. of the cases the exophthalmos coincided more or less closely with the line of the axis of the orbit. In arriving at this conclusion he excluded, as exceptions to the rule, all those cases in which there was a displacement upwards, inwards, or

Digitized by Google

directly downwards. On adding the recent cases, in which the direction is stated, to those collected by him, I find that a downward displacement occurs in 36 out of 72, = 50 per cent.

It is probable that in the early stage of the disease the displacement is forwards and outwards, but when the patients come under observation an additional downward displacement frequently exists. This is probably due to the weight of the globe. That it should have been present in the second case recorded in this paper is surprising, considering that the tumour projected altogether below the nerve. I would therefore only exclude as exceptional, cases with any deviation inwards or upwards. According to this view the exceptions amounted to 20 out of 72, = 27 per cent.

No particular attention has been paid to the relation between the direction of the proptosis and the position and shape of the tumour, and herein lies, I think, the explanation of the exceptional cases. The optic nerve sometimes increases considerably in length, and in doing so one or more S-shaped curves are formed. A bend in the nerve close to the eye would tend to cause a deviation of the eyeball in a direction opposite to the convexity of the curve. This, I noticed, took place in one of the recorded cases. Again, if the tumour be very eccentrically situated on the nerve, the deviation of the eye will be altered accordingly.

The diagnosis, as a rule, presents no difficulties, except as regards the distinction between intra- and extra-dural growths; and, with Krönlein's operation in view, this is hardly necessary, unless for the purpose of giving an opinion as to the possibility of retention of sight, for by this method the diagnosis can be made with certainty at the time of the operation before the contents of the orbit have been disturbed.

The *microscopical structure* of primary tumours of the optic nerve is a subject of very great interest. These tumours have been described under a great many names,

Digitized by Google

the particular name given in each case depending partly on the view which the observer took as to its point of origin, which in many cases is doubtful. Hence, considerable differences of opinion arise, which are intensified by the fact that the structure often varies in different parts of the same tumour. A recent example of the difficulty experienced in these cases is afforded in a paper by A. Pagenstecher (23), who described three cases, but only ventured, even after a minute and careful examination, to name one.

The terms most commonly employed in this connection are sarcoma, myxoma, fibroma, simply or in combination; glioma comes next in frequency, and psammoma but rarely, while endothelioma has appeared in later years.* The most recent investigations, however, tend to show that they can all be reduced to two, or at most three generic terms, the largest group, sarcoma, fibroma, myxoma, etc., consisting of connective-tissue tumours in different phases of development. This view is taken by Collins and Marshall in a communication made before the Society in 1900. A careful study of six tumours led them to believe that they were "all primary growths of the connective-tissue framework of the optic nerve." Byers takes the same view, and uses the expression "fibromatosis" to denote the underlying condition in this group. Case 2 in this paper is a typical example of this form of tumour.

The second group is formed by the endotheliomata, which spring from the endothelial lining of the intervaginal space, or of the blood-vessels or lymphatics. Psammomata are either endotheliomata or connective-tissue growths, and are generally vascular.

The third section which has been shown was made from the tumour in Mr. Swanzy's case by Dr. Earl, who kindly gave it to me. It represents what most observers would

* No undoubted case of true neuroma has been recorded. A few cases of gumma and one of tubercle exist, but they do not belong to the class of new growths dealt with here. The earlier cases described as cancer are, of course, useless.

Digitized by Google

call a psammoma. But Leber (22) and Pagenstecher (23), who carefully examined this tumour, refuse to give it this name because they found that the laminated calcareous bodies which it contains are not formed from concentric layers of cells.

If all the cases can be included in the two groups just mentioned, then it may be truly said that tumours of the optic nerve are always mesoblastic in origin. A doubt, however, arises in connection with those which have been designated as gliomata. Modern histologists regard the neuroglia as an epiblastic structure, and gliomata consequently as epiblastic tumours. Some authors believe that there exists no indubitable proof that gliomata occur in the optic nerve. However, this is a question which remains to be determined. To complete this subject I shall merely mention the view put forward by Emmanuel (30), that tumours of the optic nerve are a local manifestation of the disease known as elephantiasis neuromatodes, a view which is rejected on very good grounds by A. Pagenstecher.

Treatment.—Removal of the tumour with enucleation of the eye has been the rule in these cases, and the majority of surgeons even still adhere to this practice. This ought not to be. There exists now, as we have seen, sufficient proof that the eye can be retained in its normal shape and appearance without interfering with the efficiency of the operation or increasing the risk of a recurrence of the growth. This statement applies specially to tumours of the optic nerve, which are always encapsuled and separated from the eyeball by a small portion of normal, or nearly normal, nerve. Out of the large number of cases recorded, only two showed any sign of extension into the eye, and in no case did recurrence take place in the eyeball when it was retained.

The only question, therefore, to be considered is, which operation affords the best prospects of retaining the eye in a normal condition as regards its position, appearance, and mobility? The method of operating from the front,

Digitized by Google

as performed by Knapp (39), and (with some additions to the *technique*) by Lagrange (40), has been recently brought into prominence by Schlodtmann (48), who advocates it in preference to Krönlein's operation, which he would reserve for those cases in which vision was still retained and the tumour difficult to reach. His objections to Krönlein's operation are, however, trifling, and the reservation which he makes is in favour of its superiority.*

The advantages of the latter have already been referred to, and need not be repeated. It only remains to compare the results obtained by the two methods. They may be briefly stated as follows:

	Knapp. Per cent.	Krönlein. Per cent.
Eye normal in shape and position	50	100
Position normal . . .	50	74
Upper lid normal . . .	50	80
Mobility normal, or only slightly defective	30	60

This comparison provides a further argument in favour of Krönlein's operation. The only reasonable grounds for rejecting it are, that it appears to be a more serious operation than the other, and that it leaves a scar. But the results show that it is devoid of complications or danger, and that the scar, which is not disfiguring, does not counterbalance the much greater security which it gives for the preservation of the eye in the best condition possible under the circumstances.

I have had the opportunity of comparing the two operations as far as their performance is concerned, as I assisted Mr. Swanzy in the removal of the tumour in his case by Knapp's method; and I much prefer Krönlein's operation.

For every reason, therefore, I feel justified in concluding that tumours of the optic nerve should be dealt with by Krönlein's method.

* The most successful cases of Knapp's operation, as regards preservation of the eye, are the three of von Hippel related by Schlodtmann. In these the tumour was removed from the inner side.

Digitized by Google

Prognosis.—The statements made as to the prognosis in these cases vary very considerably. This is not surprising, in view of the facts mentioned below, which make it impossible to dispose of the matter briefly.

Byers concluded that "the outlook in general is to be regarded as extremely grave," and that "the danger is not from a recurrence in the strict sense of the term, but from the continued development of the intra-cranial portion of the tumour which it is impossible to remove at the time of the operation." He bases his opinion on the results of ten *post-mortem* examinations, in only two of which the disease was confined to the orbit; and also on the fact that only eight cases were known to be in good health beyond five years.

I have looked up the results in 121 cases, and for the sake of clearness have divided them into five groups:—

1. Patients (*a*) *alive* and *well* when last seen:	
Time not stated	30
Under 1 year	29
1 year	14
2 years	5
3 „	7
4 „	1
5 „	1
6 „	2
11 „	2
15 „	1
25 „	1
Total	93
(*b*) Living, but with symptoms of *intra-cranial complications.* (One of these was known to be alive after 8 years. The remainder were not under observation longer than 1 year)	7
(*c*) Living, but with *local recurrence* only	2
2. Deaths:	
(*a*) From *meningitis after operation*	12
(*b*) From *intra-cranial complications* (one 10 years, one 2½ years, the others not more than 1 year after operation)	7
Gross total	121

Digitized by Google

Fourteen *post-mortem* examinations * revealed intra-cranial growths in twelve cases. In nine the condition was present with certainty at the time of the primary operation, death having taken place within a fortnight after it from meningitis. Local recurrence was noted, in addition to the cases mentioned above, in six of the others. Two at least of the latter died of meningitis after operation. Some were associated with intra-cranial complications.

As regards meningitis, it has been remarked that most cases occurred previous to the adoption of aseptic methods. This is true, but three of the cases occurred since 1894.

Evidence of intra-cranial complications existed in twenty-four cases—Groups 1 (*b*), 2 (*b*), and in ten *post-mortem* examinations after meningitis. This is a very large proportion, 19 per cent. These results prove that the danger to life is very considerable. On the other hand, the facts pointing in a more favourable direction should not be lost sight of.

Post-mortem examination in two cases revealed no trace of intra-cranial growth; in some they were small and confined to the intra-cranial part of the nerve, and did not cause any symptoms. Moreover their existence was not incompatible with a possible prolongation of life for many years, as the growth of these tumours is in many cases extremely slow. Cerebral symptoms, epilepsy, idiocy, were improved by operation in three cases. In spite of incomplete removal in a great many cases, local recurrences have not taken place. Twelve patients are known to have lived five years or more. Of these three died, one from cerebral complications in ten years (Byers), and two from meningitis, after operation for recurrence, at intervals of five and twenty-six years (Pagenstecher) respectively. One was alive, but with cerebral symptoms, after eight years. The others lived 6, 11, 15, and 25 years. Unfortunately for statistics, in

* One case in which an autopsy was obtained and no intra-cranial growth found is not included in the above list. No operation was performed, and the patient (a girl) died of pulmonary tuberculosis at nineteen years of age. The orbital tumour developed in early childhood.

Digitized by Google

the majority of the cases the subsequent history is either unknown or has been followed for too short a time. However, I think the following conclusions are warranted by the facts:

(1) A perfect cure can be effected in some cases.

(2) Local are less frequent than intra-cranial recurrences, but may occur after a very long interval of years.

(3) Meningitis after operation will occur in a very small percentage of cases.

(4) Intra-cranial complications constitute the chief danger, and are found in a much larger number of cases than are local recurrences; and since the existence of these growths within the cranium cannot be made out, except in a late stage, and seeing that they may occur or develop at any time, it is impossible to say, in any given case, when the patient is out of danger.

In conclusion, I wish to say that this paper has reached a much greater length than I had originally intended, but the interest of the subject, and the fact that little or no attention has been paid to Krönlein's operation in this country, will, I hope, be a sufficient excuse. I have added a table of the twenty-one cases of tumour of the optic nerve in which Krönlein's operation has been performed.

Bibliography.

I. *The two undermentioned works contain complete lists of references to papers on tumours of the optic nerve and Krönlein's operation respectively, which had appeared up to the date of their publication.*

(1) Byers.—The Primary Intra-dural Tumours of the Optic Nerve, Fibromatosis Nervi Optici, *Studies from the Royal Victoria Hospital, Montreal,* vol. i, No. 1, August, 1901.

(2) Domela-Nieuwenhaus.—Ueber die retrobulbäre Chirurgie der Orbita, *Beiträge zur klinischen Chirurgie,* 1900, Hefte 2, 3, July, 1900.

Digitized by Google

II. *Papers of later date than the above.*

(3) KNAPP, A. H.—A Case of Orbital Cavernoma, removed by Krönlein's method, with Preservation of the Eyeball, *Archiv. of Ophthalm.*, vol. xxix, pt. 2, p. 141.

(4) FOSTER.—Distension of the Sheath of the Optic Nerve with Cerebro-spinal Fluid; Osteoplastic Resection of the Outer Wall of the Orbit (Krönlein's operation), *Archiv. of Ophthalm.*, vol. xxix, p. 397.

(5) VALUDE.—Des Opérations sur l'Orbite par la Voie temporale, *Annal. d'Oculist.*, cxxiv, p. 114, 1900.

(6) CHAILLOUS.—*L'Opération de Krönlein dans les Affections de l'Orbite*, Paris, 1900.

(7) RAFF.—*Thèse de Bucharest*, 1899. (*Quoted by* Chaillous.)

(8) JONNESCO.—Extirpation des Tumeurs du Nerf optique avec Conservation du Globe de l'Œil, par la Résection temporaire de la Paroi orbitaire externe, XIIIe Congrès Internat. de Méd., Paris, 1900, *Annal. d'Oculist.*, cxxiv, p. 175. (*See also* Chaillous.)

(9) CHEVALLERAU and CHAILLOUS.—XVIII Sess. ann. de la Soc. Franç. d'Ophtalm., *Annal. d'Oculist.*, cxxvii, p. 76, 1901.

(10) PARINAUD and ROCHE.—Angiofibrome de l'Orbite, Modification du procédé de Krönlein, *Annal. d'Oculist.*, cxxvi, p. 241, 1901.

(11) MORESTIN.—Two Cases of Extensive Epithelioma of the Face and Orbit operated on by Krönlein's method, XVIe Congrès Franç de Chirurgie, October, 1901.

(12) STEPHAN.—Ein Beitrag zur Erkenntniss der Orbitalen Echinococcen und der Krönlein'schen Operation, *Inaug. Dissert. Rostock*, 1901.

(13) ROLLET.—Exophtalmie guérie par Orbitotomie Malaire, *Annal. d'Oculist.*, cxxvi, p. 370, 1901.

(14) QUÉNU.—Extirpation d'une Tumeur orbitaire par la Résection temporaire de la Paroi externe de l'Orbite, *Soc. de Chirurg. de Paris*, 1900.

Digitized by Google

(15) GANGOLPHE.—De la Résection du Trépied Orbitaire externe dans la Chirurgie de l'Orbite et de la Face, *Congrès Franç. de Chirurgie*, October, 1901.

(16) POCKLEY.—A Case of Primary Neoplasm of the Optic Nerve Sheath removed by Krönlein's Operation, with Preservation of the Eye and Good Vision, *Austral. Med. Gazette*, October, 1901, p. 11; and *Archiv. of Oph.*, vol. xxxi, p. 114.

(17) VON AXENFELD.—Orbital Platten zur Krönlein-'schen Operation, *Bericht der Oph. Gesellsch. Heidelberg*, 1901, p. 235.

(18) PAYNE.—A Case of Primary Glioma of the Optic Nerve, *Med. Record*, January, 1901.

(19) BIETTI.—Un Cas d'Endothéliome des Gaines du Nerf optique, *Annal. di Ottalm.*, vol. xxx, fasc. 4, 1901; *Revue Générale*, 1901, p. 555.

(20) TSCHEMOLOSSOW.—Retro-bulbar Tumour, Ophthal. Soc. St. Petersburg, November, 1901, *Annal. d'Ocul.*, 1902, p. 387.

(21) RUSCHHAUPT.—Ueber ein myxomatös entartetes Gliom des Nerves opticus, *Inaug. Dissert. Bonn*, 1900.

(22) LEBER.—*Bericht der Ophtalm. Gesellsch. Heidelberg*, 1901, p. 223.

(23) PAGENSTECHER, A.—Ueber Opticus Tumoren, von Graefe's *Archiv f. Oph.*, Bd. liv, p. 300, 1902.

(24) KNAPP, A.—A Case of Tumour (Endothelioma) of the Orbit, *Trans. Oph. Sect. N. York. Acad. Med.*, February, 1902. (Also *Archiv. of Oph.* xxxi, p. 209.)

(25) ROHMER.—De l'Extirpation du Ganglion ciliaire, *Annal. d'Oculist.*, vol. cxxviii, p. 1, 1902.

(26) TOBIAS.—Ein Beitrag zur Kenntniss der Thränendrüsentumoren und ihrer Operation nach der Krönlein-'schen Methode, *Inaug. Dissert. Freiburg*, 1902.

(27) ISRAEL.—Operation eines Orbital Sarcoms mit Erhaltung des Auges, *Centralbl. f. Augenheilk.*, 1902, p. 108. (Modified Krönlein skin incision.)

(28) FRANKE.—Zur Diagnose und Behandlung retrobulbärer Erkrankungen, *Oph. Gesellsch. Heidelberg*, 1902.

Digitized by Google

(29) Swanzy and Earl.—Psammoma of the Optic Nerve, Royal Acad. Med. Ireland, January, 1901. (Also *Brit. Med. Journ.*, 1901, and Pagenstecher, No. 23 above.)

(30) Emmanuel.—Ueber die Beziehung der Sehnervengeschwülste zur Elephantiasis neuromatodes, von Graefe's *Archiv f. Oph.*, Bd. liii, 1. (Also *Oph. Gesellsch. Heidelberg*, 1901.)

(31) Delens.—Note on Extirpation of the Ciliary Ganglion, *Bull. de la Soc. de Chirurg. de Paris*, April, 1902.

III. *Other papers referred to.*

(32) Krönlein.—*Beiträge zur klin. Chirurg.*, Bd. iv, 1889.

(33) Braunschweig.—Von Graefe's *Archiv f. Oph.*, xxxix, Abth. 4, p. 1.

(34) Norris and Oliver.—*System of Diseases of the Eye*, vol. iii, p. 918,

(35) Czermak.—*Die augenärztlichen Operationen*, 1894.

(36) Finlay.—*Archiv. of Oph.*, xxiv, p. 224.

(37) Collins and Marshall.—*Trans. Oph. Soc. U. K.*, vol. xx, p. 156.

(38) Buller.—*Trans. Amer. Oph. Soc.*, 1899, p. 510, and *Canada Med. and Surg. Journ.*, 1886.

(39) Knapp.—*Klin. Monatsbl. f. Augenh.*, Bd. xii, S. 439; and *Archiv f. Augenheilk.*, 1874. (Also *Trans. Amer. Oph. Soc.*, 1879, p. 557.)

(40) Lagrange.—*Études sur les Tumeurs de l'Œil*, Paris, 1893, p. 217; and *Annal. d'Oculist.*, 1892, cvii, p. 377.

(41) Schreiber.—*See* Bullinger, *Beitrag z. klin. Chirurg.*, Bd. xix, p. 533; and Domela-Nieuwenhaus, *loc. cit.*, p. 676.

(42) Axenfeld and Busch.—*Archiv f. Augenheilk.*, Bd. xxxix, p. 1.

(43) Ellinger.—*Zeitschr. f. Augenheilk.*, i, p. 48.

(44) Mayweg.—*Die Oph. Klin.*, Bd. iii, No. 6, S. 90; and *Clin. Oph.*, vi, p. 68, 1899.

Digitized by Google

(45) GOLOWIN.—*Westnik. Oftal.*, 1899; and *D.-Nieuwenhaus*, pp. 669 (Case 1), 684 (Case 2), and 685 (Case 3).

(46) MADELUNG.—*D.-Nieuwenhaus*, p. 685.

(47) VALUDE.—*Annal. d'Oculist.*, cxxii, p. 63.

(48) SCHLODTMANN.—*Beiträge zur Augenheilk.*, A. von Hippel's *Festschrift*, 1899, Halle.

Digitized by Google

Primary tumours of the optic nerve removed by Krönlein's operation, with preservation of the eye.

No.	Author and year of publication.	Age, sex, right or left eye.	History.	Condition before operation.	Nature of tumour (microscope).	Result.
1	Braunschweig, 1893	1½ M. L.	Rapidly developing proptosis towards end of first year of life	Exophthalmos forwards, down, and outwards; limitation of movement, especially vertically; post-neuritic atrophy; hypermetropia; symptoms of intracranial growth	Myxosarcoma	Death four weeks after operation, apparently from intracranial tumour eye.
2	Braunschweig, 1893	24 M. L.	Proptosis and failure of vision for one and a half years	Exophthalmos forwards, outwards, and downwards; optic neuritis; V. very defective; limitation of movement except inwards	Myxosarcoma	Four years later eyeball well preserved; slight divergence.
3	Schreiber, 1897 or 1898 (?)	4 M. R.	Exophthalmos for one year	Exophthalmos; good mobility; optic neuritis; no palpable tumour	Myxosarcoma	Six days later eye normal but convergent.
4	Axenfeld and Bush, 1899	11 F. R.	Periodical attacks of headache, accompanied by sensations of heat and cold, and vomiting, for six to eight months; onset of proptosis with headache	Proptosis varied in degree; once increasing with pyrexia and swelling behind angle of jaw; again with pain in eye and vomiting; optic neuritis; sudden reduction of vision; no palpable tumour; movements free	Myxosarcoma	Nine months later eye well preserved; limitation of movement, inwards chiefly; cornea clear; sensation only in lower outer quadrant.

Digitized by Google

5	Ellinger, I, 1899	10 F. L.	Internal strabismus and proptosis of two years' duration	Exophthalmos forwards and almost imperceptibly downwards and outwards; mobility free except upwards; optic atrophy; H. + 10 at papilla, − 2 at periphery; tumour palpable	Myxosarcoma	Three months later slightly diminished enophthalmos; free mobility in all directions, except slightly defective downwards; cornea clear; sensation normal.
6	Ellinger, II, 1900	20 F. R.	Internal strabismus and proptosis at age of 4	Exophthalmos forwards, upwards, and inwards; vertical movements chiefly diminished; optic atrophy; palpable tumour	Myxosarcoma	Ten months later slight enophthalmos; free movement in all directions; slight superficial cloudiness of cornea below; sensation normal.
7	Mayweg, 1899	5 F. ?	?	Exophthalmos	Myxosarcoma	Fourteen days later strabismus convergens, but no exophthalmos.
8	Golowin, I, 1899	4 M. R.	Onset of proptosis one month after a fall on forehead ten months previously	Exophthalmos forwards and slightly downwards; mobility good, except out and also down; optic neuritis; palpable tumour	Myxomatous fibro-sarcoma	Five and a half months later still some enophthalmos and ptosis; mobility increasing, but least upwards and outwards; eye well preserved; cornea clear.
9	Golowin, II, 1899	40 F. R.	Exophthalmos began fourteen years previously	Exophthalmos forwards and somewhat downwards and outwards; movements limited in all directions; optic neuritis; no palpable tumour	Endothelioma	Patient left quite well after ten days' complete ptosis and immobility of eye, which is well preserved.
10	Golowin, III, 1899	40 M. R.	Proptosis began five years previously, with defect of V.	Exophthalmos forwards so great that forcible closure of eyelids caused luxation of globe; mobility slightly restricted in all directions; optic atrophy; palpable tumour	?	Suppuration of orbit and corneal ulcer after operation; recovery complete; eye well preserved; mobility lost outwards only.
11	Madelung, 1900	18 M. R.	V. lost fourteen days after an injury to orbit one month previously; proptosis noticed shortly afterwards	Exophthalmos forwards and very slightly outwards; movements slightly limited upwards and inwards; pupilla hyperæmic; veins engorged; no palpable tumour	Myxosarcoma	One month later ptosis; very slight proptosis; convergent strabismus; mobility lost upwards and also outwards; slight transverse nebula of cornea.

Digitized by Google

No.	Author and year of publication.	Age, sex, right or left eye.	History.	Condition before operation.	Nature of tumour (microscope).	Result.
12	Valude, 1900	4 M. R.	Proptosis of seven months' duration	Exophthalmos; optic neuritis; no palpable tumour	Sarcoma probably growing from sheath of nerve (cells fusiform)	The muscles were removed with the tumour; nine months later slight enophthalmos, diminishing ptosis; eye well preserved, but immovable; cornea transparent, though anæsthetic; conjunctiva anæsthetic.
13	Jonnesco, I, 1899	15 F. R.	Great proptosis of eight years' duration, beginning after a fever, with loss of V.	Exophthalmos; V. = 0	Fibroma with colloid degeneration	Eye perfectly preserved two years later, and in good position.
14	Jonnesco, II, 1900	4½ F. R.	Proptosis for one year, coming on after typhoid	Exophthalmos; good mobility; optic neuritis; V. = 0; sensation of hardness on palpation	Tumour of nerve.	
15	Jonnesco, 1900	5 F. R.	Proptosis of one year's duration	Exophthalmos; loss of V.	Myxoma	Five months later, eye well preserved.
16	Chevallereau and Chaillous, 1900	15 M. L.	Proptosis of two years' duration; failure of vision three years	Exophthalmos; mobility of eye intact; feeling of fluctuation on palpation; V. = 0	Psammoma	Six weeks later, upper lid freely movable; mobility of eye downwards and inwards good, defective in other directions; cornea anæsthetic; small healed ulcer.
17	Chevallereau, 1901	5 F.	Two years' duration	—	Fibro-myxoma of internal sheath.	
18	Pockley, 1901	13 M. L.	Exophthalmos six to eight months' duration	Eye displaced forwards; moderate neuritis; no diplopia; V. = $\frac{5}{12}$; distinct feeling of resistance	Glio sarcoma (aberrant round-celled sarcoma)	Tumour grew on outer surface of optic nerve sheath and was dissected off; seventeen days later, eye normal; mobility perfect; diplopia only to extreme left; V. = $\frac{5}{12}$; neuritis subsided.

Digitized by Google

19	A. Knapp, 1902	27 F. L.	Proptosis for one and a half years	Exophthalmos forwards; mobility slight in all directions; optic neuritis; V. = $\frac{1}{100}$; no palpable tumour	Endothelioma springing from optic nerve sheath	Tumour easily separated, except when attached to nerve; capsule ruptured; soft tumour masses evacuated; suppuration; bony wedge subsequently replaced; three months later, no exophthalmos, but eye adducted; no motion vertically; optic disc discoloured; V. = $\frac{5}{100}$.
20	Pagenstecher, 1902	5 M. L.	Proptosis of six or seven months' duration	Exophthalmos forwards and upwards; good mobility in all directions; optic neuritis; V. = 3; fingers at 4 mm.; no palpable tumour	Sarcoma (author could not decide whether it was a glioma or endothelioma)	Five months later, slight prominence of eye, very slight ptosis; cornea anæsthetic; horizontal nebula; some degree of vertical movement.
21	Werner, 1902	45 F. L.	Proptosis began twelve months previously	Exophthalmos forwards and slightly outwards and downwards; freedom of movement considerable in all directions; optic atrophy; no palpable tumour	Alveolar sarcoma with concentric grouping of cells (endothelioma?)	Seven months after operation, complete ptosis; very slight enophthalmos; slight divergence; T. n.; cornea clear but anæsthetic; lower bulbar conjunctiva also anæsthetic; mobility in vertical plane good; trace of outward motion, none inwards.

Numbers 1, 2, 4, 5, and 8 are included in Byers' table of cases of primary intra-dural growths. Numbers 6, 10, and 11 were published for the first time in D. Nieuwenhaus's paper on Krönlein's operation. Golowin's first case is classed by Nieuwenhaus as an extra-dural tumour of the nerve sheath, while Byers places it, correctly I think, amongst intra-dural growths. Numbers 14 and 16 were published for the first time by Chaillous. Another case of Valude's is placed with tumours of the optic nerve sheath by D. Nieuwenhaus, but the details as given by him do not agree with the original in the *Annal. d'Oc.*, vol. cxxiv, p. 114. The references belonging to the other cases are given in the bibliography. It seems to be a case of cavernous angioma surrounding the nerve, but it is not clear where it arose.

Digitized by Google

The CHAIRMAN (Mr. W. LANG) said he had not had any personal experience of the operation.

Mr. J. B. LAWFORD thought Krönlein's operation had been performed several times in the United Kingdom. Personally, he had done the operation once.

Mr. SYDNEY STEPHENSON had performed Krönlein's operation once in a case of endothelioma originating from the ethmoidal and sphenoidal sinuses.

The CHAIRMAN said that probably the cases which had been referred to would be published later. No doubt it was still early to pronounce a definite opinion about the operation, or to say whether the operation could be done in all cases without the likelihood of a recurrence.

Mr. L. WERNER, in reply, said he of course referred to cases which had been reported, as he had no other means of finding out whether, or how often, the operation had been performed in the United Kingdom. He had ascertained that Krönlein's operation had been done in twenty-one cases of tumour of the optic nerve, and with success in every case, as far as preservation of the eye was concerned. It was early yet to speak of the question of recurrence. Inasmuch as one recurrence took place twenty-six years after the original operation, one could never know when the danger of recurrence was passed. At any rate, he saw no reason why Krönlein's operation should hasten recurrence.

---

2. *A case of family optic neuritis (Leber's disease) in which perfect recovery of sight took place.*

By E. NETTLESHIP.

I RECORD this case because it is, I believe, very unusual for even partial recovery, still more complete restoration of sight, to occur in this disease.

Digitized by Google

Mr. F—, æt. 28 years, a tutor, was sent by Dr. Price, of Carmarthen, in December, 1895. His sight had been perfect till the previous June, when it failed, got to its worst in four or five weeks, and remained stationary from then. The left began to fail before the right. Within a few weeks of the commencement, he was advised to give up smoking, and did so absolutely, but without benefit to the sight. When I saw him V. was $\frac{6}{60}$ with each eye, and with both together he could read 16 J. There was a large, central, horizontal scotoma for green in the left, and a still larger one in the right, the 10 mm. green spot being recognised in this eye in the lower part of the field only. The scotoma could not be found with any certainty by using a red spot, the perception of red being relatively much better than that of green, or of black and white. The O. D.s were sharply defined and rather pale on the temporal side, and the retinal arteries perhaps too small. The retina skirting the Y. S. above and below was extremely streaky, especially so below, almost amounting to opaque nerve-fibres; but as the choroids were very dark, I attached no importance to this retinal appearance. Health good. Knee-jerks very brisk.

At the date of my examination, the patient knew of two similar cases in the family. The sufferers, themselves brothers, were his first cousins, sons of his mother's sister; both were heavy smokers, and had drunk too much. One, a shopman, was between twenty-five and thirty when his sight failed; he had to give up business, and his sight never improved. The other, a small farmer, was thirty-five when his sight failed; he remained bad for two years, and then, it was said, recovered his sight completely. Recognising my patient's case as one of Leber's family axial neuritis, I told him he was not likely either to recover his sight or to get worse, and I saw no more of him. Last May (1902) Mr. R. W. Doyne wrote to ask about my patient, because his brother was then under care for the same kind of amblyopia, and Mr. Doyne had heard that my patient had recovered. In reply to inquiry, my

Digitized by Google

patient informed me that his vision began to improve in the spring of 1896, say nine months after it failed and three months after I saw him; that in a few months (December, 1896) it was good enough for him to read for ordination, and was, in fact, as good as ever; and that he had since been appointed head-master of a large school. I sent him a card of pocket test-types, and he marked the smallest, equivalent to Snellen's 0·3 or Jaeger's 1, as quite easily legible. He said he resumed smoking in 1897—say, within two years of the failure of sight—but to only about half his original quantity; he also mentioned that his brother, Mr. Doyne's patient, was a non-smoker.

Mr. Doyne has very kindly sent me his notes (quoted below) of the brother's case, from which it appears that, when he saw him, one eye was badly, the other only very slightly attacked.

"May 3rd, 1902.—Mr. C. J. F—, æt. 25 years, discovered defect of right eye a month ago; cannot now shoot, but could at Christmas. V. of R. now, fingers at 3 feet, of L. $\frac{6}{9}$. In the right there is a large central scotoma for red, the colour being scarcely recognised at all to the inner side. The scotoma is absolute at centre. There is in left eye distinct loss of depth of colour at centre, but not complete loss of perception of red. Pupils do not dilate very widely on shading, but react quite readily. Fundus really nothing abnormal; perhaps right disc is not very well-defined, but really nothing to notice. Knee-jerks present in both. Patient is very pale, and always has been so."

October 8th.—Mr. Doyne has not so far succeeded in ascertaining the progress of this case.

July 28th, 1903.—No further information procurable.

We have here, therefore, four cases in two pairs of brothers, the sons of two sisters, two of the four recovering completely.

(*Read October 16th*, 1902.)

Digitized by Google

The CHAIRMAN (Mr. W. ADAMS FROST) said he saw at St. George's Hospital early this year a typical case of Leber's atrophy, with a large central scotoma, in a man æt. 23 years. The patient stated that some four years previously his brother, then of the same age, had attended for the same condition and had completely recovered. Mr. Frost was able to verify the first part of this statement, but as to the second he had only the brother's statement. He had written to ask the man to come to see him, but he had not done so.

Mr. A. W. ORMOND said he knew of a case of partial recovery from Leber's atrophy, but it was somewhat complicated by a history of injury to the head. The case was in the brother of a patient who consulted him first, with typical Leber's atrophy, with a large scotoma in each eye, with defective colour-vision, pain, and ordinary eccentric fixation. He was not a heavy smoker. But the case of the brother, who said he suffered in the same way, was more interesting. He had a severe accident in March, 1899, being thrown from a train. He recovered from that accident, and afterwards was able to resume his work; he then, about two months afterwards, found his sight failing, and in about six months had to give up his work. For some time the sight continued so bad that he could not see more than shadows in front of him, and could not discern the faces of his children. Eventually, he improved, and was now in the same state as his brother, with the condition stationary. There was a large scotoma, but the peripheral vision was good. Both patients can read large print.

Mr. JOHNSON TAYLOR said that in vol. xii of the *Transactions* he recorded four cases of Leber's disease among six sons. In the youngest case a very considerable unilateral improvement took place, which seemed to follow an operation for mastoid disease which had to be done a few months after the onset of the eye affection on the side which improved. Whether that had any effect in the way of counter-irritation in hastening

Digitized by Google

recovery he could not say. He would like to know whether in Mr. Nettleship's case any treatment was adopted, or whether it was left to nature.

Mr. J. B. LAWFORD referred to a case of Leber's disease in which almost complete recovery of vision occurred in one eye. The patient was one of three brothers affected with this form of disease, and his case was included in a paper* read before this Society by Dr. Menteith Ogilvie. In December, 1895, the vision was, in R. $\frac{5}{60}$ and No. 16 J.; in L. $\frac{6}{24}$ and 14 J. In September, 1901, vision was, in R. $\frac{2}{60}$ and 20 J., and in L. $\frac{6}{18}$ and 1 J. with difficulty. In February, 1902, vision was, in R. $\frac{6}{36}$, and in L. $\frac{6}{6}$ almost entirely. The field of vision of the left eye was of full extent.

Mr. NETTLESHIP did not know whether his patient had received any treatment. He suggested that in the case mentioned by Mr. Ormond, where the symptoms came on some considerable time after a railway accident, the accident need not be considered.

---

3. *Retro-bulbar neuritis and peculiar appearance of retinal vessels.*

By WALTER H. JESSOP.

LEONARD S—, æt. 22 years, carpenter, was admitted into St. Bartholomew's Hospital on November 18th, 1902, complaining of loss of vision. He says his sight was perfect till four weeks ago, when he noticed on a Sunday he could not read his book. Since then he has been unable to do his work; the sight has gradually become a little worse.

Present history.—Always a healthy man, but rather nervous. No specific history; never rheumatism. Smokes two ounces of Honey-dew tobacco a week. No complaints of headaches.

* *Transactions*, vol. xvi, p. 118.

Digitized by Google

Family history.—Parents, two brothers, and sister healthy, and nothing the matter with their eyes. No history in family of Leber's disease.

Present condition.—Well-nourished man, healthy-looking. Dr. Ormerod examined him thoroughly and found nothing wrong with him. Urine 1016, acid, no albumen, no sugar. Blood examined, but nothing important found beyond slight leucocytosis; hæmoglobin, 85 per cent.

Both eyes.—Lids, conjunctivæ, and media healthy and normal.

V. { R. $\frac{1}{60}$, J. 20 at 30 mm. / L. $\frac{3}{60}$, J. 20 at 30 mm. } Retinoscopy — + ·5 / + ·5

Fields of vision taken.—Good size peripherally for white and red. Central scotoma for red in both eyes; right larger than left.

Ophthalmoscope.—In both eyes there is a curious condition of exaggerated retinal reflexes and contracted vessels above, below, and nasal side; the retina at temporal side between superior and inferior temporal vessels is apparently normal. This condition is probably congenital. *Right eye.*—Optic disc pale on temporal side, edges well-marked, no swelling; vessels look increased in number and are very tortuous, especially the arteries, which have broad light streak and apparently contain little blood; in places the small vessels look empty, and have almost a moniliform appearance. No actual hæmorrhages to be made out. *Left eye.*—Optic disc pinker than right and not so pale on temporal side. Vessels, etc., the same.

Treatment.—Pil. Hydrarg. c̄ Cretâ, gr. j, b. d.; strychnine; blisters.

December 10th.—The sight if anything has got worse. The ophthalmoscopic signs are a little more marked as to the exaggerated retinal reflexes and vessels. The right optic disc is distinctly paler and less transparent-looking.

(*Card specimen. December 11th*, 1902.)

Digitized by Google

4. *Partial atrophy of the optic nerves caused by lightning.*

By E. Treacher Collins.

John G—, æt. 49 years, one stormy night two years ago in South Africa, was knocked down by lightning. He does not think he was actually struck. He did not lose consciousness, but felt dazed afterwards, and vomited. He did not notice any defect of sight until the following morning, and then everything appeared to be in a mist in front of him. The sight gradually got worse until it reached its present condition. For some months after the injury he suffered from severe frontal headaches; they have now almost entirely gone. He smoked, until a month ago, an ounce of shag a week, and chewed tobacco while in South Africa when he could get it. He denies ever having had syphilis.

There is a constant spasmodic blinking of the lids of both eyes. The cornea and other media are clear. The pupils act to light and to accommodation. V. of each eye is equal to counting fingers at two feet. The field for white of the left cannot be taken; that of the right is entirely within the 30° circle. It was taken more than once, and each time came out practically the same. He cannot distinguish either red or green.

Ophthalmoscopical examination shows the outer half of each optic disc white and atropied; the inner halves are of good colour. The retinal vessels are normal in size, and there are no other fundus changes.

Dr. Mott has kindly examined him for me, and has pointed out that there is facial paresis, chiefly affecting the lower part of the face on the right side, that the tongue is protruded rather over to the right side, and that on the same side there is some deafness, due to nerve changes, as bone conduction is deficient. The larynx is normal;

Digitized by Google

knee-jerks slightly exaggerated ; no weakness of arms or legs ; muscle reaction on right side of face is weaker than on left.

Remarks.—The appearance of this man, with the constant twiching of his lids, suggests at first that he might possibly be malingering. The consistency of his statements and the decided pallor of his optic discs disproves this. The question also arises whether the condition might not be one of unusually severe tobacco amblyopia. The quantity of tobacco he smoked or chewed does not seem to have been excessive. The sudden onset of the failure of vision, its intensity, the presence of other nerve lesions, and the non-improvement of sight during the last month since he had abstained from tobacco, are all against such a supposition.

There seems, then, to be practically no doubt that the atrophy of his optic nerves and failure of vision are due to lightning. The number of recorded cases of eye injury due to lightning is not numerous. An examination of them seems to show that the symptoms which they present are attributable to one or more of three causes :

1. *The effects of the heat rays,* such as burns of the lids or conjunctiva.

2. *The effects of the chemical ultra-violet rays.*—Symptoms similar to those which are met with in cases of "snow blindness" or "ophthalmia electrica," *e. g.*, blepharospasm, conjunctival hyperæmia, spasm of the sphincter pupillæ, and erosions of the cornea.

3 *The effects of electrolytic action or concussion.*—Changes which can be reproduced in animals by shocks from Leyden jar batteries (Hess * and Kisibuchi †): paralysis of ocular muscles, opacities of lens, retinal hæmorrhages, detachment of retina, optic atrophy, and rupture of choroid.

Leber ‡ in 1883 collected eighteen cases with injury of

* *Bericht der VII internat. Ophth. Kongress,* Heidelberg, 1888.

† *Arch. für Ophthalmologie,* L, 1.

‡ *Arch. für Ophthalmologie,* xxviii, 3, p. 255.

Digitized by Google

the eye from lightning, nine with cataract. Rohmer,* writing in 1895, could find only six cases recorded in which the retina or the optic nerve had become affected by lightning. The only cases of injury from lightning recorded in the *Transactions* of this Society are two published by Major M. T. Yarr† in 1901, one with retinal hæmorrhages and the other with detachment of retina.

(*Card specimen. December 11th,* 1902.

The CHAIRMAN (Mr. William Lang) said, in reference to Mr. Collins's case, that a few months ago a lady was blinded by a flash of lightning, and when he saw her she had a little patch of choroiditis, probably the remains of a small hæmorrhage in the yellow spot region. The condition came on suddenly, and directly after a flash of lightning. Otherwise the patient was quite healthy.

---

5. *Primary extra-dural tumours of the optic nerve.*

By J. HERBERT PARSONS, B.S.

IN a recent publication‡ Dr. W. G. M. Byers has collected all the published cases of primary intra-dural tumours of the optic nerve. The object of the present paper is to do the same for the primary extra-dural tumours, a typical case having recently come under my notice. The following are the notes of this case :

Millicent M—, æt. 7 years, was admitted an outpatient to the Royal London Ophthalmic Hospital, under Mr. Arnold Lawson, on March 13th, 1902, suffering from proptosis of the L.

* *Archives d'Ophtal,* xv, p. 209.

† *Trans. Ophth. Soc.,* vol. xxi, p. 139.

‡ *Studies from the Royal Victoria Hospital, Montreal,* vol. i, No. 1, August, 1901.

Digitized by Google

Previous history.—Two months before Christmas, 1901, patient was playing with her father, when his finger accidentally touched her eye. Nothing was noticed until the following morning, when it was seen that the lid had "dropped." In February, 1902, the child was taken to the Children's Hospital, Great Ormond Street, because she was getting thin. After treatment there it was noticed that the L. projected somewhat, and that the lid still drooped. The child also had headaches, which were attributed to a "discharge which came from the left ear." For a day or two she had slight vomiting, attributed to a "bilious attack." The patient suffered from "night terrors."

Family history.—No consumption in the family. One other child alive. One other child died, æt. 5 months, of "inflammation of the base of the brain." The mother had one miscarriage after patient's birth.

Present condition.—March 13th, 1902.—L. ptosis. Exophthalmos directly forwards. Limitation of movements in all directions. Marked optic neuritis. V. = $\frac{6}{6}$. R. V. = $\frac{6}{6}$.

Progress, etc.—May 14th.—Admitted an in-patient under Mr. Lang. Condition has apparently not progressed much. Optic axes apparently parallel; no diplopia. There is an abnormal bony (?) prominence to be felt on the L. lower orbital margin near the inner angle. Marked ptosis and proptosis (= fully 1 cm.). Movements limited in all directions, especially vertically. Cornea and A. C. normal. Atropine mydriasis. Lens clear. Edges of disc blurred and radially striated. Swelling = + 6 D.; ? a minute hæmorrhage on disc. There is some exudation along the vessels below the disc, and there are many white irregularly disposed dots immediately to the temporal side and over the macular area. V. = $\frac{6}{6}$. T. n. In the R. there is no proptosis; the cornea and A. C. are normal. The pupil reacts both directly and consensually to light, and also to accommodation There is indistinctness of outline to the disc except to the outer side, and also slight elevation above

Digitized by Google

the surrounding hypermetropic (+ 1 D.) fundus. The blurred edge is radially striated. No hæmorrhages. Veins slightly fuller than normal. V. = $\frac{6}{6}$. There was considerable discussion as to whether the condition of the R. disc could be accounted for by the low degree of hypermetropia, or whether there was actual slight neuritis. The general opinion was in favour of the former view.

May 26th.—Vision under atropine: R. $\bar{c}$. + 2 = $\frac{6}{5}$; L. $\bar{c}$. + 2 = $\frac{6}{18}$.

Operation.—After an exploratory incision, the contents of the L. orbit were exenterated under chloroform. Recovery was uninterrupted. Seen on September 25th, there were no signs of local recurrence. On the other hand, the patient complained of slight dimness of vision in the R. eye three or four days previously. On ophthalmoscopic examination, it was found that the disc was swollen, its edges blurred and striated, and the veins were engorged. The child's general health was good, and there were no cerebral symptoms. On January 22nd, 1903, there was no evidence of optic neuritis.

Pathological examination.—The mass of tissue consists of the whole contents of the orbit, including the globe and eyelids. The greater part consists of a conical mass of dense white growth, moulded to the shape of the orbit. On the inner side it extends forwards to the orbital margin, and constitutes here the hard nodule felt through the skin. The growth anteriorly closely ensheathes the eye, which is not distorted. At the apex the cut end of the optic nerve, surrounded by new growth, is seen, so that the latter probably extends through the optic foramen into the skull cavity. The lids were removed, and the eye and growth, after hardening in 10 per cent. formol, were cut by a sagittal section which divided the nerve longitudinally.

Macroscopic section.—The tumour measures 23 mm. from the posterior pole of the eye to cut end of growth. The vertical diameter is 35 mm. in the thickest part, *i. e.*, on about a level with the posterior pole of the

Digitized by Google

eye. The horizontal diameter at the same level is about 36 mm. The growth, therefore, practically filled the orbit, extending forwards on the inner side to the orbital margin. It consists of dense, white tissue of almost cartilaginous consistence, the peripheral parts being less dense. The anterior surface forms a cup in which the globe lies, the growth being apparently continuous with the sclerotic. The optic nerve is entirely surrounded by, but passes unchanged through, the midst of the tumour, which is evidently continuous with the dural sheath. The cut end of the nerve is surrounded by new growth, which has also been cut through. It therefore probably extended into the optic foramen, and has not been completely eradicated. The outer surface is smooth, but this is apparently due to the compression exerted upon the orbital walls rather than to any fibrous capsule. The eye is normal except for the swollen disc, which is quite obvious to the naked eye, although the swelling is probably less than before hardening.

Microscopical examination.—The eye is normal except for some retinal congestion with minute hæmorrhages, and marked optic neuritis. The optic disc is much swollen and is hypernucleated, though not more so than the other parts of the nerve. Apart from a diffuse moderate infiltration with round-cells and a distinctly increased number of oval nuclei of endothelial type, the nerve looks normal throughout its length. The pial sheath is normal. The arachnoid is very evident owing to its great infiltration and the proliferation of its cells. The intervaginal space is much obstructed, the subdural space being absent over large areas owing to the adhesion of the hypertrophied arachnoid. The dural sheath, apart from some infiltration, is normal in its inner layers; peripherally it fades off insensibly into the tumour.

The tumour consists of dense masses of fibrous tissue, mostly hyaline, with a variable number of cells. This tissue is directly continuous with the sclerotic and dural sheath of the optic nerve, Tenon's capsule being unrecognisable. Embedded in the fibrous tissue are several

Digitized by Google

masses of closely-packed, round nuclei, belonging to round-cells in the interstices of a definite reticulum. The intervening tissue has a variable number of cells, and these are mostly of the ordinary spindle-shaped connective-tissue type. Scattered throughout the tissue are many round-cells, but there is an absence of leucocytic infiltration. The blood-vessels, which are scanty in the deeper parts, show very well-marked endothelial proliferation, and there are many indications of the same process elsewhere. Thus, there are faintly staining, large, oval nuclei, with deeply stained nucleoli, scattered everywhere between the broad hyaline fibres, and these doubtless belong to endothelial cells. There are no definite masses of concentric cells nor any patches of calcification (corpora arenacea). At the periphery the growth invades the orbital fat and surrounds the muscles, which it infiltrates without destroying. The fat is gradually absorbed and replaced by new growth, and this process is well seen in sections cut by the freezing-microtome, stained by Sudan III* and mounted in glycerine.

The growth belongs clearly to the connective-tissue group, and whilst the embryonic character of the cells is not especially evident, its progressive and infiltrating nature shows that it is sarcomatous. On account of the preponderance of fibrous tissue, it may be called a fibro-sarcoma. It is probably of relatively low malignancy, but it is obviously locally malignant.

The relationship of the endothelial cells in the tumour cannot be conclusively decided. As will be seen in the more general discussion on the pathology of these tumours, they are probably nearly all true endotheliomata; and this diagnosis is not inconsistent with the characters of the tumour now described, although it has not yet gone on to the definite formation of groups of concentrically arranged endothelial cells, such as are so typical of the true endotheliomata of the dura mater. In the absence

* *See* Parsons, "Arcus Senilis," *Royal London Ophthalmic Hospital Reports*, vol. xv, part ii, p. 141.

Digitized by Google

of these bodies, it is not surprising that there are no calcareous nodules, as in psammomata.

The exact nature of endotheliomata and their exact position amongst the sarcomata have not yet been settled. In the meantime, we shall be on the safe side in calling the tumour a fibro-sarcoma, with the tentative qualification, endothelioma.

It will be seen from the table that only eighteen cases of undoubted primary extra-dural tumour of the optic nerve have as yet been published. Of these, the first sixteen are given in the bibliography appended to Byers' paper. I have carefully gone through the literature on the subject in the excellent ophthalmological library attached to the Moorfields Eye Hospital, but have failed to discover any hiatus in this list. The seventeenth case, that of Mr. Arnold Lawson, was probably not available at the time the list was completed; the eighteenth case is reported above.

We may conclude from the paucity of the reported cases that the condition is much rarer than those of the true, or intra-dural tumours of the optic nerve, which are themselves rare. Of these, 102 cases are collated by Dr. Byers.

Remarks upon Primary Extra-dural Tumours of the Optic Nerve.

Etiology.

Age.—Of the 18 cases, 14 are available for exact details as to the age of the patients. Classifying these in decades, we have:

From birth to	10	. . .	5 cases.
,, 11 ,,	20	. . .	4 ,,
,, 21 ,,	30	. . .	1 ,,
,, 31 ,,	40	. . .	1 ,,
,, 41 ,,	50	. . .	2 ,,
,, 51 ,,	60	. . .	0 ,,
,, 61 ,,	70	. . .	1 ,,

Another patient is reported as being "young."

Digitized by Google

The number of cases is too few to be of any value for the determination of percentages, but most of the cases occur before the age of twenty. These are the ages at which the patients actually came under observation, and when the proptosis was well developed. If these ages are modified by the less trustworthy details derived from the histories, we obtain the following results as the approximate ages at which the proptosis commenced:

From birth	to 10	7	cases.
„ 11	„ 20	2	„
„ 21	„ 30	1	„
„ 31	„ 40	2	„
„ 41	„ 50	1	„
„ 51	„ 60	0	„
„ 61	„ 70	1	„

Hence, half the cases commenced before the age of ten. The disease is therefore essentially one of early life. The oldest case is sixty-five (11).* It is doubtful whether this case was a tumour of the nerve-sheath at all. It was a small round-celled sarcoma, which did not surround the nerve. From the drawing given in the original, it was adherent to the sheath for only a limited area, and the sheath was apparently normal. In all probability the tumour originated in other orbital tissues, invading the sheath secondarily. The patient who was fifty years of age (8), and had had proptosis for six years, was said to have been blind in the eye for eighteen years. Granting this, and eliminating Case 11, all the tumours commenced before the age of forty, and probably considerably earlier.

Sex.—The sex is stated in sixteen cases; ten were males and six females. In the intra-dural tumours there is a preponderence of females (56 to 39).

Eye.—In thirteen cases, the right eye was affected in five, the left in eight. (Intra-dural, R. 42, L. 52).

Injury.—Curiously enough, injury is very rarely mentioned in the histories as a cause. This is surprising in

* The numbers in brackets refer to the table.

Digitized by Google

consideration of the popular belief that tumours are due to injuries, but is probably explained by the fact that the proptosis would not appeal to the lay mind as being caused by a tumour.

Symptomatology.

Exophthalmos.—This is the symptom which has usually led to the patient being brought for treatment. It was present in all the cases which are fully reported when they came under observation. The predominant direction, directly forwards, agrees with von Graefe's rule for optic nerve tumours in general. In seven of the cases there was some modification, as follows:

Downwards . . .	2
Up and out . . .	1
Down and out . . .	2
Down and in . . .	1
Outwards . . .	1

Hence, as in the case of intra-dural tumours, and perhaps more so, while proptosis in or about the orbital axis is somewhat characteristic, too much stress is not to be put upon it as a sign of primary tumours of the optic nerve.

The progress of the exophthalmos is almost invariably slow and even, usually spreading over months and years. The only rapid case is Case 11, which we have seen reason to doubt as a true tumour of the nerve-sheath. Hence, these growths agree in this respect with the intra-dural tumours.

Pain.—Extra-dural, like intra-dural tumours, are generally painless.

Movements.—The movements of the eye are usually restricted, particularly in the opposite direction to any modification of proptosis directly forwards. In some cases the limitation of movement has been surprisingly small compared with the size of the tumour. In several cases this is accounted for by the freedom from adhesion

Digitized by Google

between the globe and the growth, Tenon's capsule having apparently escaped. There is, however, probably in general less mobility of the eye with these tumours than with the intra-dural ones; hence, as regards this symptom, they are more allied to other orbital growths.

Vision.—In the early stages vision is often nearly normal, and its failure slow. Many of the cases, however, only came under observation after blindness had supervened. In only one case (3) was vision said to be intact, and to remain so after operation; in this case the tests were probably somewhat primitive.

The eye.—Ophthalmoscopically, in the cases which have been fully reported early in the history of the disease, there has been optic neuritis of the "choked-disc" type. In the only case examined pathologically (18), the condition was essentially one of œdema, and was doubtless due to the partial blocking of the intervaginal space. The blocking may have been complete when the parts were *in situ*, and was almost certainly so in the optic foramen. As in cases of early "choked disc" from intra-cranial causes, there was very slender evidence of any true neuritis apart from œdema, there being practically no leucocytic infiltration. Similarly, in this stage, the vision may be normal, as in this case, or but little impaired. In later stages the neuritis is replaced by a post-neuritic atrophy.

During the neuritic stage retinal hæmorrhages have been observed. Other parts of the eye are usually normal until the changes due to lagophthalmos come on, when ulceration of the cornea, etc., supervenes, ending in panophthalmitis and total disorganisation.

In no case has the globe been implicated directly in the growth, nor has progressive hypermetropia from pressure been recorded, as in some cases of intra-dural tumours.

Digitized by Google

Pathological anatomy.

The extra-dural tumours of the optic nerve show a rather remarkable similarity in general type to the intra-dural ones. This is the more remarkable when we remember the very different tissues from which they are respectively supposed to spring. This leads us to doubt how far any of these tumours really spring from the optic nerve itself; in all probability, all, with the exception of the true gliomata, arise from one or other of the nerve-sheaths. Of course, in both cases we are discussing primary growths only. In this connection Dr. Byers' suggestion of a process of "fibromatosis," comparable to the condition met with in the subcutaneous tissues in elephantiasis, is extremely interesting and luminous. It is to be regretted that Dr. Byers did not discuss the pathology of the reported cases more in detail from this point of view. It seems, at any rate, to afford the best working hypothesis which has been brought forward for a very difficult class of case. The slow growth and relatively low malignancy of these growths, combined with their anatomical peculiarities, demand an explanation different from that of the more malignant growths which we are accustomed to classify as sarcomata. In these respects they are more allied to the infective granulomata, but differ from them in being single, usually free from glandular dissemination and from metastasis. The possibility of a local infection should be borne in mind, and the possibility of parasitic influence has more in its favour in these cases than in the case of carcinomata and sarcomata. It is not, of course, suggested that they are tuberculous or syphilitic in origin, but it is by no means improbable that many so-called endotheliomata, not only in this situation, but elsewhere, are due to parasitic irritation. The proliferation of endothelium, so marked in these cases, is an anatomical feature bridging over the gulf between many chronic inflammatory conditions and

Digitized by Google

these peculiar tumours. In the absence of further evidence it would be futile to theorise as to the possible or probable nature of the parasite which might lead to such results; but the attention of the believers of a parasitic theory of malignant growth (of whom I am not one) may well be directed to this type of growth as the field in which they are most likely to meet with success.

On the hypothesis which I have ventured to bring forward, the condition of "fibromatosis" must be regarded as chiefly secondary in nature, being determined by the obstruction of the normal lymphatic channels. The observations of Vossius, Salzmann, Delius, and others as to the absence of mucin in these cases, I consider to be of prime importance, and it must in future be chemically tested in all the growths in which the so-called mucoid or myxomatous condition is found. In the meantime, Dr. Byers adduces sufficient evidence to make his position a strong one. If we accept a condition of lymph stasis, it may account for the little tendency of affection of the lymphatic glands. Further, the anatomical disposition of the parts doubtless conduces largely to lymph stasis in the case of orbital growths.

Considering the extra-dural tumours more in detail, the pathological diagnosis is stated in all except the first two. Revising these in the light of more recent views, we find that eight may be definitely regarded as endotheliomata (Nos. 3, 4, 5, 6, 8, 9, 10, 13). Of these, two (4, 5) are called psammomata, and were doubtless typical tumours of the dura mater, now commonly regarded as endotheliomata. No. 6 was described as a "scirrhous carcinoma," but the very full description leaves no doubt that it was a psammoma. The descriptions of Nos. 8, 10, and 13 lead to the same diagnosis, though the first and last are called "angiolithic sarcoma" and "fibro-sarcoma" respectively. The reports of Nos. 3 and 9 admit of some doubt as to their true nature, but the presence of "osseous" particles and cysts in the former, and of an alveolar structure "like some carcinomata" in the latter,

Digitized by Google

render the diagnosis of endothelioma probable. To these a ninth case is probably to be added, *viz.*, No. 18. Here, early diagnosis and extirpation probably account for the absence of many of the more characteristic signs; but some doubt must still remain.

In three of the remaining cases the myxomatous degeneration was a prominent symptom. In two of these, judging from the condition of the eyes, the disease had probably existed for a considerable period. In all "fibromatosis" was a prominent feature, although lack of minute detail and the more modern tests render its exact nature doubtful.

No. 12 is to be regarded rather as a curiosity than of any real importance. No history is given; but the extraordinary opinion is stated that a minute "sarcomatous tumour developed on the optic nerve and caused meningitis."

There remain three small-celled sarcomata (Nos. 11, 14, and 15). We have already given some reasons for regarding No. 11 as an orbital tumour involving the optic nerve-sheath secondarily. The lack of detail in the reports of Nos. 14 and 15 renders discussion nugatory.

There are, therefore, only twelve cases in which we can be practically certain that the tumours were true primary extra-dural tumours of the optic nerve, and of these nine were almost certainly endotheliomata.

Diagnosis.

Diagnosis of these tumours from the intra-dural growths is usually impossible. The diagnosis of optic nerve tumours from other orbital growths is well summed up by Byers:—"As proptosis gives us the principal clue to the presence of an orbital growth, so *an associated early and profound reduction of vision* indicates more than any other symptom the presence of a tumour of the optic nerve. Taken together, these two symptoms alone, *unilateral and early exophthalmos with early amaurosis*, are almost in themselves proof positive of the presence of the condition under discussion; but if in

Digitized by Google

addition one has, as is frequently the case, *marked changes in the papilla*, the diagnosis of a tumour of the optic nerve is practically certain." The more prolonged maintenance of fair vision in the case of extra-dural growths is of some diagnostic value, but must not be overrated, since it occurs in some intra-dural cases.

Prognosis.

As regards prognosis, this, too, is on a *par* with that of other optic nerve tumours. The malignancy is essentially a local one, and in most cases metastasis need not be greatly feared. The impossibility of eradicating intra-cranial extensions, however, renders prognosis grave. There is some evidence in favour of the view that incomplete removal is not invariably followed by recurrence, but, of course, this is not to be relied on.

The records of the extra-dural cases are particularly faulty as regards results; these are often omitted, and, where stated, are recorded too soon to be of much value. The growths are usually slow, and, judging from the data at hand, the prognosis is more favourable than might be expected on general grounds. Thus, eliminating No. 11, we have ten cases in which the results are recorded. (I have not included my own case, since the result is not yet decisive.) Of these, five were "cured," three were followed by suppurative meningitis, and two recurred; but little stress can be laid upon these results, which are probably too optimistic.

Treatment.

In the majority of cases the tumour has been extirpated with simultaneous enucleation of the eye. It is noteworthy that in three cases the eye was preserved, and that these are amongst the earliest cases (Nos. 1, 3, and 6), and that in one (No. 3) the vision was intact in spite of a fortnight's suppuration.

Digitized by Google

In consideration of the fact that the growths are only locally malignant (and not always that) and that the point of danger is at the apex of the orbit, I think that Krönlein's operation is undoubtedly indicated, and that the eye should be retained wherever possible. This was clearly impossible in the case recorded above, owing to the intimate connection with the globe; but this condition is the exception rather than the rule, and even in Knapp's case (No. 6), where the globe fitted accurately into a socket formed in the tumour, the eye was kept with good results. (Attention may here be drawn to the extremely interesting observations of Knapp on the revascularisation of the retina in this case, and it is to be hoped that observation will be directed to this point, although it will doubtless often be futile.)

Addendum.

Pockley* records the case of a boy æt. 13 years. History: proptosis for six or eight months; no pain or inflammation; no injury or severe illness. Examination: L. proptosis straight forwards ($\frac{3}{8}$ inch), movements good, V. = $\frac{5}{12}$, moderate optic neuritis, slight ptosis due to trachoma; R. normal. Krönlein's operation was performed. Small growth removed from outer side of optic nerve, to which it was loosely attached for $\frac{1}{2}$—$\frac{3}{4}$ inch. Result: subsidence of optic neuritis, V. = $\frac{5}{12}$; perfect movements. Pathological report: spherical, completely encapsuled growth, $\frac{3}{4}$ inch in diameter; hæmorrhages seen on section; "round-celled sarcoma of an aberrant form, ... probably non-malignant, and not likely to recur."

This is probably an orbital growth adherent to the nerve, and not a primary extra-dural tumour of the nerve.

* Pockley, *Arch. of Ophth.*, vol. xxxi, No. 4, p. 114, 1902.

Digitized by Google

Primary extra-dural tumours

No.	Author.	Age, sex, eye.	Previous history.	Present condition.
1	Scarpa, 1816	Young M. ?	?	Exophthalmos downwwards; tumour felt under upper lid
2	Wardrop, 1818	? ? ?	?	"Amaurotic eye"
3	Critchett, 1852	28 M. R.	Exophthalmos up and out for fifteen months; no injury	Exophthalmos; preservation of sight; no pain
4	Billroth, 1872	16 M. R.	Exophthalmos eight years; V. impaired nearly as long	Tumour size of fist projecting from R. orbit; bulb atrophied, immovable; orbits widened, especially out; no pain
5	Neumann, 1872	20 M. ?	Migraine six years; exophthalmos three years	Exophthalmos; movements limited upwards; V. = nearly normal
6	Knapp, 1874	40 F. R.	Exophthalmos six months	Exophthalmos down and out; movements limited in all directions, especially up; V. = $\frac{20}{100}$, J. 14; intense optic neuritis three years later; V. = $\frac{1}{100}$; field normal
7	Savary, 1874	3 M. R.	?	Exophthalmos c̄ chemosis and ecchymoses; hypopyon, synechiæ, yellow exudate in pupillary area; pain; L. photophobia and ciliary injection
8	Dusaussay and Richet, 1875	50 M. L.	No vision in L. for eighteen years, noticed after extraction of a molar; exophthalmos six years, noticed after injury; gradual increase, especially last six months; pain in L. side of head at nights	Considerable exophthalmos, slightly down and in; movements slightly restricted; tumour felt up and in; simple optic atrophy (Galezowski)

Digitized by Google

of the optic nerve.

Operation.	Pathological anatomy.	Subsequent history and remarks.
Extirpation without enucleation	A knobby tumour the size of a nut composed of "lardaceous or scirrhous tissue," granular, like liver, softened in places; starting from sheath and extending between the levator palpebræ and the superior rectus	"Cure."
Extirpation with enucleation	A tumour of considerable size starting from the "neurilemma"	? Museum specimen.
Extirpation without enucleation	Tumour size of large walnut adherent to sheath, consisting of fibrous tissue c̄ many elongated cells, containing numerous "osseous" particles and a very few small smooth-walled cysts	Suppuration for fifteen days; complete cure, with intact vision.
Extirpation with enucleation	"Psammom-sarcom;" encroached on skull cavity on inner side; surrounded atrophied optic nerve	Incomplete removal; severe hæmorrhages at operation; vomiting and unconsciousness a few hours later; death in six days; *post-mortem*, suppurative meningitis.
Extirpation with enucleation	Tumour the size of a nut, ¾" long; surrounding nerve; growing from dura, which forms white line in section; partly compact tissue, partly alveolar; latter like cancer, consisting of fusiform cells c̄ concentric nests, calcified in places; former = large fibres c̄ sarcomatous cells; "psammom"	?
Extirpation without enucleation	Conical tumour, 30 mm. long, 23 mm. thick at base abutting sclera, 27 mm. in vertical diameter; surrounding intact nerve; firm; no cysts; "scirrhous carcinoma," consisting of alveoli c̄ epithelioid cells, concentric nests, and colloid degeneration of stroma; it grew from dural sheath (undoubtedly an endothelioma)	Cure; reported eight months after operation.
Extirpation with enucleation	Pus in A. C.; traces of lens; retina detached; vitreous transformed into a "calcareous mass;" optic nerve enlarged; dura thickened; black gelatinous mass inside sheath (= hæmorrhage); growth = "undoubted myxosarcoma, which appears to have started in the cellular tissue of the sheath."	Rapid recurrence; patient lost sight of.
Extirpation with enucleation	Tumour size of "large chestnut," knobbed, firm; nerve reduced to fibrous cord, indistinguishable inside tumour; very vascular c̄ calcareous nodules, surrounded by concentric layers of cells; "sarcome angiolithique" (endothelioma)	Suppuration; cerebral symptoms; paralysis of R. arm; death in eight days; autopsy, purulent meningitis; small tumour on L. optic nerve intra-cranially.

Digitized by Google

Primary extra-dural tumours

No.	Author.	Age, sex, eye.	Previous history.	Present condition.
9	Chenantais, 1879	18½ F. ?	Two and a half to three months' history	—
10	Ewetzky, 1882	14 M. L.	Exophthalmos eight years; slow increase; no pain; loss of vision three years	Exophthalmos down and slightly out; movements much restricted, especially up and in; V. = 0; post-neuritic atrophy
11	Lawson, 1882	65 M. L.	Exophthalmos five weeks; rapid increase	Exophthalmos slightly out; immovable; V. = 0
12	Peabody, 1883	? M. R.	—	Three weeks' malaise and apathy; meningitis
13	Brailey, 1886	42 F. L.	Exophthalmos eight years; blind seven years	Exophthalmos; movements much restricted; V. = 0; hypermetropia + 5 D. (R. + 1 D.); optic disc raised; margin ill-defined, whiter than normal
14	Sutphen, 1889	10 F. L.	Inflamed two years; soon became blind; exophthalmos six months	Globe disorganised; surface furrowed and ulcerated
15	Salzmann, 1890	? ? L.	Injury twenty years before; commenced at inner canthus	Size of fist; only cornea recognisable
16	Lagrange, 1894	5 M. ?	Erysipelas at three months; sloughing of upper lid	Exophthalmos; panophthalmitis
17	A. Lawson, 1899	2 F. L.	Blindness "suspected" three months; exophthalmos a few weeks	Very slight proptosis; movements good; fundus normal, except that the veins were large; three months later marked proptosis, slightly downwards; slight limitation of movements; optic atrophy
18	Author's case, 1902	7 F. L.	Slight injury four months before; treated for "thinness" and headaches one month before	Exophthalmos and ptosis; movements limited in all directions; optic neuritis; small nodule felt at inner side of lower orbital margin

Digitized by Google

of the optic nerve (continued).

Operation.	Pathological anatomy.	Subsequent history and remarks.
Extirpation with enucleation	Size of hen's egg (with globe), firm; eye normal, joined to tumour by loose tissue, except at optic nerve; surrounds nerve, which is normal; alveolar, "like some carcinomata;" cells very variable, some large; "névrome médullaire alvéolaire ou sarcome à cellules nerveuses" (probably an endothelioma)	?
Extirpation with enucleation	Ant.-post = 30 mm.; vert. = 45 mm.; horiz. = 40 mm.; greatest diam. = 55 mm.; loosely attached to sclera; encapsuled; firm, c one calcareous mass; nerve compressed, atrophic; sclera compressed, retina and choroid *in situ*; alveolar, c endothelial cells, concentric nests and bands, concrements; endothelioma	Recurrence in three months.
Extirpation with enucleation	Small, round-celled sarcoma	Recurrence, death in three months; metastases in cervical bronchial and abdominal glands, liver, etc.
No operation	Small fibrous tumour, size of half a small French pea; small round-cells between fibres of optic nerve	*Post-mortem:* meningitis; two small abscesses; "sarcomatous tumour developed on the optic nerve and caused meningitis."
Extirpation with enucleation	Tumour "about 1½" in each diameter," surrounding nerve, which "shades off into a fibrous tract;" "fibro-sarcoma" starting in outer part of dural sheath;" "whorled arrangement" of cells (probably an endothelioma).	
Extirpation with enucleation	Oval, nodular tumour, 6" broad, 5½" vertically, 2" thick, attached to nerve, which is swollen to double its normal size; small-celled sarcoma	"Cure."
—	Small-celled sarcoma of outer sheath of optic nerve.	
Extirpation with enucleation	Ovoid tumour of anterior half of optic nerve; base applied to sclera without being adherent; myxosarcoma of sheath; nerve intact; no true capsule	Cure (reported three months after operation).
Extirpation with enucleation	Tumour, conical, 1" × ⅓", surrounding optic nerve for whole length; not encroaching on globe; nerve quite free inside tumour, which is a "myxofibroma" of dural sheath	No recurrence fourteen months after operation.
Extirpation with enucleation	Tumour nearly fills orbit; ant.-post. = 23 mm.; vert. = 35 mm.; horiz. = 36 mm.; fibro-sarcoma (? endothelioma)	Probable recurrence (six months after operation).

Digitized by Google

Bibliography.

(1) Scarpa (1816).—Quoted by Demarquay, *Traité des Tumeurs de l'Orbite*, Paris, 1860 (*see* Jocqs). *Des Tumeurs du Nerf optique*, Paris, 1887, p. 208.

(2) Wardrop (1818).—*Morbid Anatomy of the Human Eye*, London, 1818, vol. ii, p. 273.

(3) Critchett (1832).—*Med. Times and Gazette*, vol. v, N.S., p. 465.

(4) Billroth (1872).—*Clinical Surgery*, New Sydenham Society, 1881, p. 116.

(5) Neumann (1872).—*Arch. f. Heilkunde*, vol. xiii, p. 310; 1872: *Trans. Internat. Med. Congress* (reported by Knapp), Philadelphia, 1876.

(6) Knapp (1874).—*Klin. Monatsbl. f. Augenheilkunde*, vol. xii, p. 439; 1874: *Arch. of Ophth. and Otology*, vol. iv, p. 323; *Arch. f. Augen- u. Ohrenheilkunde*, vol. iv, p. 209.

(7) Savary (1874).—*Ann. d'oculistique*, vol. lxxii, p. 214.

(8) Dusaussay (1875).—*Soc. Anatomique de Paris*, vol. i, p. 211. Richet (1875).—*Recueil d'Ophtalmologie*, vol. ii (2nd series), p. 295.

(9) Chenantais (1879).—*Bull. de la Soc. Anat. de Nantes*, 1879, p. 48. Jocqs, *loc. cit.*, p. 186.

(10) Ewetzki (1882).—*Arch. f. Augenheilkunde*, vol. xii, p. 16.

(11) Lawson (1882).—*Royal London Ophth. Hosp. Reports*, vol. x, p. 296.

(12) Péabody (1883).—*Med. Record, N. Y.*, vol. xxiii, p. 216.

(13) Brailey (1886).—*Tr. Ophth. Soc. U.K.*, vol. vii, p. 120.

(14) Sutphen (1889).—*Tr. Amer. Ophth. Soc.*, 1889, p. 457.

(15) Salzmann (1890).—*Finska lakaresallsk. Handl.*, vol. xxx, p. 490; *Annals of Surgery*, 1890, vol. ii, p. 219; *N. Y. Med. Journ.*, vol. liii, p. 82.

(16) Lagrange (1894).—*Journ. de Méd. de Bordeaux*, vol. xxiv, p. 73; *Gas. des Hôp. de Toulouse*, vol. viii, p. 147.

(17) Arnold Lawson (1899).—*Tr. Ophth. Soc. U. K.*, vol. xix, p. 123.

N.B.—This communication was illustrated by microphotographs.—Editor.

Digitized by Google

Digitized by Google

PLATE XV.

FIG. 1 illustrates Messrs. A. S. Morton and J. H. Parsons' communication on Hyaline Bodies at the Optic Disc (p. 135).

FIG. 2 illustrates Dr. F. E. Batten's communication upon Cerebral Degeneration with Symmetrical Changes in the Maculæ in two members of a family (p. 386).

Digitized by Google

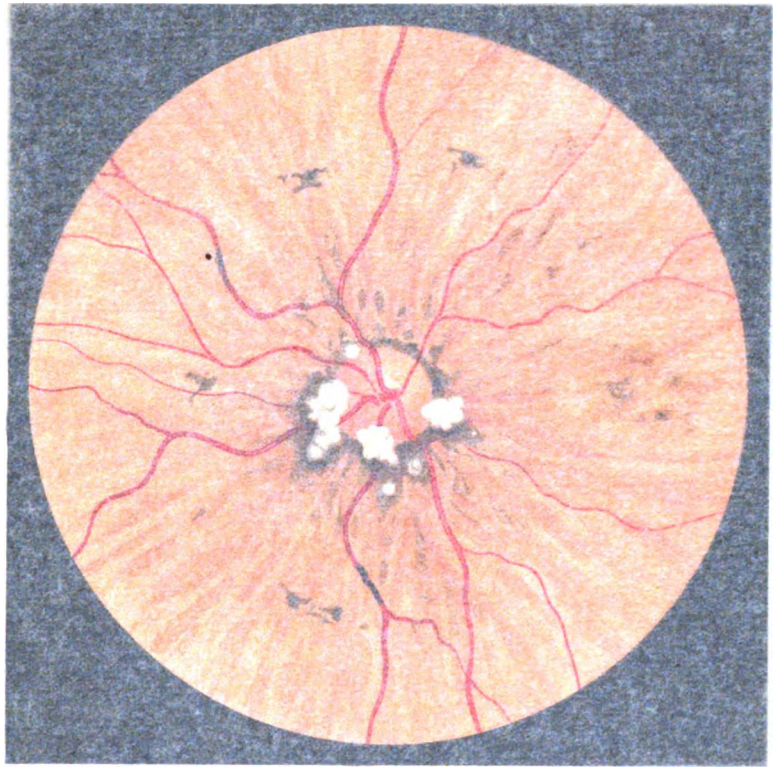

A. Stanford Morton, del. Fig. 1.

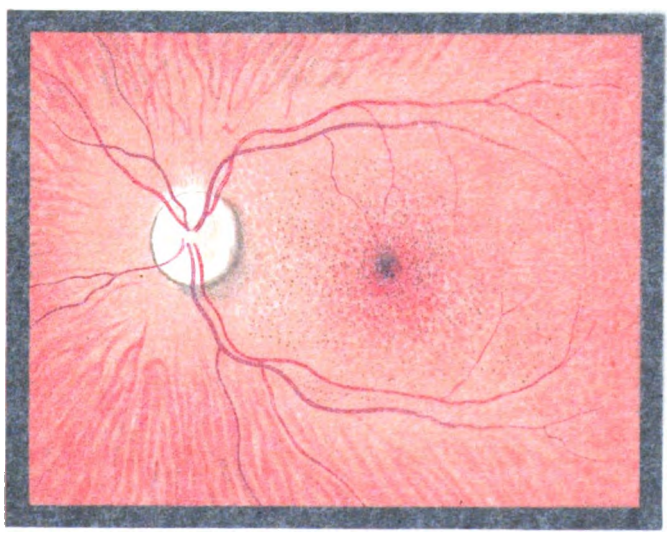

M. H. Brooks, del. Fig. 2.

Bale & Danielsson, Ltd.

Digitized by Google

PLATE XV

[illegible] J. H. Parsons' [illegible] Disc (p. 135).

[illegible] communication upon [illegible] changes in the [illegible]

Digitized by Google

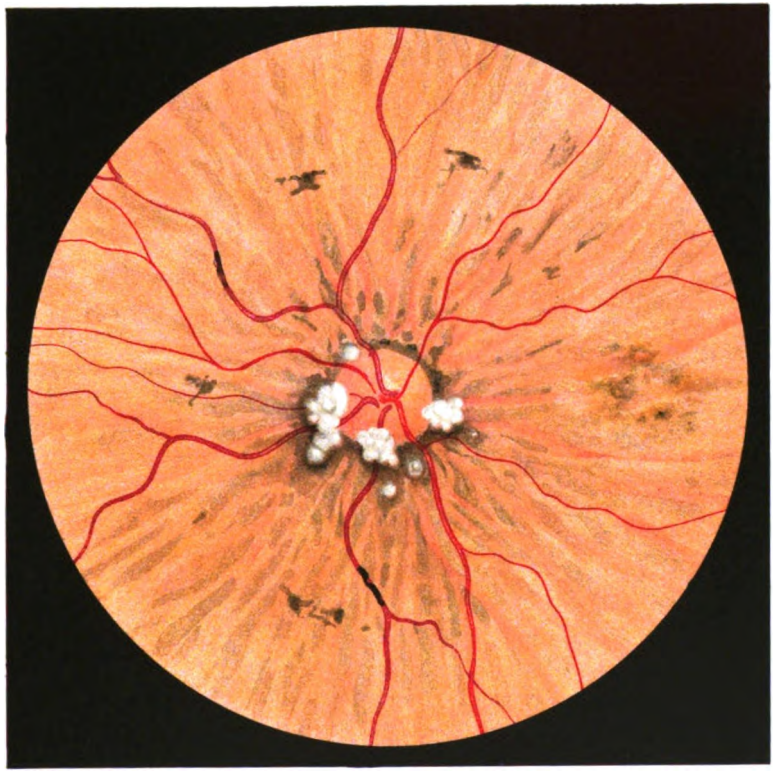

A. Stanford Morton, del. **Fig. 1.**

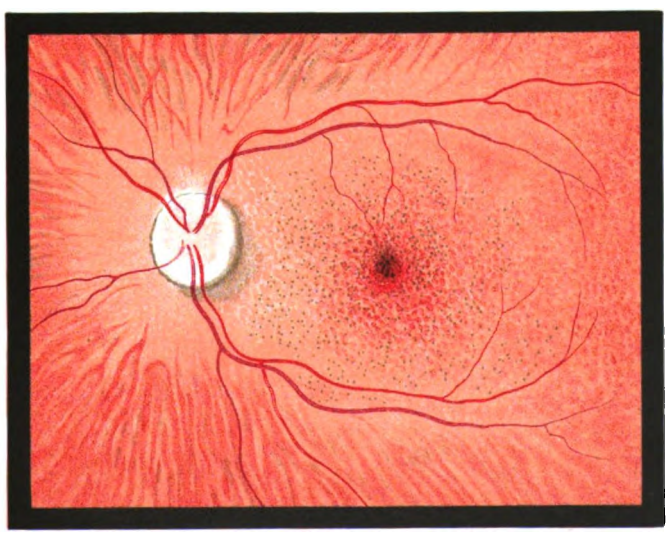

M. H. Brooks, del. **Fig. 2.**

Bale & Danielsson, Ltd.

Digitized by Google

Digitized by Google

6. *Hyaline bodies* (Drusenbildungen) *at the optic disc.*

By A. Stanford Morton and J. Herbert Parsons.

Two cases of hyaline bodies (Drusen) *at the optic disc.* *By A. Stanford Morton.*

(With Plate XV, fig. 1.)

Case 1.—F. M—, male, æt. 24 years, first came under observation in January, 1899, complaining of difficulty in getting about in the dusk. His V. was R. $\frac{3}{60}$, L. $\frac{6}{24}$. He was found to have retinitis pigmentosa with hyaline bodies at the disc in both eyes, the latter being most marked in the L., as shown in the accompanying drawing (*see* Plate XV, fig. 1). The appearances have not materially changed up to the present, but his sight is worse, *viz.*, R. $< \frac{1}{60}$, L. J. 14, $\frac{1}{60}$, and his field is contracted to 5°. *His parents were cousins.* He has one brother and four sisters, of whom one sister has retinitis pigmentosa, with night-blindness; one uncle has night-blindness.

Case 2.—G. W—, female, æt. about 20 years, complains of difficulty in near work and of aching of the eyes. Her vision is R. J. 1 slowly and $\frac{6}{9}$, L. J. 1, $\frac{6}{5}$. Fields full, with one or two small scotomata. There is no retinitis pigmentosa or night-blindness, but there is distinct pallor of the discs, with hyaline bodies on each. *The parents were second cousins;* the Mother is in an asylum. The patient's two sisters are said to have perfectly good sight.

Remarks.—The fact of consanguineous marriage in the parents of both these cases is of special interest, and does not appear to have been hitherto recorded in connection with *Drusenbildungen.*

Digitized by Google

Hyaline bodies (Drusenbildungen) *at the optic disc.*
By J. Herbert Parsons.

THE presence of hyaline bodies, called by the Germans *Drusenbildungen*, or granular formations, upon the optic disc, is a rare condition, which has received but scant notice in the text-books. The pathology of the condition is somewhat obscure, and as I have had the opportunity recently of making a pathological examination of a case which probably belongs to this category, a review of the literature and theories upon the subject may be useful.

Ophthalmoscopically, the disc is seen to be swollen, and the first impression is usually that the case is one of optic neuritis. The swelling may amount to 12 D. or 14 D. The vision is often unimpaired. More careful investigation shows the swelling is due to masses of small, translucent nodules. These are variously distributed; they usually surround the vessels at their exit from the nerve, thus involving only the central parts of the disc; in other cases they are mainly situated at the edge of the disc, which they obscure. They may cover the entire surface and even invade the surrounding retina for a limited distance, or they may form a ring round the disc, which is itself free from them. Both eyes are usually affected in unequal degree. The eyes are often otherwise healthy, but in many of the cases recorded there has been retinitis pigmentosa. In other cases, concurrent disease has probably been fortuitous. The prognosis is good.

Historical.

H. Müller (1), in 1858, first described concretions at both optic discs in an almost blind man, æt. 75 years. The nerves were atrophic and the retinæ exquisitely tigroid. The concretions, which were calcareous, were in about the position of the lamina cribrosa, and were

Digitized by Google

absent from other parts of the nerve and retina. In spite of the atrophy of the nerve, the level of the disc was raised 0·4 to 0·5 mm. above the level of the choroid.

Iwanoff (2), in 1868, in a paper on optic neuritis, described concretions in the optic nerve, anterior to the lamina cribrosa, in six cases. In the first both eyes were affected, and the vision had been completely intact during life. In the second both eyes were also affected, the patient being insane, with absolute amaurosis. In the remaining four cases only one eye was examined; the eyes were lost from injury or foreign body. In longitudinal sections there were generally two large concretions on each side of the central vessels. These consisted of a great number of quite small, concentrically laminated nodules, resembling amyloid bodies but giving no amyloid reaction. Iwanoff regards them as "drusige Ablagerungen der Glaslamelle der Aderhaut, welche vom Rande der letzteren aus in den Sehnerven eingedrungen sind."

Liebrich (3) was the first to observe the bodies ophthalmoscopically, as he states in his remarks upon Iwanoff's paper. In such cases, he says, the striking effect of the nerve-fibres is more marked, and bodies are seen in the papilla which reflect the light strongly. They sometimes extend somewhat beyond the choroidal ring. Owing to the strong light reflex they may be easily overlooked. There is often no defect of vision.

Neiden (4), 1878, described similar appearances in a girl, æt. 14 years, with retinitis pigmentosa. There was no consanguinity of parents, and eight other children were normal. Both eyes were affected, the left more than the right.

Jany (5), in 1879, gave details of a well-marked case with good vision and normal fields. The patient, a woman, æt. 37 years, complained of headache and pain in the eyes, which improved under treatment but without alteration in the ophthalmoscopic appearances.

Oeller (6) examined microscopically the eye of a woman, æt. 37 years, which had retinitis pigmentosa, and which had

Digitized by Google

been injured when she was one year old. There was a mass of laminated concretions lying in the nerve-fibre layer at the outer side of the disc. They had the same consistency as the surrounding tissues, stained faintly with hæmatoxylin, and did not give any amyloid reaction. There were none near the lamina cribrosa but drops of exudations of all sizes, staining with hæmatoxylin. Oeller combats Iwanoff's theory that the concretions are colloid bodies, and thinks they may be droplets of myelin.

Lawson (7), in 1883, recorded the first case in England under the title "syphilitic choroido-retinitis with peculiar growths at the fundus." In the right eye "upwards and outwards from the disc is a large white translucent patch, composed of very numerous confluent bead-like bodies, looking like the grains of a psammoma (*vide loco citato*, plate viii, fig. 1). . . The mass projects forwards, as is shown by its overhanging and large retinal vein, and proved also by ophthalmoscopic measurement, the refraction at the most prominent part of the mass being H 2·5 D., at the neighbouring parts E. The margin of the disc is about half surrounded by a somewhat similar deposit, translucent but not beaded. In the left eye two patches of the confluent beads are present, also near the disc, but the patches are smaller. The larger is seen with + 3 D. There is a diffuse choroido-retinitis." The patches were watched for many weeks but showed no change.

At the same meeting of the Ophthalmological Society, Story (8) showed a case with "anomalous distribution of the retinal arteries," (*loco citato*, plate iv, fig 2), probably due to previous blocking of the superior nasal artery. On the right disc were two greyish-white circular spots on the temporal half, rather near the centre (*see plate*). Story mentions a case of Benson's in which similar bodies covered the disc and extended over its edge at several points.

Stood (9), in 1883, described the clinical characteristics of two cases with (doubtful) optic neuritis. The first was a man, æt. 31 years, with chronic myelitis, paraplegia, and paralysis of sphincters of two years' standing.

Digitized by Google

Both eyes were affected. There was good central vision with contracted fields and diminution of light-sense. The nodules were mostly on the temporal side of the disc and towards the periphery. There was apparent optic neuritis. Eight years later, the nodules were much the same, but the disc was pale, showing signs of optic atrophy. The other case was a girl, æt. 17 years, with hypermetropic astigmatism and convergent strabismus. Both eyes were affected, the nodules occupying a similar position on the temporal sides of the discs, the centres being free. In the left eye there was an anastomosis of two arteries upon the nasal part of the disc; and in the right eye a tag of persistent hyaloid artery projected into the vitreous. Central vision was good; there were contracted fields and diminished light sense. Stood describes optic neuritis, but the evidence is decidedly feeble.

Masselon (10), in 1884, describes and figures the ophthalmoscopic appearances in the eyes of a man, æt. 57 years, with perfect visual acuity. There are groups of hyaline bodies on both discs, especially in the upper parts, the left disc being covered with them. They are each about the diameter of the large veins, but vary above and below this size. Apart from them and the swelling caused by them, the fundi are quite normal. In a girl, æt. 20 years, with retinitis pigmentosa, V. = ½, and contracted fields, there were hyaline spots at the periphery of the fundus in the neighbourhood of the proliferated pigment epithelium. These were possibly ordinary colloid bodies. The discs were normal.

Schäfer (11) gives an anatomical description of an eye with suppurative irido-choroiditis, in which there were a few laminated concretions, staining faintly, on the lamina cribrosa. The eye was that of a girl, æt. 13 years.

Hirschberg and Birnbacher (12) found *Drusen* on the papilla of a woman, æt. 60 years, who died of cerebral hæmorrhage. There was enormous swelling of the arachnoid sheath of the nerve in this case.

Ancke (13), in 1885, gave an instructive account of two

Digitized by Google

families with retinitis pigmentosa. In each case three out of five children were affected, and all those affected had *Drusenbildungen* except one, the youngest, æt. 14 years. The ages of the children varied from 16 to 19 years, and one was of the unpigmented type. In one boy, æt. 16 years, the hyaline bodies had not developed at the age of 14.

Remak (14) describes the ophthalmoscopic appearances in a man, æt. 52 years, with retinitis pigmentosa atypica. The right eye was shrunken, the result of a perforating wound. The lens of the left eye was removed in its capsule for cataract. It was then discovered that there was partial optic atrophy, with hyaline bodies upon the disc. These consisted of five or six large, round or oval, bluish-white masses on the inner side of the disc. A few fine vessels passed over them; there were no vessels over the retina. On the inner and outer sides of the retina were a few dense black masses of pigment. Minute investigation was impossible owing to nystagmus. V. = fingers at 1½ m. It is questionable whether this case belongs to the same category as the others reported.

Wedl and Bock (15) figure in their pathological atlas a section of the nerve-head from the eye of a patient who died of chronic hydrocephalus, æt. 24 years. There are several large calcareous masses, made up of a congeries of small nodules, the smallest being upon the surface.

Gessner (16), in 1888, described the clinical history and ophthalmoscopic appearances in a case of enopthalmus traumaticus. There were three prominent concretions, resembling mother-of-pearl, on the temporal edge of the disc. V. = $\frac{1}{8}$.

Nieden (17) returned to the subject in 1889, quoting six cases. He gives two good illustrations of the ophthalmoscopic appearances, in one of which the hyaline bodies cover the edges of the disc, whilst in the other they are confined to the central parts. In a man, æt. 29 years, both eyes were affected, the right worse, the hyaline bodies being confined to the edges of the disc, the centre remaining free. R. V. = $\frac{1}{3}$, J. 4; field for blue contracted, pro-

Digitized by Google

bably due to pressure on the nerve-fibres. After adaptation to the pressure, the vision rose to $\frac{10}{15}$, and J. 1, but the field for blue remained contracted. The mass reached forward 4 mm. (+ 12 D.) into the vitreous. The pressure on the vessels was not sufficient to give rise to pulsation, and on pressing the globe with the finger only the usual venous pulse was elicited. L. V. = 1, and J. 1. In another case, a man æt. 28 years, both discs were affected in the centre: in the left the hyaline bodies had spread outwards and reached the edge of the disc in places; in the right they had nowhere extended so far. R. V. = 1, and J. 1.; small corneal abrasion which rapidly healed; no other disease. L. amblyopic, otherwise healthy. In two of the other cases there had been severe injury to the head, and the *Drusenbildung* was unilateral. It commenced several months after the injuries, and in itself had nothing to do with the failure of sight. One patient, a man æt. 24 years, with hyaline bodies at the edges of the discs, had neurasthenia and other cerebral symptoms. Vision was normal.

Hirschberg and Cirincione (18), in 1891, published an account of a case of hyaline bodies at the disc associated with a sarcoma of the choroid. They were therefore able to examine the eye both ophthalmoscopically and pathologically. The patient was a woman, æt. 59 years; both discs were affected. R. V. normal; L. V. = $\frac{1}{5}$; field contracted up and in, corresponding to site of a choroidal sarcoma. The appearances in the R. were typical. In the L., after removal, a large mass, 1·5 mm. broad by 0·85 mm. thick, was found upon the lamina cribrosa. It was made up of the usual laminated hyaline bodies, partially calcified. They were cleared up by HCl, evolving gas, but were not dissolved. They were not amyloid.

Gurwitsch (19) describes similar concretions in the eye of a man, æt. 34 years, who died from chronic interstitial nephritis. The laminated nodules were situated in front of the lamina cribrosa, at the edges of the nerve, near the choroid. They stained strongly with eosin, acid fuchsin,

Digitized by Google

and carmine; not with hæmatoxylin. Small hyaline globules were scattered widely through the nerve in front of the lamina cribrosa, and there were some in the internuclear layer of the retina. Hyaline bodies were absent from the nerve of the other eye.

Purtscher (20) gives a woodcut of the ophthalmoscopic appearances of typical hyaline bodies from the eye of a woman, æt. 35 years. Both eyes were affected. R. V. = $\frac{6}{9}$; L. V. = fingers at 0·3 m.

Terson (21), in 1892, reviewed the subject in a paper on "Les verrucosités hyalines de la portion papillaire du nerf optique."

De Schweinitz (22) was the first, in 1892, to draw attention to the subject in America. His patient was a man, æt. 45 years, who was weak-minded, probably as the result of drink; he had been shot in the head twenty years before. In each eye the ophthalmoscopic appearances were closely similar: a slightly prominent papilla, with globular masses forming a circle just within the apparent margin, most prominent above, and capped by glistening particles. R. V. = fingers at 3 feet; L. V. = fingers at 6 feet. Sections show oval masses of concentrically laminated nodules on each side of the central vessels. The whole length of the optic nerves and all the cranial nerves were examined without finding any similar bodies. The nerves were atrophied, but not as a result of the *Drusen*. There were no colloid bodies in the lamina vitrea of the choroid.

Noyes (23), in discussing de Schweinitz's paper, mentions a young male adult who had had scarlet fever, albuminuria, and neuro-retinitis. Both eyes were affected and remained unchanged for twelve years.

Gifford (24) records the case of a girl, æt. 11 years, with very extensive affection of the R. disc. V. = doubtful p. l. Papilla and surrounding retina for about half a disc diameter were entirely concealed by a mass of hyaline bodies, the summit of which was 9 D. above the rest of the fundus; below the papilla this mass, after a slight constriction, was continued into another about twice the

Digitized by Google

diameter of the disc. The superior, supero-temporal, and supero-nasal arteries were occluded and formed glistening bands. In the vitreous, mostly in the posterior part, were a number of fine reddish opacities, evidently from comparatively recent hæmorrhages. L. normal. The mass altered considerably during more than two years' watching. The case shows that the prognosis is not always absolutely good, but the loss of vision may have been due to the concurrent vascular disease. In a man, æt. 45 years, with marked hyaline bodies in both discs, Bright's disease developed a year later, leading to death at the end of another year's interval.

In 1894 de Schweinitz (25) published two cases with similar bodies at the macula.

In the same year Heyl (26) published a case of "albuminoid (?) deposit on the optic disc and retina." The disc showed typical *Drusen;* there was a similar mass at the macula, a large isolated nodule in the retina to the inner side of the disc, and a faint white infiltration elsewhere, with punctate black spots in patches. The other eye had the same condition in less marked degree. The patient had a mitral systolic murmur, and œdema of the legs; no albumen or tube casts.

Sachsalber (27), in 1898, reported very fully upon a case in a woman, æt. 42 years. The patient was weak-minded, and died of carcinoma of the stomach. Both discs had a few hyaline bodies at the eyes, projecting 4 D. The eyes were otherwise normal. R. V. = $\frac{6}{9}$, L. V. = $\frac{6}{6}$.

We have, therefore, forty-two cases of *Drusenbildungen* more or less fully reported. The cases are really much more numerous than might be expected from the small number recorded, although the condition must be regarded as a rare one. Several cases known to the author have not been reported, and it is probable that the condition is not infrequently overlooked.

Ætiology.—The ætiology of the condition is unknown, but an analysis of the cases brings out one or two points

Digitized by Google

of interest, and leads to the hope that all the cases seen in future may be investigated and published, as the number is at present too small to be of much value. It is noteworthy that seven were cases of *retinitis pigmentosa;* in other cases of this disease it is not uncommon to find similar deposits in the more peripheral parts of the ophthalmoscopic field. Diminution of light- and colour-sense with contraction of fields is a common feature in many of the other cases, and some of these were probably cases of the unpigmented type of retinitis pigmentosa; at any rate, they direct attention to a coincident depression of the light-perceiving apparatus, a condition due probably to malnutrition (comparable to the night-blindness of xerosis). The malnutrition in many of the cases seems to be a purely local condition, of which the degenerative changes are the most marked objective sign; in others, those especially associated with nervous disorders, it is more general, and therefore more allied to the cases of xerosis with night-blindness. The other local condition which appears to have some ætiological relationship to the complaint is *injury*. How far this is an unimportant concomitant is not easily determined. It is mentioned in seven or eight of the cases, one of which was also a case of retinitis pigmentosa, another one of enophthalmos traumatica; and it was sufficiently striking in Nieden's cases for him to conclude that it may not infrequently be unilateral in cases of injuries to the skull. If due largely to malnutrition, traumatism is quite likely to be an important factor. The association with various *nervous disorders* is recorded in seven or eight of the cases, the nervous condition varying from simple headache or neurasthenia to chronic hydrocephalus and insanity. The important case of de Schweinitz belongs to this group. *Nephritis* (chronic interstitial) was the prominent associated disease in one case, and developed later in another. Association with sarcoma of the choroid and suppurative iridochoroiditis must be regarded as adventitious. There remains a considerable group of cases, probably much

Digitized by Google

larger than the statistics at our disposal would lead us to infer, in which the patients were apparently otherwise normal, both as regards local condition (vision, etc.) and general bodily health.

Age.—A general review of the cases leads one to the conclusion that the condition usually commences in early life. Its extreme chronicity, attended in many cases with no defect of vision, accounts for many cases in which the *Drusen* were fully developed in older patients when first examined. The extremely slow development of these bodies is an argument against any relationship with the more acute conditions referred to under ætiology, where copious hyaline deposits are regarded as being due to sudden injury, etc. The youngest patient was æt. 11 years and the oldest 75.

Sex.—The sex of the patient is definitely stated in twenty-eight only of the cases; of these seventeen were male and eleven female. Probably sex is of no ætiological importance.

Eyes.—In the great majority of cases both eyes are affected, though often in somewhat unequal degree. Nieden's dictum with regard to unilaterality in skull injuries may be borne in mind; but it is quite likely to be disproved in the future. The probability of such a degenerative change, closely associated with the central retinal vessels, being the outcome of a blood-state, is immensely increased by this prevalence of bilaterality.

Prognosis.—The prognosis, both for the eyes and for life, may be considered good, though associated disease must be estimated independently.

Pathology.—There are only two cases recorded in which *Drusen* were diagnosed ophthalmoscopically and the eyes examined pathologically, *viz.*, those of de Schweinitz and of Sachsalber. The anatomical peculiarities of the structures are, however, so characteristic that many other pathological observations are available, and must be considered. In Müller's case, there were some large (0·5 mm.) and many small yellowish bodies similar to colloid bodies of the choroid. On treatment with

Digitized by Google

hydrochloric or sulphuric acid the calcareous material was removed, and a concentrically laminated organic substratum remained. They were coloured yellow by iodine. They had the same structure in Ivanoff's cases, resembling amyloid bodies. They gave no amyloid reaction, and this observer regarded them, as mentioned above, as colloid bodies.* This opinion was accepted by Nieden and Jany as the explanation of their clinical cases. Oeller, after a careful description of the microscopical appearances and reactions in his case, dissented from this view. He found them situated on the outer edge of the disc, extending into the nerve-fibre layer of the retina, and anterior to the choroid, from which they were quite distinct. They offered no resistance to the microtome-knife, and were of the characteristic laminated form, with a crenated contour. The edges did not stain with hæmatoxylin, but the central parts were bluish-red. Iodine reaction was negative. The smallest droplets were found on the lamina cribrosa, and these stained blue with hæmatoxylin. In a series of sections Oeller was unable to trace any connection with the choroid; moreover, near the disc the lamina vitrea of the choroid had entirely disappeared. He compares them with similar bodies found in the central nervous system, and possibly derived from the myelin of the nerve-sheaths. In Hirschberg and Birnbacher's case the bodies were less developed; they stained deeply with eosin and picrocarmine, and gave no amyloid reaction. Wedl and Bock give no details, but describe their condition as a "Kalkmetastase." Hirschberg, in his communication with Cirincione, investigated the condition more thoroughly. On treatment with hydrochloric acid, the more central concretions gave off a gas and showed their laminated structure; with acetic acid this did not occur, but the peripheral ones cleared up. They gave a yellow with iodine, and no amyloid reaction with saffranin or

* In speaking of "colloid bodies" I refer to the so-called colloid bodies of the choroid.

Digitized by Google

methyl violet. Examination with crossed Nicol prisms showed that they were probably not crystalline (Perles). They were insoluble in water, alcohol, ether, 10 per cent. acetic, 5 per cent. sulphuric, and 10 per cent. potash. Millon's reagent was negative. The authors regarded them as comparable to calcareous nodules in the lungs, and not colloid bodies. Gurwitsch found them in the internuclear layer of the retina, where they could not be derived from the lamina vitrea. He considered them identical with von Recklinghausen's "hyalin," which that author regarded as the precursor of amyloid substance. In de Schweinitz's case the optic nerves and brain were examined, and no similar bodies found there after careful search. In Sachsalber's case the bodies were also present in various layers of the retina near the disc, especially in the outer nuclear layer. A considerable number were found behind the lamina cribrosa, which has not been the case in any other observation. The concretions were submitted to a most exhaustive micro-chemical investigation. The smallest globules stained with eosin; larger ones stained with hæmatoxylin in the centre and eosin at the periphery; the largest stained with neither in the centre, but had an inner zone, staining with hæmatoxylin, and an outer, staining with eosin at the periphery. This author, like Gurwitsch, considers the substance, at any rate in its early stages, to be von Recklinghausen's "hyalin." Previously stated chemical reactions are confirmed. An albuminous constituent is proved by two tests: (1) warming with strong nitric acid gives a yellow colour, which turns orange on addition of ammonia (xanthoproteic reaction); (2) Millon's reagent gives a pink coloration. The concretions turn black with strong sulphuric acid, and parts dissolve with strong potash. Various carmine stains behave like hæmatoxylin, acid fuchsin like eosin. Picrocarmine stains them deeper red the older the concretions are; vesuvin stains them brown, like nuclei. Gram's and Ziehl-Neelson's methods give a negative result. Weigert's fibrin stain gives a deep violet tinge to the

Digitized by Google

younger bodies, but fails to stain the older ones. Russell's method stains the lamina vitrea, etc., green, whilst the concretions become red. Ehrlich's thionin gives a dark violet on a blue ground, or a dark blue on a light blue ground—never green (Kamocki).

Most authors who have not personally investigated the question adhere to the view that the concretions are colloid bodies (Nieden, Jany, Stood, Masselon, de Wecker (28), Leber (29), Ancke, Remak). This view is not borne out either by exact observations or by theoretical considerations. True "colloid bodies" are sometimes found overlapping the edges of the disc, and the appearances which they present microscopically are totally different from those described in all the cases of *Drusen*. They are exactly like the colloid bodies found elsewhere upon the choroid, and are invariably covered with pigment-epithelial cells derived from the retina. Donders (30) first propounded the theory that these bodies are derived from the retinal pigment epithelium by a colloid metamorphosis of the nuclei. Müller (31) regarded them as outgrowths of the lamina vitrea, and these rival views still hold the field. The former theory has gained ground, and in its latest form the membrane of Bruch itself is regarded as the product of the normal activity of the pigment cells, whilst pathological stimulation of these cells results in the formation of colloid bodies (E. Treacher Collins, 32). If we accept this view it is quite impossible for concretions around the central vessels and situated upon the lamina cribrosa to be colloid bodies, seeing that there are no pigment cells there normally, and the specimens show no evidence of their migration there. On the other hypothesis it is necessary to suppose a prolongation of the lamina vitrea across the disc, and anatomical facts are not wanting to show that such may possibly exist (Kuhnt, 33). They can scarcely have survived, however, in Oeller's case, where the membrane of Bruch ceased at a considerable distance from the edge of the nerve. The probability, too, of an inert non-cellular membrane taking

Digitized by Google

on an activity such as is presumed to account for colloid bodies, is so remote as to cast great doubt upon the theory.

Further, according to Müller and others, including Oeller, the condition is supposed to be due to obliteration of the chorio-capillaris. This would not account for such structures upon the disc, nor can it be supposed to be present in eyes which are normal apart from the presence of *Drusenbildungen.*

There are other, more general arguments against the colloid body theory of *Drusen,* which are not subservient to any hypothesis. It is notorious that colloid bodies are the products of extremely chronic irritation, and that they are slow in their development. *Drusen* are found in many young patients in whom such a condition can scarcely be supposed to have existed for a sufficient length of time. Colloid bodies are, however, supposed to be present in the pigmented areas and elsewhere in many cases of retinitis pigmentosa, but it has not yet been proved that the yellowish spots seen ophthalmoscopically in these cases are true colloid bodies. If they are, the strength of this argument is thereby weakened.

The general adhesion to the colloid body theory is doubtless largely accounted for by the indefiniteness of other suggestions. That the concretions should be derived from myelin, as put forward by Oeller, is very unlikely. The corpora amylacea found elsewhere have quite distinctive characteristics which are not present in *Drusen;* moreover, the great myelin sheaths cease at the lamina cribrosa, and even if we admit the presence of extremely delicate myelin sheaths, such as probably exist around many so-called non-medullated nerve-fibres, the quantity of myelin present must be very minute. A theory supported by so little evidence scarcely merits further discussion.

Gurwitsch and Sachsalber resort to the very indefinite substance which von Recklinghausen called "hyalin," and which he regarded as the precursor of amyloid material.

Digitized by Google

Now hyaline deposits are quite common in various parts of the eye, and they give the same reactions as von Recklinghausen's "hyalin." On the other hand, in England, amyloid deposits are, at any rate in my limited experience, very rare, although they are undoubtedly seen commonly in the conjunctiva, etc., in other countries, especially Russia. It is probable that "hyalin" is not a definite body at all, and that hyaline deposits are really albuminous exudates undergoing gradual chemical change. This view is supported by the different tints which these deposits assume when treated with stains, so that with methyl violet one gets all gradations from violet to a pinkish tinge, yet not the final clear pink so characteristic of amyloid.

I think it is probable that there are two classes of degenerative deposits found in the eye, *viz.*, (1) those derived from the activity of the epi- or endothelial cells, and (2) exudations. The activity of epithelial cells is represented in the normal condition by the lens capsule and the lamina vitrea of the choroid; that of endothelial cells by Descemet's membrane. Their pathological activity is shown by the formation of a new membrane under a capsular cataract (Treacher Collins), by "colloid bodies" of the choroid, and by knob-like protrusions and splittings of Descemet's membrane. The second class, exudates, are mainly the coagulated plasma poured out from diseased blood-vessels or deposited by a stagnant lymph-stream, although the death of leucocytes and even of other tissue-elements may contribute a share. Whatever be the source, the "exudate" is a dead, inert, proteid mass, and its future history is entirely dependent upon its environment. This varies in an immense variety of ways. It is altered by position, whether in the cornea, the retina, the iris or choroid, etc., whether in close proximity to blood-vessels, etc., and also by the general condition of the individual. In favourable circumstances, *e. g.*, near capillaries with a healthy blood-stream, the deposit is rapidly absorbed, probably through the agency

Digitized by Google

of leucocytes. In other circumstances it becomes organised, *i. e.*, it affords a rich pabulum to neighbouring connective-tissue cells, which are thereby stimulated to divide and to multiply. In the cornea, in certain conditions, it remains for an indefinite time practically unchanged, when it is known as "hyaline" or "colloid" degeneration of the cornea; but if it is more exposed to desiccation, as near the surface of the cornea, calcareous salts become deposited in it from the blood-plasma. In the choroid, too, it frequently becomes calcified, and is then converted into bone. This process especially commences near the edge of the disc, so that a small ring of bone is formed near the choroid here. So, too, in the retina the exudate may undergo a variety of changes according to very varied circumstances. An example of coincident fatty and calcareous changes, with deposit of cholesterin, is given in the last volume of these *Transactions* (vol. xxii, p. 255). It not infrequently becomes organised or even calcified, and may then be invaded by osteoblasts derived from the choroid, so that it becomes true bone. This occasionally occurs also at the edge of the disc. An example is shown in some of the sections, where there is a patch of true bone in the retina at the edge of the disc. The bone is surrounded by multitudes of concentrically laminated bodies, exactly like those found in true *Drusen*. They are quite different from colloid bodies, and one cannot resist the conclusion that they are exudates which have been laid down in layers. The older parts have gradually calcified, and still later ossified. Examples might be multiplied almost indefinitely, but probably one of the best is found in the *Drusenbildungen* upon the optic disc.

Bibliography.

(1) H. Müller.—Graefe's *Archiv*, Bd. iv, Abt. 2, S. 12.

(2) Iwanoff.—*Kl. Monatsbl. f. Augenheilkunde*, Bd. vi, S. 425.

(3) Liebreich.—*Ibid.*, S. 426.

Digitized by Google

(4) NIEDEN.—*Centralbl. f. Augenheilkunde*, Bd. ii, S. 6.

(5) JANY.—*Ibid.*, Bd. iii, S. 167.

(6) OELLER.—*Archiv f. Augenheilkunde*, Bd. viii, S. 449.

(7) LAWSON.—*Trans. Ophth. Soc.*, vol. iii, p. 117.

(8) STORY.—*Ibid.*, p. 102.

(9) STOOD.—*Kl. Monatsbl. f. Augenheilkunde*, Bd. xxi, S. 506.

(10) MASSELON.—*Infiltration vitreuse de la rétine et de la papille*, Paris, 1884.

DE WECKER et MASSELON.—*Traité d'Ophtalmoscopie clinique*, 2e édition.

(11) SCHÄFER.—*Centralbl. f. Augenhkde.*, Bd. viii, S. 203.

(12) HIRSCHBERG and BIRNBACHER.—*Ibid.*, Bd. ix, S. 65.

(13) ANCKE.—*Ibid.*, S. 167.

(14) REMAK.—*Ibid.*, S. 257.

(15) WEDL and BOCK.—*Pathologische Anatomie des Auges*, Wien, 1886, S. 229.

(16) GESSNER.—*Archiv f. Augenhkde.*, Bd. xviii, S. 299.

(17) NIEDEN.—*Archiv f. Augenhkde.*, Bd. xx, S. 72.

(18) HIRSCHBERG and CIRINCIONE.—*Centrabl. f. Augenhkde.*, Bd. xv, S. 166.

(19) GURWITSCH.—*Ibid.*, S. 225.

(20) PURTSCHER.—*Ibid.*, S. 292.

(21) TERSON.—*Archives d'Ophtalmologie*, t. xii, p. 367.

(22) DE SCHWEINITZ.—*Trans. Amer. Ophth. Soc.*, 1892, p. 349.

(23) NOYES.—*Ibid.*, p. 358.

(24) GIFFORD.—*Archives of Ophthalmology*, xxiv, p. 395.

(25) DE SCHWEINITZ.—*Trans. Amer. Ophth. Soc*, 1894, p. 212.

(26) HEYL.—*Ibid.*, p. 355.

(27) SACHSALBER.—Deutschmann's *Beiträge*, Bd. iii, Heft xxi.

(28) DE WECKER.—Graefe-Sæmisch *Handbuch*, 1te Auflage, Bd. iv, S. 641.

(29) LEBER.—*Ibid.*, Bd. v, S. 910.

(30) DONDERS.—Graefe's *Archiv*, Bd. i, Abt. 2, S. 112.

Digitized by Google

(31) Müller.—*Ibid.*, Bd. ii, Abt. 2, S. 8.

(32) Treacher Collins.—*Researches into the Anatomy and Pathology of the Eye*, London, 1896, p. 89.

(33) Kuhnt.—Graefe's *Archiv*, Bd. xxv, Abt. 3, S. 216.

(*January 29th*, 1903.)

N.B.—This communication was illustrated by micro-photographs.—Editor.

Mr. L. Werner asked what was the difference in the ophthalmoscopic appearance of the two cases, *i. e.*, of *Drusen* as compared with colloid bodies.

Mr. Marcus Gunn objected to the word "*Drusen*," and thought the term "hyaline nodules" all-sufficient.

Mr. Parsons, in reply, said the ophthalmoscopic appearances of the hyaline nodules was well-known. On the other hand, the appearances of colloid bodies were not well-known. There were cases on record in which true or ordinary colloid bodies had been observed ophthalmoscopically first, and then examined microscopically. In those cases they were yellowish nodules, and the pigment did not make itself more manifest than under normal conditions. True colloid bodies were said to occur in some of the cases of retinitis pigmentosa, in which cases they were yellowish and quite unlike hyaline bodies. With regard to the use of the word "*Drusenbildungen*," he was following the example of predecessors, both English and German. Most of the recorded cases had been seen in Germany, and in English they had been described as "Papillitis drusen." But there was no papillitis, so he thought it would be well to use the term which would be recognised, and at the same time to suggest an English term for them.

Digitized by Google

VIII. DISEASES OF THE ORBIT AND SINUSES.

1. *Dermoid cyst of orbit, causing complete dislocation of eyeball.*

By H. A. Lediard.

The eyeball belonged to a man, æt. 49 years, who came under observation in the Cumberland Infirmary in July of 1902.

At the age of nineteen years, prominence of the eyeball was first noticed, and ten years later he could still see perfectly well; but during the next fifteen years the protrusion of the eye and sight-failure gradually increased, and for the last five years the protrusion of the eye has been marked, the sight lost, and much pain and discomfort have been present. On reception in hospital the left eyeball was found dislocated from the orbit and resting on the front of the malar bone, showing a downward displacement, well seen in the photographs (exhibited).

There was considerable increase in the palpebral fissure, and the upper eyelid was smoothed and carried forward with the eyeball, but the patient could not entirely close the lids. The muscles were unaffected, except the internal rectus, which allowed of a slight external squint. Across the cornea a commencing slough was seen, and the lens was opaque.

There existed a distinct swelling proceeding from the orbital cavity at the external angle. Pressure on this swelling was painless, and the tumour was doughy and inelastic. The skin over the tumour was unaltered.

Without having made any diagnosis, I removed the eyeball and examined the orbital cavity, evacuating a

Digitized by Google

large cyst with dermoid contents. This cyst had intruded near the outer angle of the orbit, where a groove in the bone was found. The sebaceous material was also found to be filling up the antrum, as well as the entire cavity of the orbit behind the displaced eyeball. Removal of the sac being impossible, scraping and packing were resorted to. Subsequently the floor of the antrum was opened to facilitate drainage. The contents of the cyst were fatty *débris* and flattened epithelial cells, but no hairs were found.

Remarks.—Dermoid cysts are far from being unknown in the orbit, and cases are on record where dealing with such at an early stage has not only checked proptosis but has preserved vision.

Amongst the many diseases and tumours of the orbit described in the *Transactions* of this Society, I have not found one of dermoid tumour; but in the sixteenth volume (page 176) Dr. Argyll Robertson makes allusion, in the course of some remarks, to "dermoid cysts which sometimes extended into the orbit."

In the *Report of the Proceedings of the Fourth Ophthalmological Congress*, in 1873, Mr. W. Spencer Watson has noted three cases of dermoid cyst within the orbit. One of his cases was in a woman, æt. 49 years; a tumour caused protrusion and displacement inwards of the eyeball. There is, however, no case given there where a complete dislocation of the eyeball resulted from a dermoid cyst of the orbit. Mr. Watson remarks that the hollowing out of the bone near the angle of the orbit sometimes observed in dermoid cysts of children is the first step in the invasion of the orbit by these dermoid cysts. Perforation is the next step, and, after that, the eyeball may be, as in my case, turned out of its home, and a neighbouring cavity, such as the antrum, utilised as a store for sebaceous secretion. In all probability, the case recorded is unique and may remain so, because such an example of neglect would hardly occur again.

Digitized by Google

In my case the cyst had grown at the external angular process of the frontal bone and had grooved the orbital margin, showing an erosion of bone in the vicinity.

(*October 16th*, 1902).

This communication was illustrated by several photographs of the patient taken at different dates.—EDITOR.

Mr. R. W. DOYNE asked what was the state of the outer wall of the orbit. In a case the notes of which he read before the Society that was completely absorbed. Mr. Collins had told him of a similar case, and he believed the view held was that the upper wall of the orbit was not absorbed, but had never existed. In this case the dermoid was in the outer side of the orbit but distinctly intra-orbital.

Mr. E. NETTLESHIP thought that dermoid tumours within the orbit were almost always found at the upper-inner angle, and that Mr. Lediard's case was unusual in this respect. He had himself removed more than one from the upper-inner part of the orbit and seen several others, and did not remember ever having seen one in a different situation. They often passed deeply between the muscles, and were difficult to remove; he especially remembered one such case in a boy, about 1880, where he thought at the time that some of the cyst-wall had been left behind and that the superior oblique had been injured; but it did well, and had remained without either recurrence or muscular defect to the present time.

Mr. J. H. FISHER said Mr. Doyne's case was hardly intra-orbital, but a dermoid in which the bony outer wall of the orbit failed to develop on account of the presence of the dermoid; so it was a temporal dermoid which was partly in and partly out of the orbit.

Mr. J. B. LAWFORD agreed that the most common position for dermoid in the orbit was at the upper and inner angle, a point upon which all the authorities agreed.

Mr. R. W. DOYNE said his was certainly on the outer side.

Mr. LEDIARD, in reply, said the wall of the orbit was

Digitized by Google

not perforated in his case. There was a groove at the outer angle, and intrusion took place in that way, and the tumour grew within the orbit through that groove. There was considerable erosion of bone, due to the subsequent growth of the tumour. The inner angle of the orbit was by far the commonest situation for dermoid growths to appear.

---

2. *Plexiform neuroma (elephantiasis neuromatosis) of temporal region, orbit, eyelid, and eyeball. Notes of three cases.*

By Simeon Snell.

With histological description by E. Treacher Collins.

(With Plates VII and VIII; and Text-figs. 4 to 10.)

Case 1.—In April, 1892, I was consulted by Miss B—, æt. 25 years, on account of a deformity of the right upper eyelid (*see* photo, Fig. 4).

I found that the eyelid was greatly hypertrophied. The inner third was nearly normal, but the outer two-thirds were very much thickened. The alteration involved the whole thickness of the eyelid, but it was especially marked at the edge of the lid. The mucous membrane was also thickened, and there was some ectropion towards the outer canthus. The lower eyelid at the outer part was also involved, but to a less degree than the upper one. The upper eyelid measured two inches along the edge. The patient was unable to raise the eyelid at all. The hypertrophy of the tissues was continued to the temporal region. The condition was congenital, but it had gradually increased. There was no history of inflammatory attacks. She had on three occasions undergone operations, which, however, she asserted afforded little or no relief to the deformity.

An operation was advised, but it was not performed until November 16th of the same year. On this date,

Digitized by Google

under ether, the outer part of each eyelid was removed, together with the thickened tissues reaching from the canthus for a little distance towards the temporal region. On section the integument and the underlying tissues presented very much the appearance described in the two cases next to be recorded. On December 9th it appeared that additional improvement would be effected

FIG. 4.

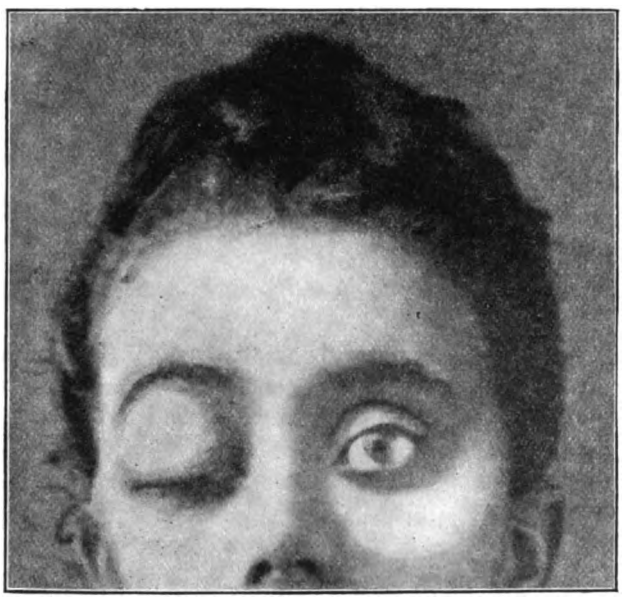

Case 1: Plexiform neuroma of eyelids and temporal region.

by a further removal of tissues, and this was accordingly done. The photograph I show was taken a few months after these operations. I learnt recently that whilst the deformity has remained very much reduced, the result is not so good as it was immediately after the operation, as there has been some slight increase of the growth.

CASE 2.—James K—, æt. 19 years, was admitted

Digitized by Google

under my care into the Royal Infirmary, Sheffield, on June 13th, 1902. He had come under my treatment in consequence of a deformity of the left eyelids and the left side of the face. The condition was congenital. There was no history of inflammatory attacks. He was brought to me when a baby aged about ten months, and he also came under my observation about five years ago, when a series of photographs were taken (Fig. 5) which show that the condition about to be described, although then present, was less marked than on his admission into the infirmary at the time mentioned. He says that the side of the face has increased in size during the last four or five months. The condition on June 13th, 1902, may be described as follows:

He was unable to raise the left upper eyelid, and could only open the eye with the aid of fingers. The lids, however, could be shut fairly tightly, but not so tightly as those on the right side. The left superciliary ridge was more prominent than the right, and the eyebrow on the left side was on a lower level than its fellow. Pressure with the finger showed that the upper bony margin of the orbit was at about the same level as on the right side, although the eyebrow was lower. The bony orbit measured 1½ inch vertically and 1⅞ inch horizontally. The upper lid was hypertrophied, flabby, and pendulous. Its lower margin sloped downwards and outwards to a line from the inner canthus to the level of the lower margin of the external auditory meatus, being 1½ inch lower than the right. It measured 2½ inches across and 1¾ inch from above downwards. The right eyelid was barely 1½ inch across. Through the outer part of the upper eyelid, and apparently in the orbit, a nodular mass was detected in the situation of, and what apparently was, the lacrymal gland. It measured about 1½ inch across by about 1¼ inch from above downwards. The hypertrophied integument formed two deep sulci on the left side of the face. The first furrow began at the inner canthus and extended at first directly downwards and then ran outwards, separating off the lower eyelid. The second ran downwards from the

Digitized by Google

left ala of the nose to the angle of the mouth, separating the hypertrophied integument between these two sulci. The tissues in the temporal region were also hypertrophied, but not to such a marked extent, measuring from above downwards about 2½ inches, and from before backwards about 2¼ inches. As far as one could feel underneath the integument, the superior maxilla was properly formed except

FIG. 5.

Case 2: Plexiform neuroma of eyelids, orbit and temporo-facial regions. (From photo. taken about 1897.)

that where it reached the orbital margin and the malar region it was more prominent than on the right side.

The eyeball was small and shrunken. It occupied the inner portion of the orbit; at the outer was the enlarged lacrymal gland and hypertrophied tissue. There was no light perception; the cornea was large and transparent, and the sclerotic was pinkish. The anterior chamber was deep. The iris was purplish brown in colour, with some

Digitized by Google

irregular yellowish markings near its pupillary margin. The lens was opaque, yellowish white in colour, with fine blood-vessels running across it. The left internal canthus and ala nasi were $\frac{1}{2}$ inch below those on the right side. The palpebral fissure was small, $\frac{3}{4}$ inch long, and was directed downwards and outwards. The left nasal bone

FIG. 6.

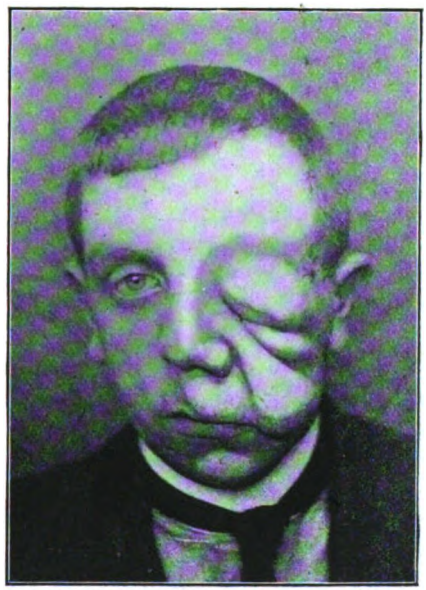

Case 2. (From photo. taken in 1902.)

was very prominent on the left side. The left ear was smaller, and $\frac{1}{2}$ inch lower than the right. The mouth, when opened, was thrown into the lozenge shape shown in one of the photographs. On swallowing, the left side of the mouth did not move equally with the right, so that food collected between the jaws and teeth. Patient could whistle a little, but not clearly. The lips closed tightly on both sides. There was a depression on the vertex; both parietal bones were affected, but the left one to a larger

Digitized by Google

extent. The hypertrophy involved the mucous membrane on the left side, that covering the left side of the palate and the left upper alveolus being decidedly thickened.

On November 17th, 1902, ether was administered, and the external canthus of left eye was divided and the incision carried outwards for about an inch. The integument beginning at the outer part of each eyelid was removed

FIG. 7.

Case 2. (From photo. taken in early part of 1903, after operations.)

for a distance towards the temple on each side of this incision, together with the lump in the orbit which was thought to be the lacrymal gland, with a quantity also of the thickened orbital tissues at the outer part. The edges of the wound were united by stitches, leaving the palpebral fissure very narrow. The tissues were found to be tough and fibrous, and as much as possible was removed from underneath the integument at the edges of the wound. The lump which had resembled an enlarged lacrymal

Digitized by Google

Digitized by Google

PLATE VII.

Illustrates Mr. Simeon Snell's paper on Plexiform Neuroma (p. 157).

The figure shows the microscopical appearances of the ciliary region and sclero-corneal margin on one side of the buphthalmic eyeball from Case 3. The root of an ill-developed iris is seen to be very thin and adherent to the cornea. In the small piece of the iris left free a wavy line is just indicated, showing the way in which Descemet's membrane terminated.

a. Thickened nerves in the cornea.

b. Thickened perineurium around the anterior ciliary nerves in the sclerotic, cut longitudinally.

n. Nerves in the sclerotic with thickened perineurium cut transversely.

Digitized by Google

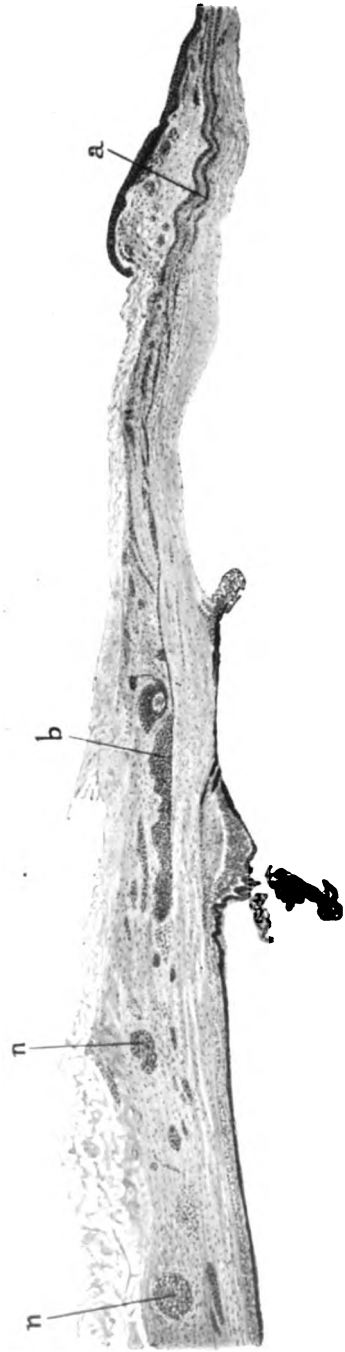

Adlard & Son, Imp.

Digitized by Google

Digitized by Google

Digitized by Google

PLATE VIII.

Illustrates Mr. Simeon Snell's paper on Plexiform Neuroma (p. 157).

FIG. 1 shows the microscopical appearances of a section through the skin and new growth in Case 2.

a. Thickened corium.

b. Subcutaneous tissue with thickened nerves in it cut in various directions.

c. The thickened perineurium of one of the nerves.

d. Nerve-fibres in the centre of the mass of thickened fibrous tissue.

FIG. 2 shows one of the nerves from the subcutaneous tissue under higher magnification.

c. Thickened perineurium.

d. Nerve-fibres with thickened endoneurium about them.

Digitized by Google

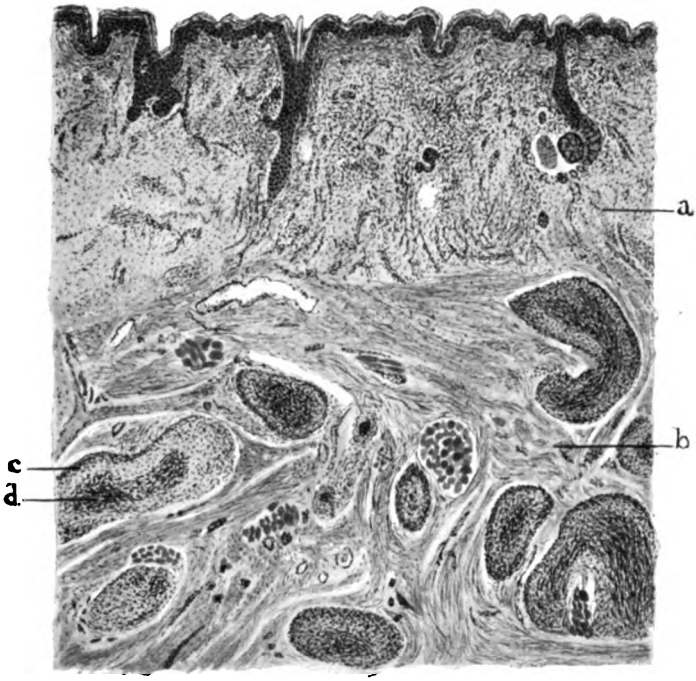

FIG. 1.

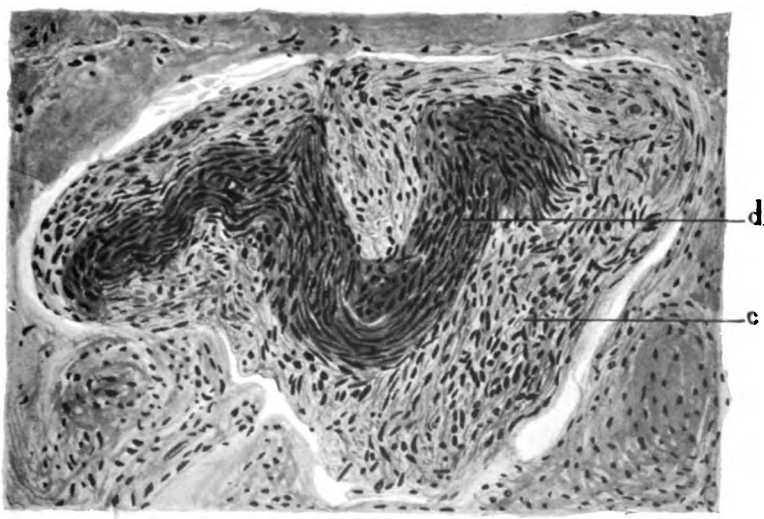

FIG. 2.

Adlard & Son, Imp.

Digitized by Google

Digitized by Google

gland was found to be somewhat kidney-shaped, measuring 1½ inch by ¾ inch. It was in a measure lobulated, the lobules being loosely held together and easily unravelled. It was semi-translucent, elastic, but soft to the touch, and not easily torn. The surrounding tissues were elastic and contained much fat. They were more or less translucent.

On March 16th, 1903, under ether, an incision was carried outwards from the canthus, stopping short a little distance from the ear. A considerable piece of the integument on either side of the incision was excised, and then a further quantity of the hypertrophied tissues were removed by burrowing under the skin at the sides of the wound. There was free hæmorrhage. The edges of the wound were stitched together. Portions of the thickened tissues which had been removed, together with the lobulated mass, from the orbit, were submitted to Mr. Treacher Collins, and he has very kindly supplied the following report upon their structure :

Report of the microscopical examination of the skin and eyelid from Mr. Snell's case of neuromatous elephantiasis.

Specimens consist of pieces of skin much thickened with new growth, a piece of the eyelid, and a mass of lobulated tissue. The latter, on dissection, is found to consist of a number of much convoluted, nodular, thick cords, held together in a compact mass by loose fibrous tissue. In the pieces of skin with new growth similar cords cut in various ways can be detected. Microscopical sections across the skin and new growth show (Plate VIII, fig. 1) :—some enlargement of the superficial papillæ and thickening of the overlying epithelium. Hyperplasia and thickening of the connective tissue forming the corium ; patches in it of marked hypernucleation, but nowhere any definite round-celled inflammatory infiltration. In the subcutaneous tissue, which is also much hypertrophied, are numerous variously shaped, well-defined areas, evidently produced by thickenings of the fibrous tissue of the

Digitized by Google

nerves. These areas can be seen in places to be surrounded by a sheath with endothelial cells. They present an outer zone of dense fibrous tissue, with small blood-vessels coursing through it, hyperplastic perineurium. A more central zone stains deeper with logwood, and in places is seen to present definite striation due to the nerve-fibres; the nuclei of the cells in it are much elongated. In some areas thickened endoneurium can be seen separating individual nerve-fibres. Sections through the eyelid show that the papillæ of the skin are enlarged, and that there is a marked increase in the amount of subcutaneous fibrous tissue, and in the fibrous tissue composing the tarsus. The loculi of the Meibomian glands have become widely separated by the hyperplastic fibrous tissue. Sections of the cords from the lobulated mass show them to be nerves with considerable thickening of the fibrous tissue elements, peri- and endoneurium. Sections of them stained with Weigert's stain show the medullary sheaths of the nerve-fibres, blue-black in colour in some places, collected together in the centre of a mass of fibrous tissue, and in others separated by thickened endoneurium.

Case 3.—Vernon D—, æt. 7 years, was admitted to the Royal Infirmary, Sheffield, on June 27th, 1902, on account of hypertrophy of the left eyelids and adjoining portions of the face. The condition was congenital. The patient was under observation three or four years previously. Since that time the hypertrophy had considerably increased. There was no history of inflammatory attacks. On admission to the Infirmary the following record was made:

The whole of the left upper lid is very markedly hypertrophied, but especially so at its outer and lower part. This hypertrophy of the tissues extends upwards and outwards beyond the orbital margin, involving the temporo-maxillary region nearly to the ear. Underneath the integument the tissues are somewhat thickened, but less so than in the preceding case (No. 2). The skin is also pigmented (freckle-

Digitized by Google

tinted). The bone is felt to be irregular on its surface. The lower margin of the upper lid runs in a direction downwards and outwards from the internal canthus, which is at a lower level than that on the right side. The lid then curves downwards, and at the outer part it reaches so low down as to be almost on a line with the ala of the nose. From this point it turns sharply upwards to the

FIG. 8.

Case. 3: Plexiform neuroma of eyelids, orbit, and temporal region, with buphthalmos. (From photo. taken in 1902.)

external canthus. The upper lid is projected forwards considerably in advance of that on the right side. There is some ectropion causing exposure of the conjunctiva along its lower margin for a breadth of nearly ¼ inch. The lower lid is overlapped by the upper lid in its outer half. There is some slight entropion. The lower eyelid is affected, but to a very much less extent than the upper.

The orbit is greatly enlarged, the measurements from

Digitized by Google

above downwards being nearly 2 inches, and across 1½ inches. The right orbit measures in the corresponding directions 1 inch and just over 1 inch. The eyeball is buphthalmic. The cornea is much enlarged and globular in shape. The lens is opaque and of a yellowish green colour. The movements of the eyeball in all directions

FIG. 9.

Case 3: Side view at same date.

are considerably impaired. The outer and lower portions of the frontal bone and of the squamous portion of the temporal bone are much more prominent than on the right side. The superior maxilla also appears enlarged, and is more prominent. The left cheek is rather fuller than the right. The left corner of the mouth somewhat slopes outwards and downwards. The left ala nasi is somewhat narrower than the right, and the outer edge slopes towards the mouth. The general tendency of the face is

Digitized by Google

to slope towards the left. The mucous membrane of palate and alveolus is not implicated in this case as it was in No. 2.

On July 16th, 1902, the globe was enucleated under ether.

On September 15th, 1902, he was again placed under ether. A large portion of the thickened upper eyelid at the outer part was removed, together with a smaller part

FIG. 10.

Case 3. (From photo. taken in early part of 1903, after operations for removal of Buphthalmic eye and tissues from eyelids and temporal region.)

of the lower lid, and the excision of the tissues was continued from the external commissure for about an inch towards the temporal region. On either side of the wound the tissues underlying the integument were excised, as were they also from the orbit at its outer part.

Considerable improvement in the boy's appearance followed this operation, but more benefit seemed likely to result from a further operation. The boy was therefore

Digitized by Google

put under ether again on March 25th, 1903. An incision was carried from the external canthus for about two inches towards the ear, and a considerable amount of tissue was excised on either side of this incision; and the effect was further increased by removing the thickened tissues underneath the integument on either side of the wound. The tissues were dense but elastic, and retracted when an incision was made. They were difficult to cut. The colour was somewhat yellowish. The tissues contained numerous coils of thick threads, which could be unravelled into long strings. These were as large as the thickest surgical silk, and had nodosities on them at intervals. The bleeding was very free, numerous large vessels being present as well as numberless small ones. The characteristics of the tissues ascertained at the time of the operation were similar in the three cases. In the first no microscopical examination was made.

The buphthalmic eye and portions of the tissues removed from the orbit, eyelids, and adjacent parts were submitted to Mr. Treacher Collins, and he has supplied the accompanying very complete account of the microscopical characters of the eyeball and other parts:

Report on the pathological examination of a buphthalmic eye, with a fibromatous condition of the ciliary nerves, received from Mr. Snell.

A left eyeball preserved in formol solution.

Measurements.—Of eyeball: antero-posterior, 37 mm.; vertical, 26 mm.; lateral, 27 mm. Of cornea: vertical, 12 mm.; lateral, 13 mm.

External appearances.—The cornea is not only much enlarged, but globular in shape. The piece of optic nerve left attached to the globe appears of about normal size; its sheath is somewhat distended. The ciliary nerves surrounding the optic nerve external to the sclerotic, are abnormally large and tortuous.

Internal appearances.—After equatorial section of the

Digitized by Google

globe, the retina is seen to be *in situ*. The choroid shows areas of atrophy with some pigment disturbance around the optic disc and just behind the ora serrata on the outer side. The optic disc is cupped. On reflecting the choroid from the sclerotic the ciliary nerves can be distinctly seen on the outer surface of the former; they run a perfectly straight course, and do not appear much, if any, larger than normal. The suspensory ligament of the lens is absent externally over about one third of its circumference; there is also a gap in it at the upper and inner part. Where the ligament is absent, both outwards and up and in, the margin of the lens is straight instead of being curved. The outline of the lens, instead of being circular, is roughly semilunar in shape. There is a partial coloboma of the iris outwards, the pupil, which is widely dilated, being pear-shaped with the point outwards.

Microscopical appearances.—Sections cut transversely across the optic nerve and the structures around it external to the sclerotic show atrophy of the optic nerve; the nerve-fibres in it are decreased in number, and the amount of fibrous tissue is increased. The pial sheath is shrunken away from the dural sheath, spaces being left between them. In the loose tissue external to the dural sheath numerous sections of the ciliary nerves are seen, which, on account of the tortuous course of the nerves, are cut in various directions. In these sections of the ciliary nerves there is a large increase of fibrous tissue, thickenings of their peri- and epineurium. In sections further forwards, where the nerves are seen perforating the sclerotic, this thickening of fibrous tissue around the nerve-fibres is also seen to be present. In sections across the tunics of the eye, cut transversely at about the equator of the globe, the choroid is abnormally cellular; this is not due to any inflammatory infiltration, but to an increase in the amount of the stroma between its blood-vessels. Sections passing transversely across the ciliary nerves show them to be slightly enlarged, but not very markedly so.

Digitized by Google

The retina is atrophied, and its several layers cannot be clearly differentiated. No rod and cone layer can be distinguished. Sections through the choroid and retina just behind the ora serrata on the outer side show the two coats adherent and much atrophied. Sections through the anterior half of the eyeball show the epithelium of the cornea thinner than normal. Its deep layer of cells are somewhat elongated, its superficial cells unusually flattened; there are but very few cells intermediate between these two layers. The substantia propria is also thinner than normal; here and there between its layers are small groups of elongated cells. They are most numerous immediately beneath the anterior limiting membrane. They are largest and best defined in the periphery of the cornea, where in places continuous tracks of elongated cells can be traced for a considerable distance; sometimes back into the anterior part of the sclerotic, where numerous thickened nerves are to be seen (Plate VII). It is probable, from their distribution, that these patches of elongated cells are due to enlargement of the nerves in the cornea.

Descemet's membrane with its lining endothelium is well defined; on its posterior surface, especially at the periphery, are numerous hyaline excrescences. On following it outwards on either side nothing can be seen of any ligamentum pectinatum. At the position where the iris ceases to be adherent to the cornea, there Descemet's membrane is seen to curve round on to the anterior surface of the iris and to become incorporated in its tissue.

The root of the iris is everywhere intimately adherent for some distance to the periphery of the cornea. In the position of the coloboma the iris is not entirely absent, only much smaller than elsewhere. Where it is smallest a piece of very atrophied iris is seen adherent to the cornea, which terminates in a very small free knob of iris tissue (Plate VII). Round the free border of this knob the pigment epithelium passes on to its anterior surface. In it, also, Descemet's membrane, somewhat corrugated, is seen to terminate.

Digitized by Google

On the opposite side of the globe, where the iris is more developed, its root, where it is adherent to the cornea, is not so atrophied. The ciliary body is small and composed of closely packed cells; very little definite muscle tissue is to be made out. The ciliary processes are small, and project out of the ciliary body in one compact little group. In one section, what appears to be a thickened nerve (*i. e.*, a continuous track of elongated cells) runs between the ciliary body and sclerotic. In the sclerotic overlying the ciliary body, standing out and sharply defined from the surrounding fibrous tissue, are seen numerous areas of deeply staining cells. These, on higher magnification, are made out definitely to be nerves with thickened endo- and perineurium. In or about the centre of the patches groups of healthy-looking nerve-fibres can be seen, cut either longitudinally or transversely. The thickened tissue surrounding these is in some patches fairly dense, and in others vacuolated. Sections across the lens show cells lining both its anterior and posterior capsules. Over a large area of the anterior capsule the lining cells have proliferated and formed some dense laminated tissue on its inner surface. No definite nucleated zone can be distinguished, and there is a large quantity of a homogeneous substance between the lens capsule and the lens fibres, and also between some of the lens fibres themselves.

Report on the pathological examination of a piece of skin removed from Mr. Snell's third case of elephantiasis (*Denton*).

Microscopical sections were cut and stained with logwood and eosine. They show the surface epithelium and its appendages presenting their normal appearance. The papillæ are large and numerous. The corium is thickened by hypertrophy of its white fibrous tissue and some increase of cells. Nowhere is there any sign of inflammatory exudation. In the subcutaneous tissue are numerous variously shaped areas, which are evidently due to sections

Digitized by Google

of nerves the fibrous tissue elements of which have become immensely increased. In or near the centre of many of the patches well-formed collections of nerve-fibres can be seen, cut longitudinally. They are easily differentiated from the surrounding hypertrophied perineurium by their regular parallel striation. In the thickened areas of fibrous tissue constituting the perineurium small blood-vessels can be detected.

Remarks.—De Schweinitz, in the *Transactions of the American Ophthalmological Society* for 1891, records a case very similar to, but less marked than, the first of mine. The patient was aged twenty years, and the right upper eyelid and the adjacent parts of the temporal region were affected. He gives illustrations of the patient before and after operation, and micro-photographs showing the histological structure of the tissues. He adds, moreover, a *résumé* of the literature up to that time, which is not extensive.

Alexis Thomson in 1900 published a monograph * *On Neuroma and Neuro-fibromatosis*, in which the subject of plexiform neuroma is fully discussed. He points out the close relationship between the following conditions :— (1) multiple neuro-fibromata (generalised neuro-fibromatosis) ; (2) plexiform neuro-fibroma (plexiform neuro-fibromatosis) ; (3) molluscum fibrosum (cutaneous neuro-fibromatosis) ; (4) elephantiasis neuromatosa ; (5) pigmentation of the skin associated with neuro-fibromatosis ; (6) "secondary malignant neuroma (Garré), being the sarcomatous transformation of one or other form of neuro-fibromatosis."

Recently Rockliffe † has recorded a case of plexiform neuroma with a careful description of the histology by Parsons. The following is an epitome of the case : The child, æt. 2 years, was shown at the Ophthalmological Society in 1899 as a case of pulsating exophthalmos. The

* *On Neuroma and Neuro-fibromatosis*, Alexis Thomson, 1900.

† Parsons and Rockliffe, *Trans. Path. Soc.*, 1903.

Digitized by Google

proptosis increased gradually without much affecting the child's general health, but finally interference became necessary, and Mr. Rockliffe exenterated the orbit in January, 1903, after tying the carotid artery. The child died very shortly after the operation. At the *post-mortem* examination it was found that the roof of the orbit had been absorbed and the growth had become intra-cranial, leading to great distortion of the bony and soft parts. On microscopical examination, the growth was found to consist of convoluted hypertrophied nerves embedded in dense fibrous tissue. These filled the orbit, extending backwards into the posterior part of the upper lid, leading to ectropion. Parsons, in recording this case with Rockliffe, collected references to the previously published cases. With his permission, I give at the close of this paper his bibliography. To this series of published cases I have been able to add the three included in this paper.

Plexiform neuroma of the eyelids is a rare condition, but it is rarer still when the orbit is affected. In Thomson's collected cases implication of the orbit is conspicuous by its absence. He says, "By far the most frequent situation is the subcutaneous tissue of the head and neck in the distribution of the trigeminal and superficial cervical nerves, although it may be met with anywhere throughout the sympathetic and peripheral cerebro-spinal nervous systems. The following table includes the figures given by Bruns, with the addition of recent cases:

Sites of plexiform neuro-fibroma.

Temple, forehead, and upper eyelid .	18	cases
Posterior part of neck and behind auricle	14	,,
Nose and cheek	4	,,
Region of lower jaw, and anterior half of neck	5	,,
Breast and back	8	,,
Extremities	9	,,
	58	

Digitized by Google

In my first case, the eyelids, especially the upper and adjacent temporal area, were affected. The eyeball was normal. In the second, the neuroma was very extensive —the orbit, eyelids, temporal region, side of face, and the mucous membrane of alveolus and palate were all affected. In the third, to an implication of orbit (in a lesser degree than the second case), eyelids, and temporal area, was added a buphthalmic eyeball, also affected.

In a case involving the orbit described by Sachsalber (*Beiträge zur Augenheilkunde*, Bd. cxi, Heft. 27, p. 523, 1898) a buphthalmic condition of the eyeball was present. The eye was enucleated, and microscopical examination of it showed increase of the peri- and endoneurium of the nerves in the iris. So far as I know, these are the only two cases in which this condition of the ocular nerves has been met with. It may naturally be asked whether there was any connection between the buphthalmic condition of the eye and the altered condition of the ciliary nerves. Apparently not. The increase of tension which caused the expansion of the globe is shown by the histological examination to be due to arrested development of the parts about the angle of the anterior chamber. The root of the iris had failed to become separated from the back of the cornea, and the ligamentum pectinatum with the spaces of Fontana had not formed. Descemet's membrane, instead of splitting up into fibres at the angle of the anterior chamber, turns, round on the anterior surface of the iris and terminates in its substance.

In my cases the impression given to the touch was very much as if the tumour was composed of fat and connective tissue.

De Schweinitz says that "plexiform neuroma may be and has been mistaken for congenital lipoma, encephocele, hydro-meningocele, cystic tumour, and cavernous angioma. The absolute diagnosis is dependent on histological examination."

Having observed these three cases, it seems to me, however, that there are certain characteristics, especially in

Digitized by Google

appearance, which would make one immediately recognise the nature of any case at all similar without a histological examination, however confirmatory that might be of the diagnosis. It appears that plexiform neuroma is congenital or is usually observed at a very early age. It is certainly progressive, although usually slowly so, and this is illustrated by my cases. My cases were all congenital.

Of the cases which Thomson tabulates, the age of onset of the plexiform neuroma is given in 44. The following are the ages: at birth, 24; in childhood, 3; at 1 year, 2; at 2 years, 2; at 4 years, 2; at 5 years, 1; at 6 years, 2; at 7 years, 2; at 8 years, 1; at 9 years, 2; at 14 years, 1; at 16 years, 1; in youth, 1.

It appears to be more frequent in males. Of the 54 cases in which the sex is given by Thomson, 19 are females and 35 males.

References.

Vernueil.—*Arch. gén. de méd.*, xviii, 1886.

Bruns.—Virchow's *Archiv*, l, p. 80, 1870.

Bilroth.—*Archiv f. klin. Chirurgie*, iv, p. 547, 1863.

Bilroth.—*Archiv f. klin. Chirurgie*, xi, p. 232, 1869.

Genersich.—Virchow's *Archiv*, xlix, 1870.

Marchand.—Virchow's *Archiv*, lxx, 1877.

von Recklinghausen.—*Ueber die mult. Fibrome der Haut u. ihre Beziehung z. d. mult. Neuromen*, Berlin, 1882.

Herczel.—Ziegler's *Beiträge*, viii, p. 38, 1890.

de Schweinitz.—*Trans. Amer. Ophth. Soc.*, xxvii, p. 48, 1891.

Jacqueau.—*Gaz. hebd.*, 27 Fév., 1896.

Sachsalber.—Deutschmann's *Beiträge*, Heft 27, p. 523, 1897.

Bruns.—Bruns' *Beiträge z. klin. Chir.*, viii.

Katz.—*Arch. f. Ophth.*, xlv, p. 153, 1898.

Emmanuel.—*Arch. f. Ophth.*, liii, p. 129, 1901.

Digitized by Google

PARSONS.—*Trans. Ophth. Soc. U. K.*, xxiii, 1903.
SNÉGUIRKW.—*Archiv. d'Ophth.*, xx, p. 375, 1900.
KRIEGE.—Virchow's *Arch.*, cviii, 1887.
UNNA.—In Orth's *Pathologie*, Berlin, 1894.
THOMSON, ALEXIS.—*Neuroma and Neuro-fibromatosis*, Edin., 1900.
GARRÉ.—Bruns' *Beiträge z. klin. Chir.*, ix.
GOLDMANN.—Bruns' *Beiträge z. klin. Chir.*, x.
LAHMANN.—Virchow's *Arch.*, cl.
JORDAN.—Ziegler's *Beiträge*, xviii.
FINOTTI.—Virchow's *Arch.*, cxliii.

(*July 3rd*, 1903.)

Mr. VERHOEFF (Boston, U.S.A.).—I should like to say a few words about a case of multiple neuro-fibroma associated with plexiform neuroma of the eyelid which came under my observation at the Massachusetts Charitable Eye and Ear Infirmary. The case was that of a man aged about 24 years, and was in many respects similar to the third case just reported by Mr. Snell and Mr. Collins. In this case, too, there was highly developed buphthalmos. The most striking feature of the case clinically, however, was the presence of four or five tortuous worm-like bodies, which could be seen running from the sulcus and attaching themselves to the sclera about 4 to 5 mm. from the cornea. Microscopic examination showed them to be nerve-fibres overgrown and surrounded by connective tissue, and that many other of the anterior ciliary nerves were involved in the same way but in a less degree. The new connective tissue accompanied the nerves into the superficial layers of the sclera, but I think not as deeply as in the third case just reported. There were some strands evidently of the same nature originally as the others, but from which the nerve-fibres had entirely disappeared. It seems to me that the involvement of the nerves of the globe in these cases gives an explanation of the buphthalmos. From a clinical standpoint alone it is rather striking that in three cases the buphthalmos should not only be monolateral, but

Digitized by Google

should occur on the same side as the plexiform neuroma. The involvement of so many of the ciliary nerves would strongly suggest that the glaucomatous condition was brought about through a disturbance in the metabolism of the eye. That the function of nerves can be disturbed by the new growth of tissue is shown very well by one of Mr. Snell's cases, in which the muscular movements of one side of the face were impaired; and, as I have already said, some of the nerve-fibres in my case had completely degenerated.

---

3. *Two cases of proptosis associated with disease of ethmoid and sphenoid respectively.*

By Walter H. Jessop.

These two cases I have published together, as though in the one the ethmoidal sinuses were involved, and in the other the sphenoid bone, they had many points in common. They were both of septic nature, acute in their progress and course, and completed as clinical studies by *post-mortem* examinations. They were marked especially by considerable proptosis, great œdema of lids, and no visible changes in the optic nerves. I am much indebted to my colleague, Dr. Gee, for the notes of Case No. 2.

Case 1. *Proptosis of left eye; orbital abscess; recurrence of proptosis and abscess; proptosis of right eye; orbital abscess; necrosed bone; septic cerebro-spinal meningitis; abscess in right frontal lobe; death.*—Arthur J. D—, æt. 9 years, schoolboy, was admitted into St. Bartholomew's Hospital on April 14th, 1898.

He said a stone struck him on April 5th on the left

Digitized by Google

side of forehead above the brow, but no bruise or wound was ever seen. Two or three days afterwards he complained of feeling ill, with headache and pain in the left eye.

On April 9th he was very sick, and the left eyelid suddenly swelled. On April 10th Dr. Rawlings, of Dorking, saw him, and found he had a temperature of 100·5° F.; pulse 120; tongue thickly furred. There was considerable œdema of left eyelid and slight proptosis of left eye. Since then his general condition has much improved, the œdema of lid has diminished, but the proptosis is increasing (Dr. Rawlings' note).

History.—Has never suffered from his eyes before. No previous history of serious illness. Had measles at two, and bronchitis at three years. About one month ago had operation for adenoids, but quite a simple one. Father and mother alive and well.

Present condition.—A delicate but healthy-looking boy. Tongue fairly clean. Temp. 99·2° F.; pulse 78, irregular in frequency, but not in force. Urine: cloud of phosphates; no albumen; no sugar. He complains of a constant throbbing pain at top of the eye.

Left eye.—Drooping of upper lid, which is reddened, hot, and œdematous. Lower lid somewhat swollen, very slightly reddened. The lids are closely approximated to the eyeball, and cannot be everted. Pressure upon the upper edge of orbit, slightly to nasal side of centre, causes pain. There is great proptosis directly forwards. Pressure backwards of the eyeball gives pain. No pulsation; no bruit. Movements of the eyeball are not lost, but very slight in every direction, and painless. Slight chemosis at inner canthus; bulbar conjunctiva is not injected, but a small subconjunctival hæmorrhage is to be seen on the nasal side; considerable lacrymation; no discharge. Cornea, anterior chamber, and iris natural. Pupils equal, and act normally. V. $\frac{6}{18}$. *Ophthalmoscope.*—Optic disc and fundus normal. Throwing light into the eye causes pain.

Digitized by Google

Right eye natural in every way. V. $\frac{6}{9}$.

Progress and treatment.—April 15th.—Patient has passed a good night. Temp. 100° F. He complains little of pain, but there is much tenderness. Proptosis has increased. Bulbar conjunctiva œdematous. Lower lid more swollen. V. $\frac{6}{36}$. Fomentations of boroglyceride relieved the tenderness.

16th.—As the proptosis and œdema were increasing, an incision, under chloroform, was made through the upper lid near the orbital margin, and about two drachms of foul-smelling pus evacuated from the back of the orbit. No bare bone could be felt, and it was thought to be a case of orbital cellulitis. A drainage-tube was inserted. Temp. 99·8° F. and normal in morning.

20th.—Proptosis and chemosis still much marked. Temperature slightly raised. Another incision made into orbit at outer side through upper lid and a little pus evacuated, and drainage-tube inserted. Eye normal by ophthalmoscope.

22nd.—Temperature normal and patient feels much better. Free discharge through first incision; very little discharge from outer incision.

29th.—Temperature has kept normal, and boy's condition much improved. Proptosis and chemosis much less. L. V. $\frac{6}{12}$.

May 13th.—The left eye now is only a little more prominent than the right; slight ptosis; no chemosis. The eyeball is slightly displaced down and inwards, and there is homonymous diplopia; tension normal. Eye quite healthy; fundus normal. V. $\frac{6}{6}$. There is considerable induration beneath inner part of superior orbital ridge.

27th.—Condition the same. Boy looks apparently in good health.

He was admitted again on September 8th with statement that he had been quite well till two days ago, when the lids began to swell, the eye became more prominent, and he vomited. He looks very healthy, and has gained flesh. Tongue slightly furred. Temp. 101·4° F.; pulse 92,

Digitized by Google

regular, good volume. Heart and lungs healthy. Urine 1014, acid, no albumen, no sugar. No discharge from nose, and nothing abnormal to be seen in nasal cavity.

Left eye.—Lids swollen, œdematous, and dusky, more especially the upper, and on this are two operation scars. Just above inner canthus is a tense, elastic, painful, tender swelling; marked ptosis. The eyeball is displaced forwards, downwards, and outwards, and its movements are restricted; vertical diplopia. No chemosis or conjunctival congestion. Cornea, iris, pupil, and tension normal. V. $\frac{6}{18}$. Optic disc and fundus normal.

September 9th.—Under chloroform, a free incision was made in scar of first incision, and a considerable quantity of foul-smelling pus evacuated; the abscess cavity was explored, and crumbling, gritty bone scraped away from inner side of orbit; the wound was syringed out with perchloride of mercury solution and a drainage-tube inserted.

16th.—The wound went on very well till yesterday, when there was considerable swelling of inner side of upper lid. Under chloroform, the wound was explored and some crumbling bone removed from inner wall of orbit.

27th.—The wound has quite healed, and patient is in no pain and looks much better. There is only slight proptosis, a little ptosis, no swelling, and no diplopia.

L. V. $\frac{6}{5}$. Eye normal in every way.

The boy was admitted again on November 8th with the history that he was quite well till November 3rd, when he was pushed down by another boy and came home with his nose bleeding. Next day he complained of headache and pain in his eye; on November 5th he was sick and feverish; on November 6th his eye began to swell, and the vomiting became constant; on November 7th the sickness stopped.

Patient appears well-nourished, face rather flushed, and cries a great deal, the eyes appearing red and swollen. Temp. 99·2° F. Tongue moist and furred;

Digitized by Google

bowels not open. Urine, 1014; no albumen, no sugar. Heart and lungs normal. Nose, no discharge, and nothing abnormal to be seen or found in nasal cavity. Ears, *nil*. *Right eye.*—Lids much swollen and œdematous; ptosis; movements limited, especially upwards and inwards. Marked proptosis forwards; there is a small, tender, fluctuating swelling immediately above inner canthus. Pupil slightly larger than left. Tension normal. *Ophthalmoscope.*—Fundus and nerve normal. *Left eye.*—Old scars on lids and some thickening. Slight drooping of upper lid, no proptosis; movements normal. *Ophthalmoscope.*—Optic disc and fundus normal.

Progress and treatment.—November 9th.—Rigor at 9.30 a.m., with rise of temperature to 105° F., preceded by vomiting; pulse 140; respirations 28. Temperature fell to 98·8° F. at 2 p.m. Tongue, white fur, clean at tip and edges; jaws natural; spleen palpable. Patient seems in distress, but does not complain of headache.

10th.—Temperature slowly rising all day, highest 102·6° F.; pulse 96, not quite regular; bowels open twice after calomel, 2 grs. Proptosis not increased; subconjunctival hæmorrhage at nasal side; there is some fulness above the eye, and distinct tenderness on pressure at nasal side under the supra-orbital margin. No rash.

11th.—Very restless and irritable; temperature rose to 103·6° F.; pulse 136; respirations 22; vomited two or three times; tongue coated with brown fur; a transient blotchy erythema on face, chest, and abdomen; spleen 1½ inches below costal margin; pain in back of neck; no rigidity of cervical muscles or retraction of head; increased frequency of micturition; urine natural, loaded with phosphates, no albumen; passed a motion under him; blood culture taken by Dr. Andrewes. *Right eye.*—Proptosis more marked; subconjunctival hæmorrhage increased.

12th.—Very drowsy but not so restless; wandered a little in the night; temp. 104·2° F. and fell to 101·4° F. Proptosis rather less and range of movement better.

Digitized by Google

Still complains of pain in neck and will not lie on back; holds the neck stiff and slightly drawn back with some rigidity. Knee-jerks absent.

Under chloroform, incision made through upper lid into orbit, and a few drops of fœtid pus evacuated; some loose bone found in roof of orbit; drainage-tube left in.

13th.—More swelling and œdema of right upper lid, and increase in proptosis. A counter-incision was made at outer side of upper lid and some blood-stained pus let out, and drainage-tube placed between incisions. At 10.30 p.m. severe rigor, temp. 106·4° F., sweated profusely, and at 3 a.m. temp. 99·2° F.

Blood culture taken on 11th gives negative results.

15th.—Much more drowsy, but answers questions put to him; slept badly last night, was very restless and delirious; slight rigor, with temperature of 104·4° F.; vomited several times this morning. Face twitches, especially on left side. Both eyes turned upwards and oscillate. Neck tender, rigid, and muscles all tense; no definite retraction; back also stiff. Heart and lungs *nil;* spleen easily felt. *Ophthalmoscope.*—No optic neuritis or fundus change.

16th.—Passed a very restless night, but took food better. At 7 a.m. pulse feeble and irregular; at 8.30 a.m. was then a good colour, pulse 108, regular and fair tension; he became conscious, and died suddenly and quietly at 9.10 a.m.

The general treatment has been quinine, chloral enemas to induce sleep, bromide of potassium, and tincture of opium.

Post-mortem notes (November 17th).—Body of thin, ill-developed boy. Between upper eyelid and margin of right orbit are two recent incisions, which lead downwards and backwards to orbital cavity, bare bone being felt in connection with roof of orbit. Scalp *nil.*

Meninges of brain and spinal cord.—Between orbital plate of frontal bone (on its inner aspect) and the dura mater there is a small subdural abscess, which contains

Digitized by Google

about a drachm of greenish pus. The basal portion of the brain from the optic chiasma backwards to the medulla and spinal cord is covered with a thick layer of green fibrinous pus; this lies chiefly in subarachnoid space, but slightly in subdural space. A similar condition exists within the theca of spinal cord as far as its lower extremity; the nerve-roots are surrounded by a similar layer of pus.

Brain.—The anterior half of right frontal lobe is the seat of a large abscess cavity, which contains about three ounces of greenish, foul-smelling pus; this cavity is bounded externally by brain tissue, the parts adjacent to the abscess being shreddy and in a gangrenous condition. This abscess cavity communicates posteriorly with cavity of right lateral ventricle, which, with the third and fourth ventricles, is filled and somewhat dilated by a quantity of greenish pus; the left lateral ventricle was not affected. The other parts of the brain were apparently normal.

Ethmoidal cells.—The anterior and middle ethmoidal cells of right side are well-developed and distended with greenish pus. No communication can be demonstrated between the lower of these cells and the infundibulum (no pus in right half of nose). Orbital plate of frontal bone on its inner side necrosed and denuded of periosteum both on cranial and orbital aspects.

Between roof of orbit and periosteum on inner side there is a small abscess cavity, which communicates with the anterior cells by a sinus which passes first through the periosteum and then above the muscle to the sinus mentioned before.

Retro-ocular tissues of right side on superior and internal aspects are matted together and infiltrated with green, fibrinous pus. The eyeball is not affected.

Left orbit.—The retro-ocular tissues are matted together as if from old inflammation, but there are no signs of pus or recent inflammation.

No fracture of or injury to nose could be detected.

Digitized by Google

Neck *nil.* Thorax *nil.* Abdomen: spleen enlarged, but other viscera normal.

Remarks.—This at first seemed to be a case of abscess in the orbital tissue. The history of the injury was inconclusive, and it is very doubtful if the operation for adenoids had anything to do with the origin. The upper and lower lids of left eye were swollen and œdematous, the proptosis very marked and at first straight forwards, not at all as if due to swelling of the ethmoid cells; there was slight chemosis, and no necrosis of bone. On emptying the abscess, the proptosis practically disappeared, and the vision of left eye, which was $\frac{6}{18}$, became $\frac{6}{6}$. There were never any ophthalmoscopic signs of changes in the optic disc.

It is curious that for thirteen weeks the patient was apparently quite well, and that the second attack should have occurred so suddenly. In this attack there were the first signs of caries of the orbital wall on the left side, and the eyeball was displaced down and outwards. The vision, as in the first attack, deteriorated in left eye, but was completely regained, and the boy left the hospital in his usual health and spirits.

The third attack was a month after his leaving the hospital, and this time his nose bled from a boy knocking him down, and the right eye began to follow the same course as the left had recovered from—swelling and œdema of lids, great proptosis directly forwards. The symptoms were much more acute, and pointed to cerebral affection. Throughout there was not the slightest sign of swelling or change in the optic nerve; the loss of vision in the first two attacks followed by complete recovery was probably due to pressure on the nerve. Nothing was ever found in the nasal cavity, and the only nose symptom was the epistaxis before the third attack.

Case 2.—*Infective thrombosis, following tonsillitis, involving circular and cavernous sinuses; necrosis of body of*

Digitized by Google

sphenoid bone; gangrene of superficial part of frontal lobe of brain at base; meningitis; death.

B. J. S—, male, æt. 31 years, a painter, was admitted into St. Bartholomew's Hospital, under Dr. Gee, on October 30th, 1901, for pain in the head and vomiting; soon after his admission, at 5 p.m., rigor, with temp. 104° F. Three weeks ago had "quinsy," and felt much better till October 20th, when he complained of severe headache and went to bed. Next day the headache continued, and on October 23rd he shivered and vomited.

History.—Subject to quinsy; no history or signs of venereal disease.

Present condition.—A pale, dull-looking man, who answers questions with marked slowness. Face, no paralysis. Neck, tenderness, especially on left side under the jaw; some enlarged glands. Ears, both contain much wax; after syringing, no perforation of membrane or other change found. Mastoid process, no œdema or thickness. Nose, nothing abnormal found. Temperature, rigor at 6 p.m. with 106° F. Pulse 80, regular; arterial walls very thick. Tongue furred. Bowels open. Urine 1024, slight cloud of albumen. Chest, heart, and lungs normal. Abdomen somewhat retracted, no tenderness. No discharge from urethra nor any signs of scar on penis.

Eyes.—Left eye: marked proptosis, the eyeball being directed straight forwards. Eyelids swollen and œdematous. External ocular movements good, no obvious squint. Holding up finger to left side of field he says there are two fingers, but answers inconsistent. Conjunctiva, extreme chemosis below and above. Pupils equal, and acting normally to light and to accommodation. *Ophthalmoscope.*—Optic discs a little pink; edges well-defined; no signs of swelling or neuritis. Vision in each eye roughly taken, and apparently he sees fairly well. Right eye: lids, media, pupil, and fundus are normal.

Progress and treatment.—October 31st.—Rigor at 6 p.m. with temperature of 106° F.

Digitized by Google

November 1st.—Rigor at 6 p.m. with temperature of 104·6° F.

2nd.—The vomiting continues; rigor to-day at 6 p.m.; highest temperature 104·6° F., lowest 100·8° F. Pulse between 68 and 114. Heart, short systolic murmur over cardiac area on left side, louder towards base; well-marked *tache cérébrale*. Legs, slight knee-jerk obtained; double ankle-clonus of very short duration. There is slight swelling of right lower eyelid. Left eye: the proptosis, chemosis, and swelling of lids the same. An incision was made with a scalpel through skin of eyelid below upper border of orbit, and the orbital cavity opened; a probe passed freely in, but no fluid, except a little blood, escaped.

3rd.—Left eye: the swelling of eyelids, proptosis, and chemosis have increased. No limitation of external ocular movements. *Ophthalmoscope.*—No changes in fundus of either eye.

There is much swelling of right cheek, and behind the palate there is an apparent fluctuating swelling. This swelling in palate was incised, but only watery fluid was evacuated. Two decayed teeth extracted without relief of symptoms.

Patient rapidly became comatose, and died on November 4th.

Post-mortem examination (eighteen hours after death) November 5th, 1901.

External appearance.—Extensive conjunctival hæmorrhage on left side, distinct proptosis of left eye.

Brain, weight 48 oz.; over left hemisphere there was a small effusion of blood, over the frontal lobe near the middle line between the dura mater and arachnoid. Over the right frontal lobe was a small quantity of purulent lymph on the vertex. The base of the brain was covered with offensive brownish-grey pus, and the membranes here were much matted and thickened. The brain substance at the base, especially the temporo-sphenoidal lobe, was in a semi-necrotic state; it was of a

Digitized by Google

greenish-blue colour, which extended for about ¼ inch inwards. The anterior extremity of the right temporo-sphenoidal lobe was softened and breaking down. The portion of the sphenoid immediately behind the sella turcica (the clivus) was necrotic, its surface bare and roughened. Both cavernous sinuses and the circular sinus were filled with dirty, offensive pus. There was a small abscess cavity in the superior orbital fat on the left side, just below the superior rectus muscle; the lateral sinuses were normal. The internal carotid arteries lay in pus, and their walls were softened; the jugular veins in the neck were not thrombosed.

Between the internal and external pterygoid muscles on the left side there lay a small collection of dirty-coloured pus; the anterior, ethmoidal, sphenoidal, and frontal sinuses were natural on both sides. Spinal cord not examined. Ear normal. Chest, œsophagus, glands of neck, larynx, and trachea normal. Lungs, firm pleural adhesions on both sides; both lungs congested. Heart, aorta, and vessels natural. Abdomen, intestines, peritoneum, and viscera normal. Jaws *nil*. Cultivation from heart's blood remained sterile.

Remarks.—As far as the second case is concerned, I think we may take it that the sphenoid was affected directly the acute head symptoms began. Such cases are very rare—in fact, I do not know of an acute one like this, in which the diagnosis was settled by a *post-mortem* examination. The severe initial symptoms, the œdema and swelling of the lids, great proptosis and chemosis of left eye, pointed to deep orbital mischief.

The diagnosis was made from these symptoms, and from the facts that the proptosis was straight forwards and the eyeball not displaced downwards and outwards, as in Case 1.

It seems strange that the optic nerve was not visibly altered, but the patient was too ill to make sure of the state of his vision, or the presence of retro-ocular neuritis.

Digitized by Google

Cases of caries and necrosis of the orbital plate of the ethmoid, and suppuration of the ethmoidal cells attended by ocular symptoms, are rare, and have been described by Eales and mentioned by Priestley Smith and some other authors.

I have not been able to find records of a case of acute necrosis of the body of the sphenoid like Case 2. Caries and necrosis of the sphenoid with eye symptoms have been described (4 and 5), and are generally due to syphilis or to tubercle. They run, however, a much more chronic course.

References.

(1.) *Die Krankheiten der Keilbein-Höhle und des Siebbein-Labyrinthes.* Berger and Tyrman. Wiesbaden, 1886.

(2) Berry.—*Diseases of the Eye,* 2nd edit., p. 411.

(3) Eales.—*Birmingham Medical Review,* vol. xvi, 1884, p. 107.

(4) Horner.—*Klin. Monatsbl. f. Augenheilk.,* 1863.

(5) *Medical Press,* 1903, p. 274.

(*July 3rd,* 1903.)

4. *Nævus of the orbit; evacuation of the orbit after removal of the eye.*

By W. T. Holmes Spicer.

(With Fig. 11 in text.)

Fanny H—, æt. 23 years, was first seen at Moorfields Hospital on June 23rd, 1898. The history given was that the left eye was always more prominent than the right, but the difference had scarcely been visible until her marriage four years before. She had had two children, and the swelling had increased during each pregnancy.

Digitized by Google

She thought that the sight of the left eye had always been defective.

She was a healthy young woman, and showed no sign of vascular disease in other parts of the body. The right eye was normal with V. $= \frac{6}{6}$. On the left side there was some proptosis, the lids were full and soft, they had a some-

FIG. 11.

Nævus of the orbit.

what blue appearance deep beneath the surface, and many of the superficial veins were distended. On deep pressure, the mass in the orbit felt "like a bag of worms," soft cylinders rolling over one another under the finger. No hardness could be felt, and no pulsation was present. V. $\frac{6}{24}$; fundus normal; movements not appreciably impaired.

The case was thought to be one of nævus of the orbit.

Digitized by Google

The patient was admitted to the Hospital on July 7th, and the swelling was electrolysed. The patient went out after a few days, and did not return till February, 1899, six months later. There was little change, and the tumour was electrolysed again. After leaving the Hospital, the patient disappeared for twelve months. On her return on March 6th, 1900, the note says there was considerable proptosis of the left eye, the lid being tightly stretched over it, and the lower part of the cornea exposed; the vessels of the conjunctiva were engorged; the cornea was clear; the movements of the eye were limited. (The photograph, Fig. 11, was taken at this time.)

Above the globe was a hard, almond-shaped swelling firmly fixed in the situation of the lacrymal gland, and another hard mass could be felt lying deeply in the orbit below the eye. At the inner side of the orbit there was a soft, fluid swelling, about the size of a hazel-nut, which could be emptied by pressure but which filled again immediately.

The question arose as to whether these hard masses were new growths or whether they were consolidations produced by the previous electrolysis. As no hardness had been present before, they were judged to be the result of the electrolysis, and the patient was sent to St. Bartholomew's Hospital to Dr. Lewis Jones for further treatment.

Dr. Lewis Jones reported that electrolysis was not advisable, as there was probably a free communication through a large opening at the apex of the orbit with the cavernous sinus. The patient was then taken into the Hospital again with the object of investigating the nature of the hard masses in the orbit; an incision into each of them from the conjunctiva gave vent to a quantity of dark, porter-coloured blood.

Shortly after this the cornea became ulcerated from exposure, the ulcer perforated, and on March 27th, 1900, the eye was enucleated. After removal of the eye, the tumour steadily increased in size, and the patient was shown at a meeting of the Society on December 13th, 1900.

Digitized by Google

Advice was asked as to the propriety of dealing further with the tumour. Nearly all the Members who expressed an opinion said they would not touch it, unless compelled, on account of the risk of serious hæmorrhage.

During 1901 the patient became pregnant again, and, as had occurred with each previous pregnancy, the tumour increased considerably, so that there seemed to be some risk of its bursting spontaneously. She was therefore taken into St. Bartholomew's Hospital and shown at the surgical consultations there, when the opinion was unanimously expressed by the surgeons that it was necessary to remove the contents of the orbit without delay. This was done on June 24th, 1902. The patient was put under an anæsthetic, the outer canthus was divided and the lid turned up; the periosteum was divided round the margin of the orbit, and freed from the bone all round till the tumour was isolated in the centre of the orbit, and only remained attached to the apex. Considering that the orbit could easily be packed, and that any hæmorrhage could be controlled by pressure, I then took a strong pair of scissors and cut through the pedicle. Contrary to expectation, the hæmorrhage was very trifling, and what appeared likely to be a formidable operation resolved itself into a very easy one. The patient made a rapid recovery.

The pathological report which is appended showed the tumour to be a cavernous angioma with an abundant supply of arterial blood. Another peculiarity in the specimen was the very large amount of muscular tissue in it, apparently hypertrophied recti muscles.

To sum up:—this was a cavernous nævus of the orbit, dating from early life, but only increasing rapidly after marriage, the increase coinciding with successive pregnancies. Electrolysis produced a certain amount of consolidation in it, but did not arrest its growth. Removal of the eye, by diminishing pressure on the tumour, allowed it to grow more rapidly than before. Exenteration of the orbit was carried out without difficulty; no hæmorrhage of importance occurred. No absorption of bone from the

Digitized by Google

walls of the orbit had taken place, and it would have been easy to control hæmorrhage by pressure had it been necessary.

Pathological Report on tumour removed from orbit (L.) of Fanny H—, æt. 25 years, June 24th, 1902.

Tumour after removal was roughly spherical, and measured about two inches in diameter. On division it was found to contain innumerable spaces, many filled with blood-clot and others with porter-like fluid. Under the microscope these spaces are seen to be lined with endothelium and to be supported by fairly dense connective tissue with many large, well-formed arteries. One of these vessels shows extensive endarteritis. The recti muscles, which were incorporated in the tumour, are greatly hypertrophied, probably due to increased vascular supply.

Diagnosis.—The tumour is a large cavernous angioma, and in no part is there any evidence of malignancy.

(Signed) E. W. BREWERTON.

(*January 29th*, 1903.)

Digitized by Google

IX. PARASITES.

A case of intra-ocular echinococcus cyst with brood capsules.

By L. Werner, M.B.Dublin.

(With Plates IX and X, and Figs. 12 and 13 in text.)

J. M—, a young healthy man, a farm labourer, æt. 28 years, was admitted to the ophthalmic department of the "Mater" Hospital on the 13th of December last.

In May of the same year—that is to say, seven months before his admission—he noticed that he could not see the upper half of any object with the left eye. The latter gradually became completely blind, but never gave him any trouble until a month ago, when it became bloodshot and painful. There is now some ciliary congestion; the anterior portion of the eye is slightly staphylomatous, and presents a crescentic blue line in the ciliary region above, resembling, in appearance and position, a subconjunctival rupture of the sclerotic, but he is quite positive that he received no injury. The cornea is clear; A.C. normal. The iris is atrophic, and the outer half, which is adherent to the lens, is very thin and translucent. A small portion of the uveal pigment is partly detached from the pupillary margin at the upper inner side. I was unable at the time to satisfy myself as to the exact condition of the lens. Deeply situated in the pupillary area was a greyish-white fluffy opacity, not uniform but slightly mottled, and although it did not look like any opacity of the lens which I had ever seen, it appeared to be situated too far forwards for an opacity in the vitreous, and, at the same time, not quite so concave as an opacity in the posterior layers of the lens. V. = no

Digitized by Google

P. L. T. raised, but not high. No red reflex with the ophthalmoscope.

The staphylomatous condition with raised tension, occurring in an eye which had gradually become blind, suggested the presence of an intra-ocular tumour. I therefore removed the eye.

The eyeball, after having been in 10 per cent. formalin for a few days, was opened by a transverse section through the sclerotic above; some watery fluid escaped, which I at first took to be fluid vitreous, but which in reality came from the interior of a cyst. On separating the lips of the incision a delicate greyish-white membrane became

FIG. 12.

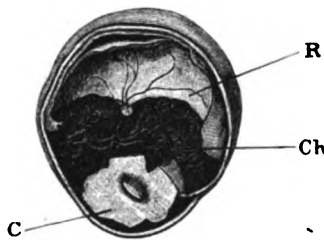

Posterior half of eyeball. (From a sketch by the author.)

visible, looking almost like the retina, except that it was more transparent, and not at all so uniform in appearance. On dividing the eye completely, being careful not to injure this membrane, I found that it lined the whole of the inner surface of the globe from the back of the lens in front to the optic nerve behind, and that it was a cyst. Although closely applied to the retina it was free everywhere except below, where it was firmly attached to the coats of the eye by a circular, depressed, scar-like area (Fig. 12, c).

The cyst wall lay also in contact with the posterior capsule of the lens, and there appeared to be no trace of vitreous humour.

On the inner surface of the lower half of the cyst were a number of minute, spherical, opaque white bodies.

Digitized by Google

varying in size, but none of them larger than a very small pin's head (Fig. 13). These were subsequently found to be brood capsules.* Except for its larger size, and the presence of these small white bodies, the texture of the cyst reminded me very forcibly of the subconjunctival cysticercus, the details of which I communicated to this Society some years ago.

A circular incision round the basal attachment, which is shown in Fig. 12, allowed the cyst to be removed, and when floated in water it was perfectly spherical (Fig. 13). After removal, the lower portion of the retina was seen to be deficient, the upper half being limited by two crescentic

FIG. 13.

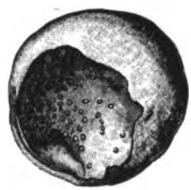

Echinococcus cyst, natural size, showing BROOD capsules in its interior. (Sketched while it was floating in water.)

margins on each side of the optic disc with their concavities downwards (Fig. 12, R). It seemed as if the lower half of the retina was adherent to the cyst, and had been torn away during its removal. But I never perceived any adhesion or tearing, and the cyst seemed to be quite free except at the one point mentioned above. Moreover, with the naked eye it was not possible to detect any indication of the torn edge of the retina on the cyst wall. It will be seen later that there was no adhesion between them. The optic nerve was white and atrophic. The lens was yellowish, but clear.

Microscopic examination.—Vertical meridional sections of the eye were very kindly prepared for me by Dr.

* According to Leuckart (*The Parasites of Man*, trans. by Hoyle, Edinburgh, 1886, p. 610) the brood capsules are always confined to certain portions of the cyst.

Digitized by Google

McWeeny, and many interesting points were thus brought to light.

The first and most important is that the cyst is sub-retinal, and not, as at first supposed, in the vitreous. It originated in the lower part of the eye, between the retina and choroid, at the point, most likely, where it is still attached to the choroid by a layer of inflammatory exudation and connective tissue. This is confirmed by the clinical history, according to which the defect in the vision began above. It then grew upwards and pushed the lower half of the retina before it, at the same time stretching and thinning it, so that the retina was doubled upon itself, the lower half being greatly atrophied and pressed against the upper half.

This is proved by the complete absence of any traces of the retina on the cyst after removal, neither is there any retinal tissue on the lower half of the eye, except in front of the attachment of the cyst. Furthermore, the free crescentic edge of the retina alluded to before (Fig. 12, R), instead of showing a torn margin, is smooth and rounded, and the folding of the membrane on itself is quite distinct. This is very well shown by the nuclear layers which are seen to curve round (Plate IX, fig. 2). Those belonging to the lower half of the retina can be traced upwards a short distance, but soon disappear as it becomes converted into a thin fibrous band in which traces of a nuclear layer spring up here and there. A similar band of degenerated retina passes out from below the cyst, in front of its attachment to the choroid, and can be followed forwards, and then upwards behind the posterior surface of the lens, so that the cyst did not actually come into contact with the lens, as appeared to be the case macroscopically, but was separated from it by the thin atrophied portion of the retina. The two portions of the retina are so closely pressed together that it is generally impossible to see the line of separation between them, except where indicated by traces of the internal limiting membrane (Plate IX, fig. 3).

Digitized by Google

Digitized by Google

PLATE IX.

Illustrates Mr. L. Werner's paper on a Case of Intra-ocular Echinococcus Cyst with Brood Capsules (p. 193).

FIG. 1.—Cyst adherent to choroid.

a. Parenchyma of cyst.
b. Hyaline laminated ectocyst.
c. Layer of connective tissue and exudation.
d. Choroid.
e. Sclerotic.

FIG. 2.—Free edge of retina, showing doubling back of nuclear layers.

FIG. 3.—Section of retina a few millimetres from free edge.

1. Degenerated lower half detached by the cyst.
   a. Remains of nuclear layers.
   b. Line of contact of internal limiting membrane.
2. Upper half of retina, which occupied its normal position.

Digitized by Google



FIG. 1.

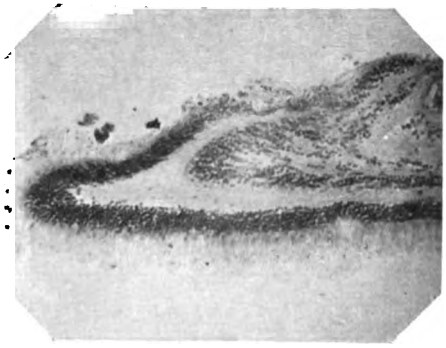

FIG. 2.

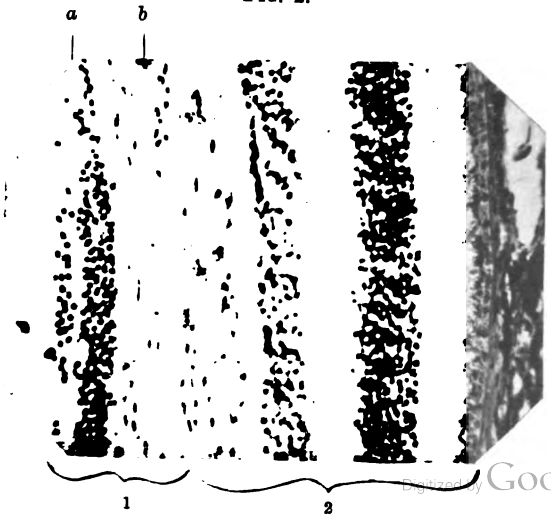

FIG. 3.

Digitized by Google

Digitized by Google

Digitized by Google

PLATE X.

Illustrates Mr. L. Werner's paper on a Case of Intra-ocular Echinococcus Cyst with Brood Capsules (p. 193).

FIG. 1.—Hyaline laminated ectocyst curved inwards. The outer surface is greatly wrinkled.

FIG. 2.—Ruptured brood-capsule, showing scolices, the majority with rostellum retracted. One can be seen above with rostellum and hooks evaginated, and the suckers on each side.

FIG. 3.—*a*. Section of cyst from Hill Griffith's case, showing an ectocyst only. *b*. Section from present case, showing granular parenchyma above the ectocyst. The lamination is not so well seen here.

FIGS. 4 and 5 show relative sizes of echinococcus head and hook from cysticercus.

Digitized by Google

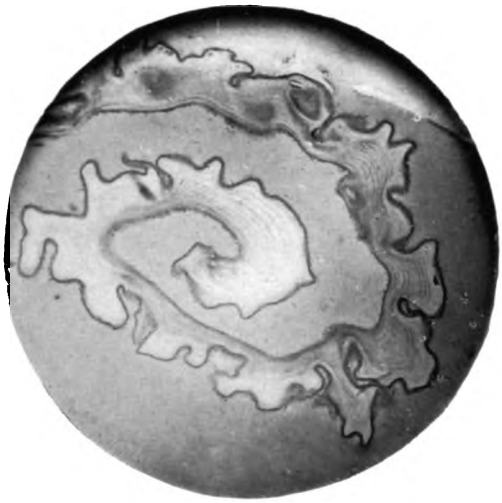

Fig. 1.

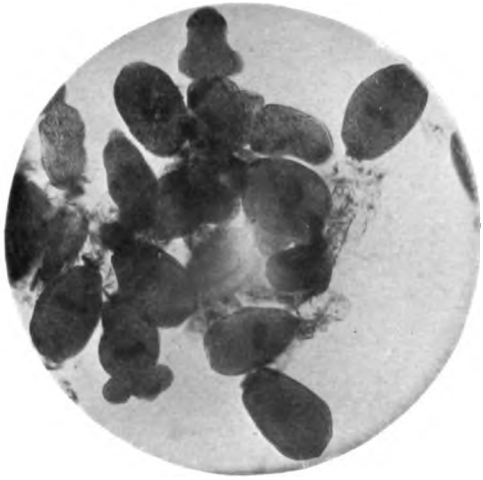

Fig. 2.

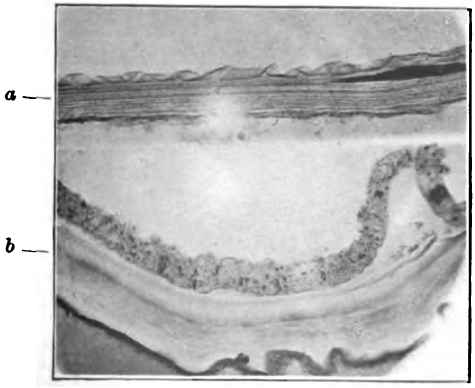

Fig. 3.

Fig. 4. Fig. 5.

Digitized by Google

Digitized by Google

The vitreous has completely disappeared. The ciliary region is flattened and atrophied. The iris is adherent to the periphery of the cornea, closing the angle of the anterior chamber and the upper portion is adherent to the lens near the pupillary margin. A large pear-shaped mass of uveal pigment projects into the pupillary area from above, being attached to the iris by a slender string of iris tissue. This was noted on clinical examination. The lens showed no evidence of cataract, but the lower half of the posterior surface is concave.

The cyst itself is a typical echinococcus. It consists of two layers—an outer, thick, homogeneous, and elastic, with a great tendency to curl inwards, and composed of numerous fine laminæ (Plate X, fig. 1), and on the inner or parenchymatous layer (endocyst) much more delicate, and composed of a finely granular substance containing many nuclei, but no outlines of any cells (Plate X, fig. 3, B). It is traversed by a fine network of stiff homogeneous cords (Leuckart, *loco citato*, p. 601), which are only seen in surface preparations.

The small white bodies seen on the inner surface of the cyst prove to be brood capsules, which arise from the parenchyma, and are connected with it by a narrow stalk. One slide shows them in an intact condition. In some of them I counted as many as fifteen echinococcus heads or scolices. Plate X, fig. 2, represents a capsule ruptured by pressure, with scolices set free. Some are retracted, the circle of hooklets being visible in their interior, while others are fully extended, and show their structure very beautifully, *viz.*, the rostellum with hooklets, four suckers, and below this a neck-like constriction. Each head is attached to the inner surface of the capsule by a small stalk which passes into its base. Heads in an early stage of development can be seen in most of the capsules. They form dark, deeply staining projections. In order to give an idea of the size of a scolex, the hook of a cysticercus has been placed by the side of one of them (Plate X, figs. 4 and 5).

Digitized by Google

Remarks.

Many cases of hydatid (Echinococcus) in the orbit have been recorded, and cases of intra-ocular cysticercus are not very rare, especially on the Continent, but only two cases have been described as intra-ocular hydatids. In order to make this paper complete, I have included them below. The first is a case of Hill Griffith's, contained in a paper published in these *Transactions*, vol. xvii, p. 220, under the title "Some Cases of Intra-ocular Cysticercus and one of Intra-ocular Hydatid."

Hill Griffith's case.

"The patient was a healthy little girl, three years and eight months old, who was brought to the out-patient department under my care, for what looked, on a casual examination, like some form of posterior polar cataract in the right eye. The sight was gone, the eye was free from injection, and the tension was normal. A closer examination showed a dense white glistening, opaque, non-vascular opacity in contact with the back of the clear lens. It did not present a concave surface like a posterior polar cataract, but was quite flat. No free edge could be made out in any direction even on wide dilatation of the pupil with atropine, nor was there any trace of fundus reflex to be seen at any part. Although the iris was not advanced, the opacity looked distinctly nearer to the cornea than an opacity behind the lens ought to do.

"When I saw the child in the hospital a few days later, after the use of atropine, glaucoma had taken place, the eye was injected and very painful, and the cornea slightly hazy.

"Dr. Little was now asked to see the case, and said it was undoubtedly a growth. I did not venture a contrary opinion, but on his advice enucleated the eye, and show naked-eye and microscopical preparations.

"The interior of the eye is lined by a dense continuous membrane closely adherent to the lens, ciliary body, and

Digitized by Google

retina, and occupying accurately the position of the hyaloid membrane. The lens is diminished in thickness at the expense of the posterior half, the posterior surface being almost quite flat,—a state of affairs which satisfactorily accounts for the undue proximity of the opacity to the cornea noted before excision. Microscopic sections of the entire globe in the horizontal plane show the choroid, retina, and other parts practically normal. The cyst wall is composed of numerous superimposed structureless lamellæ. Some of the most internal of these have in places become detached at the end, and curve inwards like a watch-spring, or the shavings of wood from a carpenter's plane."

The specimens were submitted to a Committee, whose report stated "that the shrunken vitreous, surrounded by a much wrinkled hyaloid, lay behind the posterior surface of the lens, which was concave. The cyst occupied the space left between the hyaloid and retina. The cyst wall was hyaline and laminated, and when compared with sections of an undoubted hydatid, they were found to be almost identical in appearance. No trace of endocyst, hooklets, or other contents were found, but the resemblance of the laminated membrane to the ectocyst of a true hydatid, and its dissimiliarity to any normal or pathological structure other than hydatid," lead the Committee to infer that, "in spite of the absence of more positive evidence, the specimen is one of intra-ocular hydatid cyst."

The second case is by Gescheidt, and is entitled "Echinococcus hominis zwischen Linse and Choroidea," and forms part of an article, "Die Entozooen des Auges," published so far back as 1833 in von Ammon's *Zeitschrift f. die Ophth.*, Bd. iii, p. 437. I obtained a copy of it from the library of this Society, and now give a literal translation.

Gescheidt's case.

"The patient was a youth æt. 24 years, an inmate of an asylum for the blind, who died of phthisis.

Digitized by Google

"When a child he suffered from severe ophthalmitis in both eyes, which had been at first neglected and led to incurable blindness, although the advice of several distinguished medical men was subsequently obtained.

"When I saw him two years ago, for the first time, the condition of the eyes was as follows:—the eyelids and the neighbouring parts were normal; the right eye was very prominent, and slightly staring; it was tense and hard; the sclerotic and cornea were normal, the iris was brown, and exhibited several spots of yellowish lymph-like exudation; the pupil was irregular, the upper segment of the lens was slightly clouded, and a very extensive dirty-yellow opacity was visible in the interior of the eye.

"The left eye, which was the same as the right as regards shape and tension, had a blue iris, on the surface of which small vessels were visible. The lens was cloudy and dislocated downwards, so that the upper portion only was visible in the dilated pupil, the remainder of which was filled with a yellowish-brown mass, distinguishable from the lens by its deeper colour.

"The examination of the eyes forty-eight hours after death gave the following results:—A transverse incision was made in the right eye with Daviel's scissors in order to divide the eye into an anterior and posterior segment, and when the incision was half an inch long a delicate white membrane, somewhat like the retina, was seen presenting itself between the divided sclerotic and choroid. But when the incision was completed without injury to the projecting membrane, and the posterior segment was drawn away from the anterior and bent a little backwards, the following very interesting condition was noted.

"The choroid was brownish in colour, deprived of pigment, and contained numerous varicose vessels. The retina and vitreous humour were united and compressed so as to form a white reddish-blue mass, which appeared like a string at the entrance of the optic nerve, but

Digitized by Google

anteriorly it increased in breadth, became thrown into folds, and was firmly united to the corona ciliaris and the ciliary processes. When the posterior segment was removed the combined vitreous and retina looked like the clapper of a bell. The space between the decolourised choroid and the clapper-like retina was occupied by a white bladder, the upper wall of which had presented in the incision. It was recognised to be an echinococcus. It started from the centre of the under surface of the folded and clapper-like retina, was bent around it, and filled up the space between it and the choroid in such a manner that its two bag-like ends met above. Its outer coat was white, slightly translucent, and pretty firm. When it was opened, a small quantity of serous fluid escaped, and revealed another bluish-white and more delicate membrane enclosed within the former. On opening this, some serous fluid also came away, carrying with it a number of small, round, oval, or olive-shaped worm-like bodies. In addition to those which escaped, others were visible on the inner surface of the thin membrane. Some of these, especially the oval ones, when examined under the microscope, showed undoubted small round suckers. Hooklets could not be found.

"No examination of the remaining portions of the eye was made, as the specimen was preserved in Prof. von Ammon's collection.

"The left eye was divided longitudinally with the following results:—When opened, a large quantity of moderately thick, yellowish-brown fluid escaped with small particles of detached pigment floating in it. The choroid was pale brown and devoid of pigment in front, but darker and partly covered with pigment in the neighbourhood of the nerve. The retina, vitreous humour, lens, etc., were gathered into a brownish-white mass behind the pupil. This mass, which was adherent to the uvea and contained a number of small blood-vessels, was united to the optic nerve by a slender string (the remains of the retina). The optic nerve itself was

Digitized by Google

very small. No parasite could be found either in the fluid which escaped or in any other part of the eye."

These cases of Gescheidt's and Griffith's are, as stated before, the only ones on record of intra ocular echinococcus, and both of them are considered to be doubtful.*

Davaine † (1877), it is true, states that three cases of hydatids in the deeper parts of the eye have been recorded, one being Gescheidt's alluded to above, and the others are by Portal (1803) and Rossi (1828). The last two observers merely make bare statements to the effect that they had seen intra-ocular hydatids *post mortem*; and Davaine says with reference to all three, "Dans aucun des cas la nature du corps observé n'a été bien determinée."

Professor von Zehender,‡ in the Bowman Lecture "On Parasitical Diseases of the Eye" (1886), does not seem to have been aware of Gescheidt's case, or else he also regarded it as doubtful, for he states that "the echinococcus has never been found in the eye itself, but only in the orbit."

The same remark applies to Hill Griffith (1897), who says in describing his case, "Hydatid cysts are occasionally found in the orbit causing proptosis, but, so far as I know, the case I am about to describe is the only example of such a cyst occurring in the eye itself.

Schöbl § (1897) gives a brief account of Gescheidt's case in Norris and Oliver's text-book, and in reference to it writes, "As this case was quite a clear one, and was exhaustively reported, I feel sure that it cannot be ignored, as has so far been done, for the mere reason that in recent times no similar case has been observed."

Kraemer,¶ on the other hand, in the last edition of Graefe

* In vol. xxi of these *Transactions* there is a paper entitled "A Case of Intra-ocular Hydatid;" but the term hydatid is used in a general sense, equivalent to bladderworm, the case being one of cysticercus.

† *Traité des Entozoaires*, 2nd ed., Paris, 1877, p. 826.

‡ These *Transactions*, vol. vii, p. 3.

§ *Diseases of the Eye*, Norris and Oliver, vol. iii, p. 573 (1897).

¶ Graefe and Saemisch, *Handbuch der Ges. Aug.*, 2nd ed., Bd. x, Cap. xviii, p. 2.

Digitized by Google

and Saemisch (1889), again asserts that "the echinococcus has never up to the present been seen with certainty in the interior of the eye," and he regards both of the above-mentioned cases as doubtful.

I think I have said enough to show that the occurrence of the echinococcus in the human eye has been looked upon by most, if not with positive disbelief, at least with considerable doubt.

Now in view of the positive evidence afforded by the specimen which I have been fortunate enough to secure, one at least of the causes of doubt is removed, and the study of the other cases can be approached in a different spirit from that which has hitherto prevailed.

I shall now discuss these cases, and shall begin with Hill Griffith's, as it is much more recent and easier to deal with than the other.

Mr. Griffith kindly sent me a section, and I have no doubt that it is an echinococcus cyst. It consisted of only one layer, which, however, exhibited the same fine lamination and peculiarities as the ectocyst in my case (Plate X, fig. 3, A). The absence of scolices or hooklets in his case was, of course, due to absence of the endocyst, which is not an uncommon condition,—in fact, the majority of human echinococci are sterile (Leuckart, *loco citato*, p. 585).

This case also differs from mine in that the cyst is in the vitreous, and the retina, which is normal, can be seen in the section occupying its normal position. The remaining parts of the eye are stated to have been normal, with the exception of the lens, which, as in my case, was more or less flattened on the posterior surface.

The clinical symptoms in the two cases were very similar. In both the cyst was visible as an opacity on the posterior surface of the clear lens, and appeared closer to the observer than a posterior polar cataract. There was no red reflex, and the eye was blind. In my case the tension was raised, and secondary glaucoma had set in. In the other tension was normal, but an attack of

Digitized by Google

glaucoma was induced by atropine, although the patient was only three years of age, showing that secondary glaucoma would in all probability have set in later on. In my cause the glaucomatous condition began about six months after the first symptoms had been noticed. The duration of the disease in the other case is not given.

It is much more difficult to arrive at a satisfactory decision with regard to Gescheidt's case. It may have been a true hydatid, but in spite of Schöbl's statement that it is a clear case, I cannot but look upon it as doubtful. Gescheidt was, no doubt, a competent observer, and made parasitic diseases of the eye a special study. That he found a bladderworm in this case is very probable, but that it was an echinococcus is not proved. He merely says that the cyst was recognised as an echinococcus, but does not mention how it was ascertained to be so, and at that time, in 1833 (not 1855, as given by Schöbl), the possibility of error was greater than it is now. In the fluid which escaped were some oval bodies which, he says, showed suckers but no hooklets. That the hooklets, which are the least destructible, should have disappeared, and that the suckers should have remained, is very improbable. He also states that similar bodies were visible on the inner surface of the thin membrane, and these could not have been scolices, which are invisible to the naked eye.

We must therefore conclude that only two cases of intraocular echinococcus have been observed with certainty, up to the present.

The salient features of the disease, as illustrated by these cases, may now be briefly stated. In both instances the cyst was simple—that is to say, it contained no daughter cysts as distinguished from brood capsules, and it completely filled up the eye behind the lens. One was situated in the vitreous, and the other between the retina and the choroid. Probably the difference in situation accounted for the sterility of the former, and the contact of the latter with the vascular choroid possibly led to a

Digitized by Google

better state of nutrition and promoted the development of brood capsules. In neither case was a connective-tissue capsule present, in this respect resembling an intra-ocular cysticercus. The lens was clear but flattened posteriorly. Secondary glaucoma occurred in both, in one instance induced by atropine. The tension in cases of cysticercus, on the other hand, is "normal or slightly diminished, seldom raised,"* and cysticercus generally leads to irido-choroiditis and phthisis bulbi.

The vision, no doubt, becomes affected in the same manner as in cysticercus cases. At first there is a defect in the field corresponding to the position of the cyst (as in my case). This gradually increases and finally ends in blindness.

The ophthalmoscopic appearance presented by a hydatid in an early stage can, of course, only be conjectured. That it would resemble a cysticercus is extremely probable; but no head or neck would be visible, and it would exhibit little or no movement, owing to the very feeble development of muscular fibres in the cyst wall and the thickness and rigidity of the cuticle (Leuckart, *loc. cit.*, p. 402). The hydatid is also much slower in its growth than the cysticercus.

As regards the mode of infection, it may be mentioned that, while the cysticercus can be caused by auto-infection, this is impossible in the case of the hydatid, since the *Tænia echinococcus* has never been seen in man. I was unable to ascertain how the disease was acquired in the case which I have described. The man never lived abroad; no dogs were kept in the house in which he lived; nor had he anything to do with dogs.

P.S.—I am indebted to my brother, Mr. A. Werner, for his valuable assistance in the preparation of the micro-photographs. Figs. 2, 4, and 5, Plate X, are from slides of my own; the remainder I owe to the kindness of Dr. McWeeny.—L. W. (*June 9th*, 1903.)

* Graefe and Saemisch, *Handb. d. Gesam. Augenheilkunde*, 2nd ed., Bd. x, Cap. xviii, p. 126.

Digitized by Google

X. COLOUR-BLINDNESS.

1. *The tests for colour-blindness.*

By F. W. Edridge-Green.

Dr. Edridge-Green gave a demonstration of his two tests for colour-blindness (lantern test and classification test), which are described in detail in his book on *Colour Blindness and Colour Perception*, International Scientific Series, Kegan Paul and Co.

1. *The lantern test.*—The apparatus of this test consists of a lantern and thirteen slides, seven slides containing coloured glasses and six containing modifying glasses. The slides are numbered as follows:—(1) standard red, A and B; (2) yellow; (3) pure green; (4) standard green; (5) blue; (6) purple; (7) ground glass; (8) ribbed glass; 9, 10, 11, and 12 are different thicknesses of neutral glass. I have not given separate numbers to the two reds, but called them 1 A and 1 B respectively. This I have done in order to show that the examinee is not expected to distinguish between them. They appear very similar to the normal-sighted, but when examined with the spectroscope it will be found that 1 B allows a number of green rays to pass, and it is therefore seen as green by those who have much shortening of the red end of the spectrum. These cases, when occurring without any other colour defect, are often passed as normal by the ordinary tests. The modifying glasses, besides preventing a colour-blind person from naming colours by their luminosity, in many cases change the colour of the light to the colour-blind whilst leaving it unaltered to the normal-

Digitized by Google

sighted. Every detail of the test is constructed from a knowledge of the facts of colour-blindness, and no colour-blind person has been able to avoid detection by this test, even when he had previously passed Holmgren's with ease.

2. *The classification test.*—This test consists of four test colours and 180 confusion colours: 150 wools, 10 skeins of silk, 10 pieces of cardboard, and 10 pieces of glass. The test colours are orange, violet, red, and blue-green. The whole series of colours is chosen with the view of presenting as much difficulty as possible to the colour-blind, and as little as possible to the normal-sighted. This test, like the lantern test, forces the examinee to use his colour perception and not judge colours by their luminosity. The classification test is neither essential nor perfect, as certain varieties of colour-blindness will escape detection by it. It is, however, very convenient, and enables the examiner to become thoroughly acquainted with the majority of the mistakes made by the colour-blind. In both these tests colour names are a necessity; the candidate is told to name the coloured light, and having named the test wool, is told to pick out the various coloured objects of that colour.

The CHAIRMAN (Mr. William Lang) said the meeting was indebted to Dr. Edridge-Green for a valuable demonstration. Holmgren's test, after all, appeared not to be sufficient.

Mr. W. ADAMS FROST asked what was the routine method of testing adopted by Dr. Edridge-Green. Did he begin by testing the candidates with the coloured wools and glass and cards? If they passed this, was it considered sufficient, or did he proceed to the lantern test in all cases?

Dr. EDRIDGE-GREEN replied that he commenced first with the wools, silks, cards, and glasses. A man who had only shortening of the red end of the spectrum might pass any other than the lantern test, and he might see six colours correctly in the spectrum. In that case he had practically normal colour-vision except the shortening of the red end. It was absolutely necessary to find out whether he had

Digitized by Google

that shortening. Shortening at the violet end of the spectrum was not a matter of much practical importance.

Mr. Adams Frost said he understood Dr. Edridge-Green to say that a man might pass the Holmgren test, and might even pass in Dr. Edridge-Green's wool and glass test, and yet fail in the lantern test. Such a man would be obviously unsafe to employ as a signalman, as he might mistake a red for a green glass. For years past the Society and the profession generally had been urging upon the Board of Trade and Railway Examining Boards the necessity of using the Holmgren test, and now it was stated that that test was not sufficient, and that men who could pass it might be totally unfit for signalmen. The matter was of the utmost importance, and it would be very desirable if Dr. Edridge-Green could bring forward a number of persons who fulfilled the alleged conditions, so that they could be investigated. Such persons could be examined by a small Committee of the Society, as it would be impossible to demonstrate them before a general meeting of the Society, and the Committee could report its findings to the Society.

Dr. Breuer thought Dr. Edridge-Green's test by itself did not justify any man being condemned as colour-blind. The matching of the colours in that test must be done mentally by the candidate. Any person who passed the Holmgren test with ease was not colour-blind, but not *vice versâ*. People were apt to confuse colour-blindness with colour-weakness, and Dr. Edridge-Green's test did not enable one to distinguish always colour-blindness and colour-weakness. His own opinion was that doubtful cases should be examined by several tests. There were a number of other tests. He did not see why Dr. Edridge-Green subdivided the spectrum into six colours in place of the three colours adopted by von Helmholtz, Hering, von Kries, Donders, etc. The ordinary three fundamental colours had always been regarded as red, green, and violet or blue. Another point was, Dr. Edridge-Green did not mention at what distance the

Digitized by Google

person should be from the lantern. The colour-blind person had a great difficulty in distinguishing small colour objects which were seen only by the macular area, the colour-weak person had difficulty in distinguishing large objects. He believed Dr. Edridge-Green's test was of great practical use, but it was untrustworthy alone; it must be taken in conjunction with Holmgren's test.

Dr. EDRIDGE-GREEN, in reply, said he would be pleased to bring some of the subjects whose red end of the spectrum was deficient before the Society, and it would be a great point if Sir William Ramsay would consent to be examined by the proposed sub-committee. He showed a man having colour-vision similar to that of Sir William Ramsay before the Society about a year ago. He failed entirely to discern yellow and blue as distinct colours. Such cases he termed trichromic. In answer to Dr. Breuer's remarks, he maintained that his (Dr. Edridge-Green's) was an absolutely trustworthy test, and it would have been more satisfactory if Mr. Breuer had supported his statement by any cases. Wherever his test had been employed it had succeeded in detecting every case of colour-blindness. There were six varieties which might escape detection by Holmgren's test. With regard to his mentioning six colours instead of three, the trichromic persons saw three definite principal colours in the spectrum just as Sir William Ramsay did, who saw red, green, and violet, but no orange, no yellow, and no blue. When the person examined continually confused these colours with others, *i. e.*, he did not see yellow or blue, there was a definite defect which it was necessary should be detected, for such a person could not possibly be employed safely on a railway or at sea. At sea he confused the mast-head light with the sidelights. In testing he had confirmed the results obtained by means of the spectroscope, and that examination gave a perfect key to the colour-vision of any person. Holmgren's test would not detect those who only saw three colours in the spectrum—red, green, and violet. Mr. Breuer's statement

Digitized by Google

that those who failed with Holmgren's test were undoubtedly colour-blind, was not true. On many occasions he had men before him of perfectly normal colour-sight who had been rejected by the Holmgren test. In answer to Mr. Silcock, the same pigment was used in both glasses, but the intensity varied. Both were cut out of the same piece of glass, and therefore either might be equally used at sea or on the railway. He thought it likely that Members of the Society having all the facts before them might be able to design some more simple contrivance than that which he had shown, and that was why he had not brought the tests themselves more prominently before the Society; what he had been working at for years were the facts relative to colour-vision, and he based his tests on the knowledge of those facts. The test he had brought forward was absolutely practical, and had no relation to theory at all.

The CHAIRMAN (Mr. William Lang) said the matter would arise again shortly, as the Council would no doubt appoint a Committee of Investigation.

---

2. *On the necessity for the use of colour names in a test for colour-blindness.*

By F. W. EDRIDGE-GREEN.

THERE is no fact which can be more easily demonstrated than the absolute necessity for the use of colour names in a test for colour-blindness. Such, however, is the influence of authority, that it is exceedingly difficult to convince men who have held the opposite opinion without giving them a practical demonstration.

The first requirement of a test for colour-blindness is that colour names be used, and that the person to be

Digitized by Google

examined should employ and understand the use of the colour names, red, yellow, green, and blue. I can say in the most emphatic manner that no test which ignores colour names can be efficient. I predicted that if colour names were ignored in the Board of Trade tests, normal-sighted persons would be rejected, and this prediction was fulfilled. Over 38 per cent. one year and more than 42 per cent. another year of those who appealed were found to be normal-sighted and to have been rejected wrongly.

Nothing shows the value of colour names better than an examination with my lantern of an educated colour-blind man who has just passed Holmgren's test with the greatest ease. He miscalls red, green; and green, red; and applies either term to yellow, thus not only proving his colour-blindness, but showing how absolutely unfit he is to act as an engine-driver or a look-out. It also proves to the colour-blind person himself that he is colour-blind, because he can be allowed to take out the red glass which he has called green and examine it. I have examined many persons who would not believe that they were colour-blind, and remarked their horror when the conviction that they were became forced upon them. An engine-driver or sailor has to name a coloured light when he sees it, not to match it. He has to say to himself, "This is a red light, therefore there is danger," and this is practically the same as if he had made the observation out loud.

In order to show how normal-sighted persons are rejected by ignoring colour names I will relate the following case:—A man was sent to me as colour-blind. On examining him I found that he was normal-sighted. I then examined him with Holmgren's test, carefully adhering to the directions. He put several confusion colours with the test green but no greens. In answer to my inquiry he said they were all of the same colour. I then said, "Are they all greens?" He replied, "No; they are not. That is a purple brown, that is a grey, and that is a

Digitized by Google

yellow. You did not tell me to put only greens with the wool you gave me; you said, 'Pick out all of the same shade or colour.'" Several artists have remarked to me that they pay far more attention to shade than colour, and that the confusion colours were more like the test green than those which are supposed to be picked out by normal-sighted persons. A very simple illustration may serve to make my point quite clear. Let it be supposed that I wish a man or a child to separate a roomful of people into men and women. I take him to the room and say, "Now I want you to separate these persons. I want you to put all who look alike in one class and the remainder in another." When I return I find that he has put all the big people in one class and all the small people in the other. If I then say, "You have classified them wrongly; I wanted you to put the men in one class and the women in the other," he could reply, "Why did you not tell me that you wanted me to separate them into men and women?"

The method of matching colours should, in order to be efficient, be one of mentally naming them. For instance, if a man say to himself, "This test colour is green, therefore I must pick out all the colours having this hue of green in them," he will go through the test as it should be gone through; but if on looking at the wool he be more influenced by shade, he will put light blues, yellows, greys, and browns with the green. This will be especially liable to happen in cases of the lesser degrees of colour-blindness, in which the green is simply enlarged and encroaches on the yellow and blue. In my classification test I use coloured materials of different kinds, as similarity, other than that defined by the word "colour," is the great source of error in a test of this kind, and it is exaggerated by ignoring names.

In all my tests for colour-blindness I first make certain that the examinee understands what is meant by colour. I then make him name a colour. It is not necessary that the colour names used be those used by me; any name will

Digitized by Google

do. The essential point is that colour-blindness is shown by a person including two colours of the normal-sighted under one name. For instance, in testing with the spectrum, I show the examinee a portion of the red end of the spectrum and ask him to name the colour. Nearly all, whether colour-blind or normal-sighted, will reply, "Red." The examinee is then asked to find the first point where there is a definite change of colour, and to name the second colour. The normal-sighted will put the pointer between the red and orange. The pentachromic and tetrachromic will put the pointer nearer the green and call the colour yellow. The junction will be nearer the green in the case of the tetrachromic than in the pentachromic. The trichromic will put the pointer in the yellow and call the colour green, and the dichromic will put it in the centre of the green and call the colour blue. I should like to have given a practical demonstration with different cases of colour-blindness, which would have shown how accurately the method of naming colours corresponds to the spectral examination. I will briefly refer to the different varieties of colour-blindness, because the facts of colour-blindness are so inaccurately stated in the text-books. The facts are not given as they really are, but as they ought to be according to some theory.

The colour-blind may be divided into two distinct classes which are independent of each other, but which may be associated. The first class includes those who are not able to see certain rays of the spectrum; their spectrum is shortened at one or both ends. If a man have shortening of the red end of the spectrum, he will not be able to see a red light at a distance, though he might be able to pick out all the green wools in the classification test. A man of this kind when shown the red light of my lantern test declares that there is no light visible, at once demonstrating his incapacity. The second class of the colour-blind make mistakes not because they cannot perceive a certain colour, but because they are not able to recognise the difference between the colours which is

Digitized by Google

evident to normal-sighted persons. Both these classes are represented by analogous conditions in the perception of sounds. The first class of the colour-blind is represented by those who are unable to hear very high or very low notes; that is to say, those notes are non-existent to them. The second class is represented by those who possess what is commonly called a defective musical ear. Normal-sighted persons see six definite colours (points of difference) in the spectrum. The second class of the colour-blind see five, four, three, two, or one colour, according to the degree of the defect; and they confuse the colours of the normal-sighted which are included in one of their own. If the normal-sighted be designated hexachromic, those who see five colours may be called pentachromic, those who see four tetrachromic, those who see three trichromic, those who see two dichromic, and the totally colour-blind monochromic. The degree of the defect will be recognised by the names given to different colours. The pentachromic will miscall orange. The tetrachromic will in addition make mistakes with regard to blue. It is not necessary to reject either of these two varieties, because I have never succeeded in making them confuse the colours red, yellow, green, and violet. The trichromic are always in difficulty over yellow and miscall it red, green, or red-green, and for practical purposes must be excluded as colour-blind. The dichromic confuse red, orange, red, and yellow-green on the one hand, blue-green, blue, and violet, on the other.

(*November 14th*, 1902.)

Mr. C. DEVEREUX MARSHALL said Dr. Edridge-Green had made out a very clear case in favour of his views of colour-vision, and also for the using of names when testing subjects for the condition. It was true an engine-driver or ship's look-out did not require to match colours at night; but on a pitch-dark night, in a thick atmosphere, the look-out had to see a dull red light or a green light in the distance, which, perhaps, if the observer's spectrum was

Digitized by Google

shortened on the red side, he would not see. Such cases must inevitably cause disaster, and must in all probability account for a large number of the shipping accidents with which one was so familiar. He had seen, with Dr. Edridge-Green, a patient who had a shortened red end of the spectrum, and it was remarkable how, when one looked down at the end of an otherwise darkened room and saw a dull red light at the other end of it, he could declare there was no light there at all. Yet those were the conditions under which his colour-vision would probably be required at sea and on the railway. He thought everyone was agreed how unsatisfactory Holmgren's test was in the usual way. Very many people were rejected through it when used in the ordinary way who ought not to be rejected. Dr. Edridge-Green's lantern test was so much better that he (Mr. Marshall) could not think why the authorities, such as the Board of Trade, did not use more satisfactory methods for testing their people, considering the enormous importance of having a clear investigation with regard to the men who were colour-blind, and those who had normal acuteness of colour-vision.

After some remarks by Mr. Holmes Spicer, Dr. Edridge-Green replied to the discussion.

Digitized by Google

XI. PATHOLOGICAL ANATOMY.

1. *Case of early formation of true bone in a shrivelled stump.*

By Leslie Buchanan, M.D.

Robert I—, æt. 17 years, a healthy-looking boy, came to Charlotte Street Infirmary with a purulent wound at the lower part of the right cornea, the result of a blow from a chip of coal three days before. The cornea was hazy all over, and the iris could be seen only with some difficulty. There was exudation of puro-lymph in the anterior chamber, and the lens was swollen and pressing forwards. Two days later there was panophthalmitis. The eye was opened anteriorly and the pus evacuated. The stump shrivelled down quietly, and as the lad desired to wear an artificial eye as soon as possible, it was removed just ten weeks after the receipt of the injury.

When the eye was bisected, it was found that there were some gritty particles in its central part. Histological examination showed that all the structures in the eye had been destroyed by inflammatory action, and that the shrivelled stump was filled with fibro-cellular tissue, which was the result of this process. In the midst of this newly-formed tissue, and near the remains of the ciliary body, there was a moderately large mass of fairly well-formed bony structure of very irregular shape, and surrounded by fibro-cellular tissue, some of the connective-tissue cells being arranged in a row round parts of it. Besides this, other centres of ossification of smaller size were found in a state of early development.

Remarks.—The interesting feature in this case is the early formation of bone. There can be absolutely no doubt but that the bone in this case was formed within six or eight

Digitized by Google

weeks, as suppuration only ceased within that time, and as the eye was undoubtedly good before the date of injury.

Of some sixty cases in which ossification of inflammatory exudation had taken place, the earliest was about eight years. (*July 3rd*, 1903.)

2. *Ossification of the choroid.*

By Thos. Snowball, M.B.

[From the Pathological Laboratory, Royal London Ophthalmic Hospital.]

The presence of bone in the eye is a not infrequent occurrence, and has long been recognised and often described. The frequency with which ossification occurs in the various structures is, however, not the same, for while in some parts it is rare, in others it is comparatively common. Amongst the latter the uveal tract takes the first place, and of it the choroid is the part that is generally regarded as the *locus prædilectionis* for this pathological formation. Yet observers are not all agreed as to the site and mode of formation of bone in the choroid, or while some regard the capillary layer as the exclusive or most frequent seat of its origin, others hold the opinion that the bone is laid down most often internal to the membrane of Bruch, and may here arise in different ways. The object of this paper is to give an account of the microscopical examination of several eyes in which this pathological process had taken place, and to compare the results with the conclusions arrived at by other observers. The following is a description of my cases:

Case 1 is that of a man, æt. 26 years, who had lost the sight of his left eye sixteen years previously through a blow with a stone, and seven weeks previous to enucle-

Digitized by Google

ation the same eye again received an injury, after which it continued painful. Right eye normal.

Macroscopically.—The iris has a broad attachment to the back of the cornea at the site of the old cicatrix. The lens is almost entirely absent; a transverse band of fibrous tissue occupies its place, or is closely adherent to the remains of it or its capsule; this fibrous tissue is also adherent posteriorly to the substance of the retina, which is detached from the optic disc to the ora serrata. On the choroid round the entrance of the optic nerve is a thin, greyish layer, which extends as far as the equator on one side of the optic nerve, and on the other for a distance of 3 mm. from it.

Microscopically.—The posterior part of the choroid, showing this greyish layer that contains the bone, consists of two parts: (1) an outer layer, comprising the supra-choroidea and choroidal stroma, and (2) an inner layer, made up of fibrous tissue, in which the formation of bone is seen. The stroma proper is fibrous in texture throughout, and on its inner side merges into the more uniformly fibrous layer that encloses the bony mass; the layer of large vessels is represented by only a few vessels, which exhibit distinct thickening of their walls with diminution of their calibre. The stroma-pigment cells are irregularly distributed and mostly degenerated. The chorio-capillaris has to a large extent disappeared, but it is evidently represented by large, congested, capillary vessels seen at intervals towards the outer border of the fibrous layer; but other small, new-formed capillaries, the walls of which are composed of a single layer of endothelial cells with definite elongated nucleus, are seen in the outer layers of the stroma, and especially among the fibres of the fibrous layer next the bone. Leucocytes are scattered through the outer layers, or even form a mass occupying the whole thickness of the choroid. Red blood-corpuscles are also scattered throughout the choroid, or form masses in its inner layers or immediately round the great vessels. There is no trace of Bruch's membrane external to the bony layer. The thin fibrous tissue layer lining the bony plate

Digitized by Google

on its outer surface is composed of bundles of fibres with elongated nuclei. Here and there these fibres are directly continuous with the end of a developing bone-trabecula, showing in parts a more homogeneous or slightly granular appearance. In some places pigment cells, evidently altered pigment-stroma cells, lie singly or in small clumps among the fibres; in other places there are small, well-defined, rounded bodies of a uniformly granular appearance, which stain purple with logwood and in some cases are surrounded by rounded pigment granules. The fibrous layer that lines the inner border of the ossified plate is entirely devoid of a retinal epithelium covering on its internal free surface except opposite one end of the bone; only a few blood-corpuscles and degenerated epithelium cells are attached to the surface. A few capillaries are seen here and there in this layer. Its inner part is composed of richly nucleated fibres, while the outer, next the bone, has become more homogeneous or finely fibrillated or granular in appearance. The retinal epithelium is, as I have said, present opposite one end of the bone, but is degenerated; under it the lamina vitrea is seen to run for a short distance internal to the bone (separated from it by some fibrous tissue), and to disappear in a small mass of homogeneous or osteoid tissue lying next the bone. This membrane is easily traceable beyond this end of the bone, but opposite the rest of the bone it is absent altogether. The bony mass forms a long narrow band of irregular outline, and contains several spaces in its substance, similar spaces being made by its trabeculæ with the help of the adjacent fibrous layers; these spaces are filled with cells, which by their processes form an open delicate meshwork that carries the capillaries of the space; in several spaces small round-cells are seen in the meshes in varying numbers. The walls of these cavities are paved with a continuous line of cells which contain large nuclei—the osteoblasts. The latter, as they come to lie deeper in the osseous tissue, become more and more angular,

Digitized by Google

assuming the form of true bone-corpuscles. Some of the trabeculæ and both ends of the bone-plate merge into richly nucleated fibrous tissue. The bone shows typical lacunæ and canaliculi with their bone-corpuscles, but fully developed Haversian systems are seen only here and there. Several well-defined rounded bodies are seen intimately connected with the bone, either lying in cups formed by it, or situated at one end of the bony plate. They show a few pigment granules lying in or on them; the ossifying process appears to be growing round them. Similar smaller bodies are seen in the substance of the bone. Beyond the bone-containing area the choroid shows marked degenerative atrophic changes after an old inflammation; the vessels have either disappeared, or, where the large vessels remain, the capillary layer is replaced by fibrous tissue. Farther forward the evidences of an inflammatory process are in places very slight; on its inner surface are small colloid bodies. There are signs of a chronic inflammation in the iris, ciliary body, and in the presence of a cyclitic membrane; and the retina has been converted into a fibro-cellular mass.

Case 2 is a blind shrunken eye that was removed from a man, æt. 22 years; no further history was obtainable. On section the eye shows adhesion of the iris to the back of the cornea; in the situation of the lens there is a thick mass of fibrous tissue that is in close connection with the iris and retina; the retina is completely detached except at the optic disc; slight detachment of the anterior part of the choroid; folding of the sclerotic behind the insertion of the recti muscles, and thickening of its posterior half.

Microscopically.—The bone on the inner surface of the choroid forms a collar round the entrance of the optic nerve, and extends for a short distance along the side of the retina at the point of its attachment at the optic disc. The choroid around the optic nerve entrance, corresponding to the area of ossification, presents features very similar to those described in Case 1, *viz.*, a finely fibrous stroma,

Digitized by Google

deeply pigmented next the sclerotic, only a few vessels in Haller's layer showing thickening of their coats, the fibrous stroma passing into a fine fibrous tissue that contains only a few small vessels and capillaries and lines the outer surface of the bone-plate; there is no continuous chorio-capillaris, and the vitreous lamina is absent. Numbers of large unpigmented cells, and small mostly uninucleated cells, are scattered through the choroid; and small hæmorrhages are seen in this inner fibrous layer, which is richly nucleated (the nuclei being large, and oval or spindle-shaped), as well as round some of the large vessels. A layer of dense fibrous tissue covers the bone-plate on its inner surface; it contains a few capillaries here and there, and on its free surface carries a few degenerated retinal pigment cells. The bone is similar in structure to that in Case 1, showing a beautiful lamellated formation, and a lining of osteoblastic cells round some of its medullary spaces. The process of ossification has extended along the retinal column on one side, and here the ends of the bone are surrounded by a cap of modified fibrous tissue which passes into bone that is coarsely granular and stains deeply with logwood. This coarsely granular bone, again, merges into the clearer more fully developed bone. About the equator on one side of the globe, at a point where the sclerotic forms a fold and the degenerated retina has remained attached to the choroid, a small focus of bone has developed in a layer of fibrous tissue that unites the choroid and retina together; the choroid is here atrophic, and shows only a few small vessels and capillaries that are partially hidden by bands of retinal pigment. The membrane of Bruch is not visible at this point.

The cornea shows well-marked calcareous degeneration in its anterior layers; Descemet's membrane has grown over part of the anterior surface of the iris, and the posterior endothelium of the cornea accompanies the hyaline membrane for some distance over it. A thick cyclitic membrane replaces the lens which is absent; it contains a small mass of true bone in its substance. This membrane has

Digitized by Google

largely undergone hyaline degeneration. The retina is degenerated, contains several cysts and masses of calcareous deposit, and its vessels exhibit colloid thickening of their walls.

Case 3.—This eye was taken from a woman, æt. 21 years, who had lost the sight of it since she was 9 years old; she thought she had had a "cold" in it and that the doctor burned it. The eye is shrunken. It shows an adherent leucoma with total absence of lens and a funnel-shaped detachment of the retina. A plate of bone, $1\frac{1}{2}-2$ mm. thick at its thickest part, lines the whole of the inner surface of the choroid except immediately round the entrance of the optic nerve; and even this latter area is not entirely free from the formation of bone.

On microscopical examination, the choroid around the optic nerve is found to exhibit only slight alteration in the appearance of its different layers, which are all present. The pigmented stroma cells have proliferated and spread largely into the inner layers; some of the large vessels have thickened walls; the lamina vitrea is much thickened and finely fibrillated; the retinal epithelium is degenerated, but in places has disappeared. At one point in this area a small focus of bone at a very early stage is seen lying in the region of the chorio-capillaris and replacing it, and immediately external to the membrane of Bruch. This focus consists of a small spindle-shaped mass of a homogeneous or finely granular appearance, in the centre of which is a small more coarsely granular spot that stains purple with logwood; and in this spot several cells are seen taking on the angular shape of bone-corpuscles. The outer border of this focus is lined by one or two strands of fibrous tissue, the cells of which have spindle-shaped nuclei; but those cells which lie next this homogeneous or osteoid mass are becoming more and more angular the farther into its substance they go. Both ends of the focus are studded with large oval cells; those next the new bone, again, assuming an angular form. A fine dark

Digitized by Google

line separates the mass from the membrane of Bruch on its inner side. The fibrous tissue lining the new bone replaces the chorio-capillaris for a short distance at either end of it. In other sections through the same spot we see what is apparently a still earlier stage of the process, *viz.*, a small mass of large oval cells taking the place of the chorio-capillaris just external to the lamina vitrea; some of these cells are elongating into fibres, while others are becoming angular in form where the tissue is becoming more homogeneous. In a neighbouring section, again, the bone has assumed greater dimensions, is more fully developed, and shows its outer border paved by a continuous layer of cells. Another *plaque* of bone lying in the choroid just at the end of the detached retina also replaces the chorio-capillaris, and is bordered externally by the deeply pigmented stroma.

The choroid opposite the large mass of bone is detached from the sclerotic on both sides, and shows degenerative changes (breaking down of the pigment-stroma cells, fibrous stroma, few vessels either of Haller's or the capillary layer, absence of Bruch's membrane). The bone has developed in parts immediately on the inner surface of the pigmented stroma, in parts separated from it by a layer of fibrous tissue in which a number of rounded bodies is seen. These bodies vary in size; they have a granular appearance and stain purple with logwood, usually most deeply in their centre; they lie loose in the tissue or are attached to the growing bone. Fibrous tissue also lines the inner surface of the bone and fills up the bays in it. At the posterior end of the bone, on one side of the disc, this tissue has become homogeneous, and is covered by a layer of retinal pigment. (The inner layers of this homogeneous tissue just under the retinal pigment evidently consist of Bruch's membrane, although in parts it is hardly possible to distinguish this membrane from the homogeneous tissue.) Elsewhere, however, the retinal pigment layer is for the most part absent. The bone-plate extends on one side beyond the

Digitized by Google

choroid along the inner surface of the ciliary body, and for some distance along the back of the detached retina. It contains large spaces that are filled with a fine cellular meshwork and large capillaries; the lamellar structure round the spaces is prettily shown. The fibrous mass that takes the place of the lens also contains a small mass of bone. The retina is detached and degenerated, and the walls of its vessels exhibit colloid thickening. A large mass of calcareous deposit is seen in its substance, and along its free surface tiny plates of bone are developing in a vascular fibro-cellular tissue; at the optic nerve end of the retinal stalk one also finds one or two pieces of bone.

Case 4 is the left eye of a woman, æt. 22 years, who when 2½ years old fell and ran a fork into it. The globe is shrunken and shows a transverse calcareous film of cornea, and when cut equatorially shows in its posterior half a great thickening of the sclerotic on one side (adjoining which is a yellowish mass, chiefly made up of degenerated detached retina), and on the other side a smaller mass of similar colour that contains bone; at the posterior pole is a greyish patch and a number of tiny white dots which stand out prominently against the brown colour of the rest of the fundus. These white dots are foci of bone-formation, which in transverse sections are seen to take the form of elongated trabeculæ, or small rounded masses, lying in fibrous tissue developed in the inner layers of the choroid, or independently in colloid bodies lying on its inner surface. The retina has become detached from the choroid over this area. The choroid itself here shows in parts little alteration from its normal structure, its various layers being preserved, and it is lined almost continuously by the retinal pigment layer; in parts it is altered by chronic inflammatory processes, the chorio-capillaris being in places absent and replaced by fibrous tissue, and the membrane of Bruch where present having a finely fibrillated appearance.

Digitized by Google

Colloid bodies are also seen under the retinal epithelium. These colloid bodies vary in size and shape, some being small, others large and lobulated, some rounded in form, and others more or less flattened. In one or two of the larger ones the process of ossification is going on. The granular substance of the colloid body itself is in greater part replaced by a mass of developing bone, together with a delicate fibrous meshwork containing small capillaries and numerous large rounded or oval cells, that in places lie thickly set against the granular substance. Besides these, one or two very large multinucleated cells are seen lying close to the remaining substance of the colloid body. The bone itself is not fully developed, but the centre of it is already impregnated with lime salts, and shows the bone-corpuscles lying in their lacunæ; the rest of the mass shows a granular or faintly fibrillated appearance, with a few cells scattered through it that are assuming an angular form. The retinal epithelium, mostly non-pigmented, usually remains as an internal covering to the ossified colloid body, but here and there the cells are absent. In other colloid bodies the bone is growing on their external surface, a sharp line dividing the two at the part where the body seems to have undergone calcification; where the body has not become calcareous its substance is apparently being replaced by the fibrous tissue with which the end of the bone is closely intimate; again, an island of this granular substance may be left in the middle of this fibrous tissue, and, as the bone extends, is surrounded and enclosed by it. In the case of some of the flattened colloid bodies, the fibrous tissue that in parts replaces the chorio-capillaris is seen pushing its way into them and replacing their substance; others, again, are almost completely scooped out and filled with fine connective tissue without any appearance of bone. Where the bone forms an elongated plate in fibrous tissue laid down to large extent in the capillary layer of the choroid, independently of, and in a more advanced state of development than, the

Digitized by Google

ossification of the colloid bodies, the appearances are very similar to those described in Cases 1 and 2. The bone is in places quite close to the pigmented stroma and the large vessels. The retinal pigment is absent in places, and where Bruch's membrane is present under it, the bone with its fibrous envelope lies distinctly external to the vitreous lamina. Bone also appears in *plaques*, where the retina and choroid remain in contact with each other, either in the fibrous outer layers of the retina or in the fibrous layer that has formed between the two coats. The retina, as has been stated before, is partially detached and is degenerated; its vessels show marked fibrous thickening of the walls, which have in places undergone colloid degeneration.

Case 5 is the eye of a girl, æt. 13 years, which had been twice inflamed, once when she was a baby, and again at the age of 7 years. The globe is now much shrunken; the cornea is depressed and thickened, and the remains of the iris and ciliary body are seen lying close to it; the sclerotic is folded and much thickened, and the vitreous cavity contains a large mass of bone. Only a small *plaque* of bone has developed in the choroid itself. This coat is for the most part detached from the sclerotic; it shows more or less extensive atrophic changes subsequent to a chronic inflammation; its inner layers, chorio-capillaris and lamina vitrea, have to a large extent been replaced by fibrous tissue, in which the bone has formed. This layer of fibrous tissue is really only the outer part of a broad fibrous layer by which the choroid is united with the degenerated retina, and through which the retinal pigment has proliferated in the form of bands or hollow cylinders; at one point in its inner layers (which may possibly be really the outer layers of the retina) a tiny focus of bone is seen. Bone and fibrous tissue fill up the space between the retina and the back of the cornea, the fibrous tissue coming partly from exudation from the ciliary body, partly from the retina

Digitized by Google

(into which the bone in places extends), partly perhaps from changes in the vitreous. The cornea shows patches of calcareous degeneration.

Case 6 is the small portion of a globe, the history of which is unknown. Two small masses of bone are seen on the inner surface of the choroid. The retina is not present. The choroid shows signs of a chronic plastic inflammation, the atrophied stroma having on its inner surface a layer of wavy fibrous tissue, in the centre of which the bone has developed. Capillaries are seen here and there on the outer border of this fibrous layer as well as in its substance; and several ill-defined granular masses (which stain purple with log-wood), as well as some clumps of pigment near to or separate from them, are seen in this tissue external to the bone. In places the bone lies close to the large vessels in the pigmented stroma. There is no lining of retinal pigment internal to this fibrous layer. Beyond the bone the fibrous tissue is developed, partly replacing the chorio-capillaris, partly between it and the membrane of Bruch and retinal pigment. The bone itself in its inner layers is seen in the form of irregular trabeculæ which lie parallel to the free surface and enclose slit-like spaces, while in its outer part it shows more or less rounded canals surrounded by lamellated bone substance (one or two lamellæ lying round each canal).

Case 7.—Case of buphthalmos taken from a man æt. 28 years; the eye was first affected, when he was 5 years old, after measles; this destroyed the sight; pain and inflammation began, and continued for five months previous to excision. Other eye is normal.

Microscopically.—The choroid is almost entirely detached from the sclerotic. It is very much disorganised, being represented by a pigmented fibrous layer which contains here and there small blood-vessels or much hæmorrhage between its fibres. Internal to this is a shell of bone of very open cancellous structure; it shows

Digitized by Google

most beautifully the open cellular meshwork that fills up the spaces between the trabeculæ. The shell has a thin compact layer of bone on its outer and inner surfaces with the cancellous tissue between them; it is thus comparable with the structure of the cranial bones. The bone extends forwards into the cyclitic membrane that surrounds the calcareous lens. Internal to the bone-shell lies a large mass of fibrous tissue that contains a considerable amount of choroidal stroma pigment. No membrane of Bruch is seen. The layer of retinal pigment lies in front of this, and next to it the degenerated retina, which is partially detached from the choroid. Bone is present as small foci in the calcareous lens (the partially ossified fibrous tissue surrounding it can also be seen between the anterior capsule and the lens substance) and in the degenerated retina. The iris is completely bound down to the fibrous tissue behind it; the sclerotic is folded and much thickened posteriorly.

Remarks.—The cases I have here described are all old blind shrunken eyes taken from patients of both sexes, the average age of whom was 22 years, the youngest being a girl 13 years old. The period that elapsed between the onset of the inflammation and the enucleation of the eye was in all the cases very considerable, averaging fifteen years. From a general review of the literature on this subject it is found that the condition of ossification of the choroid occurs at all ages from childhood (11 years) up to extreme old age (102 years). The time required for the growth of the bone is in most cases at least several years, yet it is worthy of mention that Schiess-Gemuseus (34) records a case in which bone was found in the choroid of an eye that had been normally functional only ten months before; and although, on the whole, more cases are recorded as occurring in males, the question of sex is probably of no etiological moment in the production of this condition.

In six of the above cases a perforating injury of the

Digitized by Google

eye or an inflammation of the cornea followed by perforation occurred four times, and an inflammation of the eye without perforation twice. This set up in various parts, and especially in the uveal tract, a chronic inflammation with plastic exudation which ultimately led to more or less extensive degenerative changes in the parts affected. In each case the remaining eye is described as normal; no mention is made of the presence of sympathetic disease in it.

As a result of this chronic plastic inflammation in the choroid, the outer pigmented layers are reduced to a fibrous band containing much fewer large vessels, which exhibit more or less marked fibrous thickening of their walls; the inner layers, *viz.*, the chorio-capillaris and membrane of Bruch, on the other hand, are for the greater part absent in those areas where bone develops in the layer of fibrous tissue which has become organised from exudation thrown out towards the inner surface of the choroid. In these areas the capillary layer, where it is still present, is never a continuous one, but at most is represented by only a few vessels that lie along with other new-formed capillaries in a layer of fine fibrous tissue, where fibrous tissue remains between the plate of bone formed in it and the outer atrophic pigmented stroma. The membrane of Bruch, however, has disappeared altogether in these parts, and here the exudation had been greatest and the inflammatory process presumably most intense. In none of the cases do we find this homogeneous membrane lying on the choroidal side of the bone-containing fibrous layer. Where it is still present near the bone, *viz.*, close to the end of the expanding plate, as in Cases 1 and 3, or contiguous to the focus of early ossification in Case 3, the membrane of Bruch lies *internal* to the bone, the latter taking the place of the chorio-capillaris (or the layer of small vessels, Sattler's layer, as well), and either lying immediately between the vitreous lamina and the choroidal stroma, or separated from them by a layer of fibrous tissue. The bone, therefore, develops in fibrous tissue that replaces the chorio-

Digitized by Google

capillaris, or, where it is still present, in the fibrous tissue that has been heaped up on its inner side and has destroyed the lamina vitrea. Where the fibrous tissue forms a thick mass uniting the choroid and retina, the bone may then appear to be quite internal to the choroid. The inner surface of the bone is usually lined by a layer of dense, richly nucleated, but poorly vascular connective tissue, which in places shows the presence of choroidal pigment among its fibres (this is specially seen in Case 7, where there is a considerable amount of such pigment throughout this fibrous layer). In the cases where the retina has become detached from the choroid, the retinal pigment layer over the area of ossification is either absent altogether or represented by cells that are mostly degenerated and almost devoid of pigment. Where the fibrous layer unites the choroid and retina, as in Cases 5 and 7, the pigment epithelium has proliferated more or less extensively, and lies internal to and separate from the ossified mass.

Hyaline masses.—In the layer of fibrous tissue lining the external border of the bony plate one often sees a number of rounded bodies of various sizes. They are well defined, granular, and not striated in appearance, and lie either singly or united to each other or to the end of a trabecula of bone; they do not take up any distinctive stain, as, *e. g.*, that for amyloid degeneration, but stain readily with hæmatoxylin; they look not unlike the colloid bodies seen on the surface of the choroid in other parts, and from that point of view might be taken for the remains of the membrane of Bruch which had elsewhere disappeared; in places, clumps of pigment are seen in their neighbourhood, or pigment granules may be attached to them. As to their nature, they are probably masses of exudation that have undergone hyaline degeneration (*cf.* similar bodies often found in the cornea) and have evidently become in part calcified. Fontan (13) describes somewhat similar bodies, which he also considered to be exudates that had become calcified. He thought that

Digitized by Google

from their number they had a part in the ossification of the adjacent fibrous layer as "stores of the calcareous elements for ossification;" he found them only where the osseous layer was incomplete or showed no cancellous tissue. This last statement is not borne out by my cases. In Case 1, one or two such bodies are seen embedded in the bone itself.

Site of the bone.—In nearly all my cases the bone was formed in the posterior part of the choroid round the entrance of the optic nerve, but in Case 3 ossification has evidently begun at some distance from the optic disc. Hoene (18) explains the usually greater intensity of a choroiditis at the posterior pole on the ground that the inflammatory process may develop freely on the surface and spread laterally, and its intensity is thereby diminished; "but when it comes to the ring of the optic nerve, where the sclerotic and choroid are more closely bound together and the tissue is more compressed, the plastic exudation can less easily penetrate this area, and the intensity of the process consequently increases." This increased intensity, he adds, may also be due to the richer supply of the nutritive fluids in this region. Possibly the entrance of the short ciliary arteries into the globe here does have some connection with the increased exudation. Independent foci may be seen at other parts of the choroid or in the colloid bodies on its surface. In Case 4, where ossification of these colloid bodies is seen, the various appearances as described give one the impression that the colloid body is not directly converted into bone, but that its substance is replaced by fibrous tissue, in which the formation of bone then takes place. This is comparable to the process of ossification in the lens. The formation of bone has, however, not been confined to the choroid in the cases above described; in several it appears in the detached retina and the cyclitic membrane (in Case 7 it has surrounded the lens and actually penetrated under its anterior capsule), while in Case 5 it forms a mass that occupies the whole of the vitreous chamber.

Digitized by Google

Growth of the bone.—Bone in the choroid is never developed through cartilage, but is always of the periosteal type. The first step in the conversion of the fibrous tissue into bone is seen in the more homogeneous, or finely granular, more dense appearance that it assumes; it stains with eosin more brightly than the unchanged fibrous tissue. In this, the so-called osteoid stage, very few cells are seen in its substance, but already the cells at the border of the mass begin to assume an angular shape. When the deposit of lime salts takes place, this osteoid tissue now appears roughly granular, and is deeply stained with hæmatoxylin; and as it merges into the more fully developed bone it again becomes clear and takes on the eosin stain, the spaces enclosed by the trabeculæ being lined by a layer of cells, the osteoblasts. The end of a growing trabecula of bone is often seen to merge into a richly nucleated fibrous bundle. Where the fibrous tissue has attained some thickness towards the inner surface of the choroid, ossification appears to begin in its outer layers first, so that they exhibit the lamellated structure and Haversian systems of fully developed bone, when its inner layers show only small trabeculæ that still have a fibrous appearance and possess only a few lacunæ and canaliculi with their corpuscles.

Origin of the osteoblasts.—Different views have been put forward on this point. Stöhr, as quoted by Whiting (38), thought that "they are embryonic cells with a tendency to bone-formation which deposit themselves by preference at points involved in such metamorphosis." These are presumably conveyed to the eye from the periosteum of the orbit or some other region. This view had also been put forward by Busch, but is refuted by Kassowitz (19). Regarding the conversion of connective tissue into bone, Stöhr remarks, "Single connective-tissue fibres become calcified, and on these are deposited osteoblasts, originating from embryonic cells, forming, after the manner described, bone." Grandclement (16) suggested that the embryonic cells, that still remain in

Digitized by Google

the choroid from fœtal life, are stimulated into growth by the long-standing inflammation or irritation, and form fibrous tissue and then bone. Reid (31) and, more recently, Buchanan (6) have expressed the opinion that the connective-tissue corpuscles are converted into real bone-corpuscles. This appears to be the most likely view, for the cells of the fibrous tissue are frequently seen to take on an angular shape, and as they become more deeply embedded in the young ossified tissue are evidently converted into true bone-corpuscles. Pagenstecher (28) had long before suggested that the bone-corpuscles might arise, among other sources of origin, from the cellular elements of the choroid. It is, however, not yet clear whether these connective-tissue cells are ultimately derived from the fixed cells of the choroid or from the cells of the capillary walls. Any connective tissue, it is said, may be converted into bone, yet it is difficult to say what are really the factors that determine the commencement of such a change in the fibrous tissue that forms in the choroid or other parts of the eye. In his study on *Normal and Pathological Ossification*, Kassowitz (19) found that while this process is always dependent on the development of blood-vessels in the ossifying tissue, it can only begin when this tissue has given up its expansive growth, and when simultaneously, or soon afterwards, the vascularisation of the tissue comes to a standstill or recedes. This diminution in the blood-supply to the part concerned he believed to be common to all pathological ossification. Yet he admitted that his theory did not explain why ossification does not set in in every possible case. Dürr and Schlegtendal (11) looked upon the presence of a plate of bone between the choroid and retina in a case of hydrophthalmos as a proof of the diminution of the blood-supply, and this diminution they attributed to the folding of the sclerotic by the external ocular muscles. In applying Kassowitz's description of ossification to the eye, Goldzieher (15) expressed the opinion that the vitreous lamina and the substance lying between the vessels of the chorio-

Digitized by Google

capillaris are really finely fibrillar in structure, and thus act as a filter to the blood-plasma, weakening the current and thereby favouring the deposition of the lime salts. But, apart from this view of the structure of these parts, their action as a filter cannot be taken as an essential factor in the production of bone in the choroid, because the lamina vitrea is so often entirely absent, and the bone not infrequently forms on its external surface where it still remains.

Views of other writers.—In 1871 Knapp (20) published a paper on this subject, in which from the examination of a number of cases he came to the conclusion that the chorio-capillaris is the place of origin of bone in the choroid. "In a low stage of development," he says, "the ossification begins in small plates, which lie in the chorio-capillaris and are covered by the hyaline membrane and the pigment epithelium." This describes exactly the appearance presented by some of my cases where the bone-formation is not far advanced. He says further, "In a more advanced stage the more abundant exudation wrinkles and perforates the hyaline membrane, invests the inner surface of the choroid, and is gradually converted into osteoid tissue." And in this view Knapp is supported by not a few writers, of whom I may mention Pagenstecher (Case 2), Whiting, Reid, and the most recent, Lagrange (23), in his book on tumours of the eye. Berger, as quoted by Lagrange, says, "In the cases which we have observed at the beginning of the ossification, we have found that the vitreous lamina covering the internal surface of the choroid was preserved. The chorio-capillaris was no longer recognisable." From the ophthalmoscopic examination of one case Laqueur (24) also inclined to the view that the bone arose in the chorio-capillaris. Knapp, however, obviously went too far when he asserted that the formation of bone in the eye arises exclusively in the capillary layer of the choroid or inflammatory products derived from it, and when he denies the occurrence of true bone in other parts,

Digitized by Google

such as the lens, retina, and vitreous body. Bone in the lens does occur; in fact, bone-formation has been reported in every tissue of the eye except the cornea. Moreover, the view of the exclusive origin of bone in the choroid from the chorio-capillaris is refuted by the cases recorded by Fontan, Schiess-Gemuseus, Brailey (4, 5), and others, in which the bone was found on the inner surface of the intact membrane of Bruch. Lagrange recognises this alternative situation of the bone, observing that the commencement of the ossifying process may take place between the retina and the lamina vitrea, or external to the lamina vitrea, *i. e.*, in the chorio-capillaris itself. The latter case, he thinks, is the more frequent, and he explains the former on the ground that the inflammatory exudation from the choroid has early ruptured the lamina vitrea, and spread between this lamina and the retina, and that in this place it is invaded by the process of ossification.

In the *Royal London Ophthalmic Hospital Reports*, Brailey recorded a number of cases from which he concluded that the bone lies most frequently internal to Bruch's membrane. This view is repeated in Norris and Oliver's *System of Diseases of the Eye*. Fontan and Schiess-Gemuseus record similar cases. The number of Brailey's cases in which the bone lay internal to the vitreous lamina, compared to those where it was situated in the chorio-capillaris, is remarkable, considering the total number of cases of ossification of the choroid recorded and the comparatively few cases similar to his that have been elsewhere described. A number of the latter are described in the museum catalogue of Moorfields Hospital, and here support is given to Brailey's view. Various explanations have been put forward as to the origin of the bone in this situation. In some of his cases Brailey traced its source to the retinal epithelium. This theory is, however, I think, untenable, for it is hardly conceivable that this layer, which is epiblastic in origin, could give rise to a mesoblastic tissue such as bone. Treacher Collins

Digitized by Google

traces the formation of bone inside the membrane of Bruch to an ossification of the hyaline exudation or secretion from the retinal pigment, which often proliferates amongst the fibrous tissue that forms in cases of chronic choroiditis such as we are discussing. But it is possible that this hyaline secretion is really mistaken for the clear homogeneous "osteoid" stage of the fibrous tissue as it is being converted into bone. Moreover, for the ossification of this hyaline secretion the cellular or vascular elements must ultimately come from the choroid. The more recent researches of Krückmann (21) into the behaviour of the retinal epithelium under pathological conditions seem to oppose the idea that this layer ever takes any real part in the process of ossification.

Alt (1), again, considers the colloid bodies the most frequent source of bone inside the membrane of Bruch. In one of my cases (No. 5) where ossification is taking place in these bodies, it is apparently independent of that in the other parts of the choroid (in which the bone-formation is more advanced), and is proceeding from the choroidal layers external to these bodies.

Others, again, believe that the initial changes take place in the vitreous lamina itself.

Whatever be the real explanation of the origin of the bone in these cases—and the one proposed by Lagrange and quoted above appears not improbable—I am inclined, from a study of my own cases and those of others, to think that, so far from being a rare occurrence in the choroid, *i. e.*, in the chorio-capillaris, as Brailey and Lobo state, ossification begins really *more* frequently in fibrous tissue that arises from the chorio-capillaris, and either replaces, or lies immediately internal to, this layer.

It only remains for me now to express my thanks to Dr. Usher, Aberdeen, for Cases 4 and 5, together with notes on them which he kindly gave to me; and to Mr. W. T. Lister, the former curator at Moorfields Hospital, and Mr. J. Herbert Parsons, the present curator, for their

Digitized by Google

frequent valuable assistance and advice. To Mr. Parsons I am also specially indebted for his kindness in taking the micro-photographs that illustrate this paper.

Bibliography.

(1) Alt.—"Compend. der norm. u. path. Histologie des Auge," 1880, p. 144.

(2) Bassères et Rochon-Devignaud.—"Ostéome de la choroïde," *Journ. de Méd. de Bordeaux*, 1887–8, xvii, 171.

(3) Berthold.—"Beiträge zur path. Anatomie d. Auge," *Archiv f. Ophth.*, xvii, 1, p. 196.

(4) Brailey.—"Colloid Degeneration of the Choroid with Ossification," *Ophthalmic Review*, June, 1892, *Ophthalmic Hospital Reports*, 1882, vol. x, p. 390.

(5) Brailey and Lobo.—"On Choroidal New Formations," *Ophthalmic Hospital Reports*, 1882, vol. x.

(6) Buchanan, L.—"Cyclitis," *Transactions of the Ophthalmological Society*, vol. xxi, 1901.

(7) De Wecker.—*Traité complet d'Ophtalmologie*, tom. ii, p. 492.

(8) Despagnet et Carra.—"Pachychoroïdite avec ossification," *Rec. d'Oph.*, Paris, 1900, S. 3, xxii, 513—520.

(9) Donders.—*Klinische Monatsbl. für Augenhkde.*, 1871, p. 468.

(10) Drake-Brockmann, E. F.—"A Case of Ossification of the Choroid," *Brit. Med. Journ.*, 1899, No. 1472, p. 585.

(11) Dürr u. Schlegtendal.—"Fünf Fälle von Hydrophthalmos congenitus," von Graefe's *Archiv für Oph.*, vol. xxxv, 2, p. 129.

(12) Faravelli e Gazzaniga.—"Zwei Fälle von Knochenbildung im Auge," *Annali di Ottalmologia*, 1888, fasc. ii (*Centralblatt f. A.*, 1888, vol. xii, p. 306).

(13) Fontan.—"Ossification de la choroïde: Examen de trois bulbes oculaires atteints de cette ossification," *Rec. d'Opht.*, 1883, iii, 205—211.

(14) Gillet de Grandmont.—"Ossification totale de la choroïde," *Rec. d'Opht.*, 1887, No. 4, p. 220.

Digitized by Google

(15) GOLDZIEHER, W.—"Ossifications in the Eye," *Archives of Ophthalmology*, 1880, vol. ix, p. 300.

(16) GRANDCLEMENT.—"Un cas d'ossification complète de la choroïde," *Lyon Méd.*, 1898, tom. lxxxvii, p. 481.

(17) GROSSMANN.—"De l'ossification dans l'œil," *Archives d'Ophtalmologie*, 1889, ix, p. 137.

(18) HOENE, J.—"Recherches microsc. sur les ossifications choroïdiennes," *Rec. d'Opht.*, Paris, 1882, iv, pp. 708—715.

(19) KASSOWITZ, M.—"Die normale Ossification," *Wien. med. Jahrbücher*, 1879, p. 145.

(20) KNAPP.—"Formation of Bone in the Eye," *Archives of Ophthalmology*, 1871, vol. ii, p. 1.

(21) KRÜCKMANN, E.—"Die patholog. Veränderungen der retinalen Pigmentepithelzellen," Graefe's *Archiv f. O.*, Bd. xlviii, 1899.

(22) LAENNEC.—"Ossification de la choroïde," *Bull. Soc. Anat. de Nantes*, 1888, Paris, 1890, xii, 17.

(23) LAGRANGE, F.—*Traité des Tumeurs de l'Œil*, tom. i, 1901.

(24) LAQUEUR.—"Ophth. Befund der Ossification der Aderhäut.," Knapp's *Archiv*, vi, 1, 284.

(25) LUNDY, C. J.—"Ossification of the Ciliary Body and Choroid," *Medical Record*, 1880, vol. xvii, p. 25.

(26) MEIGHAN, T. S.—"Ossification of the Choroid," *Glasgow Med. Journ.*, Aug., 1888, p. 178.

(27) *Ophthalmic Hosp. Reports*, vol. vii, pp. 201, 394; vol. x, p. 390.

(28) PAGENSTECHER, A.—"Beiträge zur patholog. Anat. des Auges," Graefe's *Archiv*, vii, pp. 98—115.

(29) PARISOTTI.—"Sur les ossifications dans l'œil," *Rec. d'Opht.*, Aug., 1887, No. 8, p. 462.

(30) RASSIGA, W.—"Ueber Verknöcherung der Choroidea," *Inaug. Diss. Strassburg*, Oct., 1900.

(31) REID, T.—"Ossification of the Choroid," *Glasgow Med. Journ.*, 1888, xxix, 248.

(32) ROMANO.—"Ossification im Bulbus," *Archiv. di Ottalmologia*, anno ii, p. 345 (*Centralblatt f. A.*, 1897, p. 529).

Digitized by Google

(33) Ruiz.—"Ossification totale de la choroïde," *Rec. d'Opht.*, Jan., 1899, p. 29.

(34) Schiess-Gemuseus, H.—"Beitrag zur Lehre von der Knochenneubildung in der Choroidea," Graefe's *Archiv*, 1873, vol. xix, 1, p. 202.

(35) Wagenmann.—(1) "Beitrag zur Kenntniss der path. Anatomie der Retinitis pigmentosa," von Graefe's *Archiv*, vol. xxxvii, 1, 325; (2) "Ueber das Vorkommen von Riesenzellen u. eitriger Exsudation," von Graefe's *Archiv*, vol. xxxvii, 3, 131.

(36) Webster.—"Two Cases of Ossification of the Choroid," *Archives of Ophthalmology*, 1901, vol. xxx.

(37) Wegener, F.—"Ueber Knochenbildung im menschlichen Auge," *Inaug. diss. Kiel*, 1900.

(38) Whiting, F.—"Case of Primary Sarcoma of Iris, etc.," *Archives of Ophthalmology*, vol. xix, p. 361.

(39) Wilson.—"Ossification of the Choroid," *Dublin Quart. Journ. Med. Sci.*, vol. lvi, p. 415.

(40) Wood, T. H.—"Ossification of the Choroid," *Archives of Ophth.*, vol. xix, p. 388.

(*January 29th*, 1903.)

N.B.—This communication was illustrated by microphotographs.—Editor.

---

3. *Keratitis, with special reference to the part played by the corneal corpuscles.*

By Leslie Buchanan, M.D. (Glasgow).

(With Plates XI and XII.)

It is well known that a large amount of work has been done upon this subject by men of the highest repute, and that diverse views are held by various authorities, especially as to the question whether the true corpuscles

Digitized by Google

of the cornea take any part in the production of the cellular exudation in cases of keratitis.

Several years ago the writer determined to investigate the matter so far as he could for himself, but as the majority of the work done had been of an experimental nature, it was decided to turn rather to the examination of cases of keratitis, such as are seen every day in ophthalmic *cliniques* as a result of injury and disease, As it would be almost impossible, in the limits of a short paper, to give even a *résumé* of the work, and as it is probable that the results could best be presented by the reproduction of a few photographs of microscopical sections from typical cases, this latter mode has been chosen. The principal points which it is desired to bring out are two in number, namely, first, that the corneal corpuscles play a very active part in the various processes of inflammation of the cornea; and, second, that there is evidently a definite sequence of events in the various types of inflammatory process, the changes seen in the more severe forms being really the same as those seen in the milder, but carried to a greater extent.

It is not contended that all the cellular exudation in keratitis is the result of proliferation of corneal corpuscles, for it is clear that in some cases, particularly chronic ones, migration from the blood-vessels does take place. So much evidence has been seen, however, which points to the corneal cells as the origin of the cellular elements of the exudation in acute cases, that although the writer began this investigation with a bias in the opposite direction, he is now convinced of the truth of the statement made above.

In order to make the appearances which are seen more easily understood, sections have been made of the cornea in two places, one at right angles to its surface (meridional), and the other parallel to its surface (equatorial). It is believed that this is the only way in which the phenomena can be truly observed, as in the equatorial section the corpuscles and the products of cell prolifera-

Digitized by Google

Digitized by Google

PLATE XI.

Illustrates Dr. Leslie Buchanan's paper on Keratitis, with special reference to the part played by the Corneal Corpuscles (p. 239).

Fig. 1.—Meridional section of the cornea close to the edge of a wound six days old. To show the early stages of infiltration. × 40.

Fig. 2.—Equatorial section of cornea, as in Fig. 1. To show a group of almost normal corneal corpuscles surrounded by others in a state of active proliferation. × 150.

Fig. 3.—Equatorial section of cornea, as in Fig. 1. Small portion highly magnified to show corneal corpuscles in the act of proliferation. × 350.

Digitized by Google

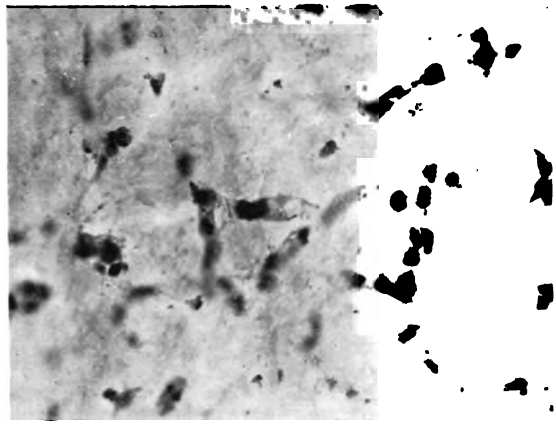

FIG. 3.

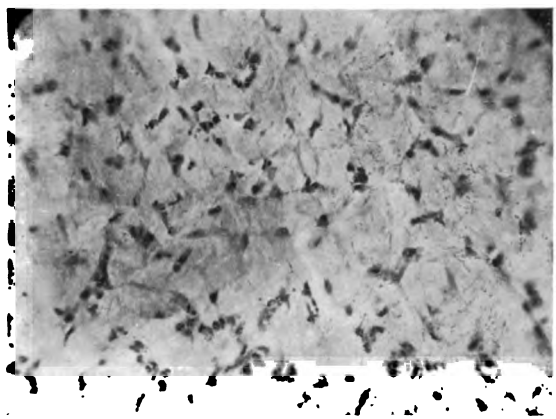

FIG. 2.



FIG. 1.

Adlard & Son, Imp.

Digitized by Google

Digitized by Google

Digitized by Google

PLATE XII.

Illustrates Dr. Leslie Buchanan's paper on Keratitis, with special reference to the part played by the Corneal Corpuscles (p. 239).

FIG. 4.—Equatorial section of the cornea, as in Fig. 1. To show corneal corpuscles in a more advanced state of proliferation than in Fig. 3. × 350.

FIG. 5.—Meridional section of the cornea in an early stage of suppuration. To show large groups of cells lying in interlamellar spaces much distended. × 150.

FIG. 6.—Equatorial section of the cornea, as in Fig. 5. To show the appearance of the structure, the interlamellar spaces distended partially by œdema and partially by cell proliferation and accumulation. The cellular matter is seen to be composed of small fragmented nuclei lying in granular protoplasm, not definite cells. The lamellæ are becoming broken up by the intrusion of fluid and cellular matter. × 200.

Digitized by Google



FIG. 6.

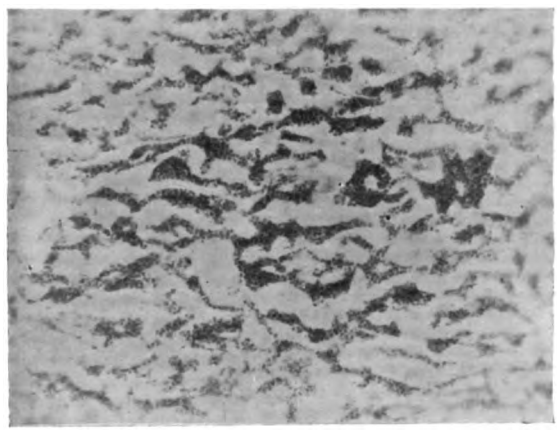

FIG. 5.

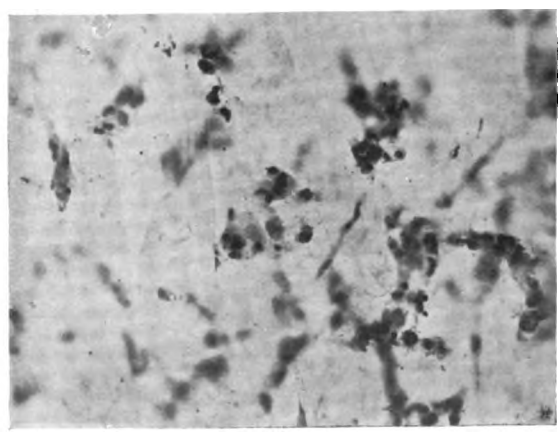

FIG. 4.

Adlard & Son, Imp.

Digitized by Google

Digitized by Google

tion can be much more easily observed than in meridional sections.

The cases chosen for demonstration are only a few amongst many, but they have been put forward as representative of groups beginning with the less severe and advancing in severity to that in which suppuration takes place.

Before looking at the pathological aspect of the subject it is desirable that it should be clearly understood that in the young subject proliferation of the corneal cells takes place constantly.

(*July 3rd*, 1903.)

Digitized by Google

XII. CONGENITAL CONDITIONS.

1. *Persistent hyaloid artery.*

By Percy Flemming and J. Herbert Parsons.

Clinical notes.

Henry T—, æt. 6 months, was brought to University College Hospital on account of a peculiar appearance in the right pupil. The right eyeball is obviously small, cornea and A. C. normal, pupil regular, dilating very little under atropine, and inactive to light. A grey-white reflex is seen in the pupil, which further examination shows to be due to a mass situated just behind the lens. Numerous vessels can be seen on this mass, but no one well-defined red spot can be seen, nor can any red reflex be obtained round the mass, but, as stated above, the pupil could not be well-dilated.

The diagnosis was thought to rest between (1) pseudo-glioma; (2) true glioma; (3) persistent fibro-vascular sheath. Absence of any sign of inflammation excluded (1), and no direct evidence of (3) was forthcoming such as the presence of a definite red spot in the centre of the mass, and a red reflex around the opaque mass. The eye was therefore excised, since it was thought to contain a glioma.

Pathological notes.

Macroscopical Examination.—The eye has been cut to one side of the optic nerve. The cornea and A. C. look normal. A fine strand is seen passing through the vitreous

Digitized by Google

from the optic disc to the centre of the back of the lens. Surrounding it here is a lens-shaped mass of connective tissue, around which is a zone of clear lens at the periphery. Crossing this zone are three ciliary processes, the tips of which are in apposition to the edge of the disc of connective tissue. The other ciliary processes are in their normal situation. The eye is smaller than normal (microphthalmos, antero-posterior diameter = 15 mm.), but shows no other gross abnormalities.

Microscopical Examination.—Cornea and A. C. normal; angles open, do not show undue persistence of spaces of Fontana. Iris stroma more cellular than usual; retinal pigment layer is adherent to lens capsule at pupillary border. The lens with the fibrous mass has the usual biconvex shape, as the fibrous mass indents the true lens. The anterior capsule and fibres are normal. The anterior epithelium extends rather behind the equator. The posterior capsule is thickened and wavy at the periphery of the fibrous disc; it is continued in front of this, gradually thinning off towards the posterior pole. There does not appear to be any gap in the capsule. The fibrous mass consists of vascular, densely nucleated connective tissue. Two sets of nuclei stand out distinctly —deeply staining rod-shaped nuclei, and oval faintly staining nuclei. The persistent hyaloid artery runs into the mass at the centre behind. There is only a single thin-walled vessel, and this can be traced through the vitreous to the optic nerve. Sections through the three ciliary processes which meet the fibrous mass show that they are stretched and attenuated. They do not actually join the mass, although they touch it. No vessels can be traced from the mass into them, though it would be impossible to deny that some may be present. Other parts of the eye are normal. There is a ring in the retina near the posterior pole, which may be a rosette, such as is found in glioma and microphthalmos, etc., but is more probably a fold.

(*May 7th*, 1903.)

Digitized by Google

2. *Anophthalmos and microphthalmos in a chick.*

By E. Treacher Collins and J. Herbert Parsons.

(With Plate XIII.)

The chicken which forms the subject of these notes was bred from an Indian game-cock and a Dorking hen. The same fowls have been bred from for the past two years. None of their previous progeny have presented any malformations.

The chick was hatched in an incubator; it was quite healthy, but born blind. It could not see to find its food, but could eat and drink quite well "when put to it." It was killed when four days old, and its head sent for examination.

After the removal of some of the feathers, the eyelids on each side were seen to be well formed. On separation of them, a small eyeball with a clear bright spot in it representing the cornea could be seen on the left side. On the right side no eyeball could be made out.

The head of the chick, after being hardened in formol, was decalcified and embedded in celloidin. A series of sections were then cut through it vertically so as to pass across both orbits. All the sections traversing the orbits were preserved, and a large number of them from different levels stained and mounted.

Microscopical examination of these sections show that on the right side no optic nerve, retina, or lens are present. Some hyaline cartilage, situated a little depth from the surface in the form of a complete ring, is seen in some of the sections (Plate XIII, figs. 1 and 3). The width of the cartilage composing this ring is about that of the hyaline cartilage in the sclerotic of the left eye, and like it has externally a small amount of fibrous tissue. Outside this fibrous tissue is striated muscle and adipose tissue.

Digitized by Google

Digitized by Google

PLATE XIII.

Illustrates Messrs. E. Treacher Collins and J. Herbert Parsons' paper on Anophthalmos and Microphthalmos in a Chick (p. 244).

FIG. 1 shows the microscopical appearances of a vertical section through the chick's head traversing both orbits, under a low power. A malformed microphthalmic eye is shown in the left orbit. Deep in the right orbit is a ring of hyaline cartilage with some irregularly pigmented tissue, like that of the choroid, in its interior.

FIG. 2 shows the left microphthalmic eye under a higher power. The adhesion of the lens to the posterior surface of the cornea is well depicted, also the extension of the upper part of the iris and ciliary body round the posterior surface of the lens, and the arrested development of the iris below.

FIG. 3 shows the ring of hyaline cartilage from the right orbit more highly magnified, and the character of the tissue contained within it.

Digitized by Google

Fig. 1.

Fig. 2.

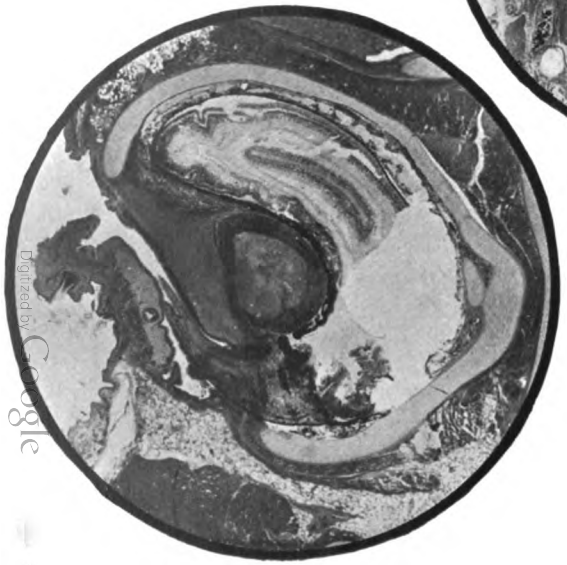

Fig. 3.

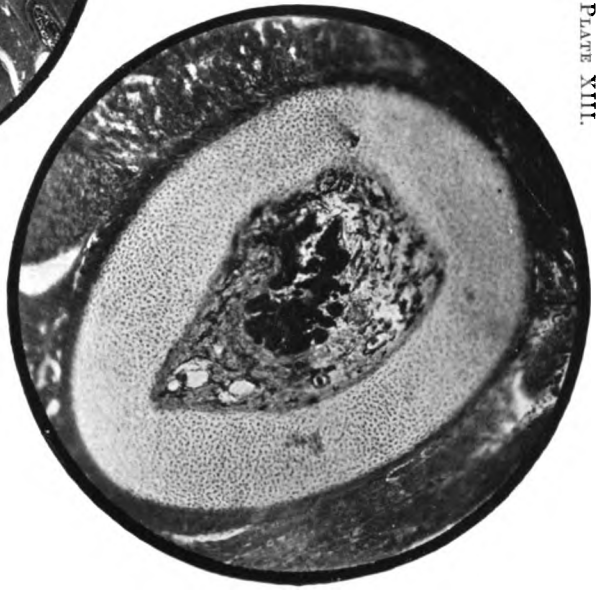

Adlard & Son, Imp.

Digitized by Google

Digitized by Google

In some sections the hyaline cartilage is not a complete ring; it has a gap in one side through which fibrous tissue similar to that on the external surface passes. In others the cartilage is arranged in two semi-lunes, there being breaks in its continuity filled with fibrous tissue both on its deep and superficial surfaces.

The interior of the ring of cartilage is filled with tissue resembling that of the choroid somewhat condensed, fibrous tissue, blood-vessels, and nerves, like the ciliary nerves, being seen. There are also delicate, fine, branching, pigmented cells, and in the centre some much denser pigmented tissue in the form of irregular dots and twisted branching lines. A careful comparison of this latter pigmented tissue with that contained in the choroid of the left eye shows that it is of the same character though somewhat more condensed, and that it is not pigmented epithelium of retinal origin, which it might possibly at first be taken for. There is no tissue in the interior of the ring or anywhere in its vicinity resembling retina or optic nerve.

The eyelids and conjunctival sac on this side appear well developed. In those sections where the ring of cartilage above described approaches nearest the surface, it is separated from the epithelium of the conjunctiva only by a small amount of dense fibrous tissue and some loose adipose tissue. Nowhere can any down-growth of epithelium or anything representing the lens be distinguished. On the left side the eyelids and conjunctival sac appear normal. The cornea is small and the anterior part of the eyeball much flattened. The sclerotic is seen to be formed in the normal way of a cup of hyaline cartilage, becoming thicker at the posterior pole and having a little fibrous tissue external to it. There is a wide gap in the posterior part of the cup through which the optic nerve passes. On one side of the nerve there is a considerable band of fibrous tissue between it and the cartilage. Anteriorly the cup of cartilage is seen to end in rounded extremities a short distance from the corneal margin.

Digitized by Google

Normal laminated epithelium covers the anterior surface of the cornea; there is no anterior limiting membrane (Bowman's layer). The substantia propria of the cornea appears imperfectly developed. It is largely composed of spindle-shaped cells; the nuclei of the cells in it are much closer together than in normal corneæ. There is no posterior limiting membrane (Descemet's membrane).

The lens is in immediate apposition with the posterior surface of the cornea, its hyaline capsule being attached to the substantia propria for a portion of its extent. Above, nothing intervenes between these structures; below, some vascular tissue, of the nature of the stroma of the iris, separates them for a short distance (fig. 2).

The choroid appears normal and ends anteriorly in the ciliary body, which is much distorted. The striated fibres of Crampton's muscle can be seen on each side; its anterior part is pressed into close contact with the sides of the lens.

At the lower part there is hardly any iris. The pigment epithelium of the ciliary body and unpigmented layer of cells forming the pars ciliaris retinæ are much plicated, and terminate in contact with the lower border of the lens. As above mentioned, a small amount of tissue like the stroma of the iris has insinuated itself for a short distance between the cornea and lens.

At the upper part of the eye the anterior part of the ciliary body and what represents the iris turn backwards behind the lens, lying in close contact with its posterior surface for more than two-thirds of its extent. Behind the upper part of the lens there is, from before backwards, tissue like the stroma of the iris, pigment epithelium, and imperfectly formed retina, *i. e.*, retina in which its several layers have not become differentiated. Further down on the posterior surface of the lens the stroma of the iris ceases, and the pigment epithelium, much rucked, lies in direct contact with the lens capsule. The tissue-like undifferentiated retina passes into a single layer of unpigmented cells which continue up to the pupillary margin.

The iris from above extends so far down on the back

Digitized by Google

of the lens that its pupillary margin is quite at the lower border.

The lens is very imperfectly formed. A hyaline capsule completely surrounds it. At the anterior pole a single layer of flattened cells lines the capsule. A short distance away from the anterior pole the lining cells gradually begin to lengthen out. They are longest and thinnest of all about the equator. They diminish slightly in length on the posterior capsule, but even there are of considerable size. The surface formed by these lining cells towards the interior of the lens gives rise to a very well-defined line. The space left within this line is filled with what looks like coagulated albuminous material with scattered, large, squamous-like, epithelial cells in it.

The retina at the posterior part of the eye is fully developed, presenting its normal arrangement of layers.

It will be gathered from the above detailed description of this specimen that on the right side there was absolute non-development of all portions of the eye formed from neural epiblast, *viz.*, optic nerve, retina, and pigment-epithelial layer. Further, that though all the neural epiblastic elements were absent, some imperfect formation of the subsidiary structures developed from mesoblast (choroid and sclerotic) had taken place.

These structures of mesoblastic origin formed a nodule to which the extra-ocular muscles were attached, and which, therefore, might have presented the appearance of a moving stump at the back of the orbit.

The question of where to draw the line between anophthalmos and microphthalmos has been much discussed. In cases where at first it appears that the eye is congenitally absent, by more careful examination a small hard nodule is frequently discovered. Sometimes it is so small that it can only be discovered when the child is kept quiet by an anæsthetic and the finger passed between the lids to the back of the orbit. The existence of such nodules have led some to suppose that in these cases the eye has become shrunken by intra-

Digitized by Google

ocular inflammation occurring *in utero*. Others have considered that where a nodule is present the case is not really one of anophthalmos, but only a very high degree of microphthalmos.

In a paper on anophthalmos in the *Royal London Ophthalmic Hospital Reports*, vol. xi, p. 429, 1887, one of us (E. T. C.) gave a fairly complete review of cases recorded under that name up to that date.

The notes of nine cases were tabulated in which a *post-mortem* examination had been made. Not in any of these cases was an optic nerve found to enter the orbit; in one it ended in a cone at the optic foramen, in another in a fibrous filament, and in five the chiasma was absent. In one case one olfactory lobe was absent, and in another both olfactory lobes and one of the cerebral hemispheres. This is worthy of note because these structures, like the primary optic vesicles, are expansions of the anterior primary encephalic vesicle.

At the end of this paper a further epitome of the literature of the subject of anophthalmos up to the present time will be found.

In the cases of Van Duyse, Bietti, and Spiller, there referred to, it will be seen that the optic nerves, chiasma, and optic tracts were all absent.

So far as we have been able to ascertain, there seems no definite case recorded in which a microscopical examination of the orbit was made and where the mesoblastic structures of the eye were found to be entirely absent; whilst there are several (Michel, Sgrosso, Van Duyse, and probably Bietti) in which, as in the chick the subject of this paper, there was a body in the orbit composed only of structures of mesoblastic origin. From the appearance of the sections through the orbit in this chick, and the complete absence of all round-celled inflammatory exudation, it is evident that the condition of the right eye is not one of phthisis bulbi from inflammation before birth.

The essential element of an eye is a nervous mechanism which serves to receive visual sensations for transmission

Digitized by Google

to the brain. All the other tissues connected with and surrounding such a mechanism are merely subsidiary. When, therefore, there is a complete failure in the development of this essential nervous mechanism, it would seem fair to speak of the condition as one of anophthalmos, even though there may have been some formation, from mesoblastic tissue, of subsidiary structures sufficient to produce a moving nodule at the back of the orbit.

When, however, the essential nervous mechanism has been formed, no matter how imperfectly, and the eye is below the normal dimensions, the case would be one of microphthalmos.

In this chick which we have examined, we should then describe the condition on the right side as one of true anophthalmos, notwithstanding the presence of the small nodule of tissue like sclerotic and choroid. This distinction, which we think is the only true one which can be drawn between these two conditions, is, unfortunately, one which can only be determined with certainty by a microscopical examination.

On the left side in this chick a microphthalmic eye was present, and, as will be gathered from the description of it which has been given, there has been a failure in the development of the anterior chamber. The lens was in contact and adherent, for a portion of its extent, to the back of the cornea. There was no round-celled infiltration or other appearances which would lead us to suppose that this adhesion was inflammatory in origin. It appears to have been simply an instance of arrested development.

It is of considerable interest in showing the altered arrangement in the iris to which it has given rise. It was suggested by Manz, as a probable explanation of the failure in the development of the iris in cases of aniridia, that that structure was prevented from growing inwards by an unusually strong adhesion of cornea and lens before the formation of the anterior chamber.

Digitized by Google

In this specimen an abnormal adhesion of cornea and lens has persisted until after birth. We find in it that the upper part of the iris, prevented from growing inwards in front of the lens, has turned backwards behind it, the iris having thus come to line the posterior surface of the lens for a considerable portion of its extent. Below, the growth of the iris forwards has become arrested, it being represented only by a little of the stroma between the lens and cornea where they are not quite in contact, the pigment epithelium of the ciliary body terminating at the lower border of the lens.

Summary of Literature on Anophthalmos.

Haab (1) carefully investigated a case of anophthalmos in a man, æt. 27 years. The chiasma was absent, the optic tracts were very small, and the corpus geniculatum externum was absent. The corpora quadrigemina were normal. All the extrinsic eye muscles, with their nerves, were normal in size and shape. The L. eye measured 3·5 mm. by 2·5 mm. The very small optic nerve entered behind. Cornea, iris, ciliary body, and lens were absent. The sclera contained choroidal elements, a few rods and cones and pigment-epithelial cells (no nerve-fibres), and vitreous. There was no lamina vitrea, but there were colloid bodies surrounded by pigmented epithelium. The R. eye was globular, 4 mm.—4·5 mm. in diameter. It contained more retinal elements, especially rods and cones and outer nuclear layer; there were no ganglion cells or nerve-fibres, and no colloid bodies. There were no nerve-fibres in the optic nerve.

Nieden (2) describes a case of anophthalmos cyclopica; but there is no microscopic examination.

Strösse (3) reports a case of unilateral anophthalmos in a calf. Careful examination (? microscopic) of the orbital tissues failed to disclose any eye or optic nerve.

Hilbert (4) reports bilateral anophthalmos in a girl, æt. 9 years. There was no anatomical examination. He (5) also

Digitized by Google

reports a bilateral anophthalmos in which there was catarrhal conjunctivitis at birth. This is of importance in consideration of the possibility of anophthalmos being due to the intra-uterine phthisis bulbi. On the R. side there was no sign of an eye; on the L. a grey, pigmented globe, 2 mm. in diameter.

Huth (6) records bilateral anophthalmos, without anatomical examination.

Fromaget (7) records a case of R. anophthalmos with congenital cyst in the lower lid, and L. microphthalmos. The cyst (only) was carefully examined.

Harlan (8) reports a similar case of anophthalmos with cyst. No microscopic examination could be made of the orbital contents. No eye or optic nerve could be made out.

Stuffler (9) reports bilateral anophthalmos in an otherwise normal new-born child. There was no anatomical examination.

Sgrosso (10) examined a pig in which one eye was apparently absent, but microscopic examination revealed sclera, ciliary body, and traces of choroid covered by a dermoid with cartilage, sweat and sebaceous glands, bone, etc. There was a coloboma of the optic nerve in the other eye.

E. von Hippel (11) examined bacteriologically a case of R. microphthalmos and L. anophthalmos in which pus was present in the conjunctival sac at birth. Pneumococci, which were not virulent as regards rabbits, were present. The patient had a brother with bilateral anophthalmos, another with hydrocephalus, and a sister with microphthalmos, and congenital opacities of the cornea. Von Hippel reviews the whole subject in this paper, concluding in favour of intra-uterine inflammation as the usual cause. Hoppe (12) arrived at the same conclusion.

Van Duyse (13) gives a very careful account of a bilateral anophthalmos. The optic nerves, chiasma, tracts, and external geniculate body were absent. The extrinsic eye muscles were present. The eyes were extremely

Digitized by Google

small, and consisted of a fibrous envelope, containing branched pigmented cells and blood-vessels. There were no epiblastic tissues present (corneal epithelium, lens, retina, optic nerve).

Fromaget (14) reports another case of anophthalmos with congenital cyst in 1900. There was no anatomical examination.

Bietti (15) gives an excellent description of a bilateral anophthalmos, and a critical discussion of the causes. In a boy, æt. 15 days, the palpebral fissure each side measured 0·5 cm.; there was intense conjunctival catarrh. The child died when 15 months old. *Post mortem*, the convolutions of the brain were good, including the occipital lobe; corpora mammillaria present; no infundibulum or hypophysis; chiasma, optic nerves, tracts, and external geniculate bodies absent; pulvinar and ant. corp. quadrigemina smaller than normal; internal geniculate body normal. All the cranial nerves were present except the second. The fourth and sixth were small. The optic foramen was occupied by a filament, proved microscopically to be an artery. The extrinsic muscles were present in the orbits. The eyes were microscopic. The R. eye was a nodule 3 mm. ant.-post. by 1·5 mm. vert. Another nodule posteriorly was the ciliary ganglion. The bulb consisted of a fibrous capsule with a pigmented centre; in the latter a more deeply pigmented crescent, with the concavity looking forwards, probably represented retinal epithelium consisting of angular pigmented cells. The other cells were uveal—oval or spindle-shaped. The L. eye measured 1 mm. by 600 μ, and consisted of sclera containing remnants of uvea and retinal pigment.

Brose (16) reports a R. anophthalmos and L. microphthalmos without anatomical examination.

Zimmermann (17) records a case of unilateral anophthalmos. *Post-mortem*: no L. olfactory nerve or bulb; L. optic nerve one fifth size of normal R.; L. third nerve half normal size; other nerves normal. The eye consisted of a small mass of fibrous tissue, the size of a pea, contain-

Digitized by Google

ing a small amount of black pigment. There was no microscopic examination.

Spiller (18) found complete absence of the visual system in an adult idiot, æt. 22 years. The palpebral fissures were extremely small, and the orbits contained only fibrous tissue (macroscopic). No eyeballs could be seen. There were no optic foramina, nerves, chiasma, or tracts; no external geniculate bodies. The pulvinars and ant. corp. quad. were apparently normal. The occipital lobes were small, the cuneus ill developed, and the calcarine fissure short. The ocular nerves were well developed, except both sixths.

References.

(1) Haab.—*Beitr. zur Ophth. Festschrift f. Horner*, p. 131, 1881.

(2) Nieden.—*Arch. f Augenheilk.*, xxii, p. 61, 1890.

(3) Strösse.—*Berl. thierärztl. Woch.*, No. 52, p. 452, 1891.

(4) Hilbert.—*Klin. Monatsbl.*, 1892, p. 287.

(5) Hilbert.—Virchow's *Archiv*, cxxvii, p. 378, 1892.

(6) Huth.—*Arch. f Augenheilkde.*, xxvi, p. 138, 1893.

(7) Fromaget.—*Arch. d'Opht.*, xiii, p. 321, 1893.

(8) Harlan.—*Trans. Amer. Ophth. Soc.*, 1893, p. 559.

(9) Stuffler.—*Rass. di Sc. Med.*, x, p. 121, 1895.

(10) Sgrosso.—*Ann. di Ott.*, 1895.

(11) E. von Hippel.—*Arch. f. Ophth.*, xlvii, p. 227, 1899.

(12) Hoppe.—*Arch. f. Augenheilkde.*, xxxix, p. 201, 1899.

(13) Van Duyse.—*Arch. d'Ophth.*, 1899, p. 412.

(14) Fromaget.—*Journ. de Méd. de Bordeaux*, 1900 (ref. in *Rec. d'Opht.*, 1900, p. 222; *Rev. gén. d'Opht.*, 1901, p. 59).

(15) Bietti.—*Ann. di Ott.*, xxx, p. 319, 1901.

(16) Brose.—*Arch. of Ophth.*, xxx, p. 12, 1901.

(17) Zimmermann.—*Arch. of Ophth.*, xxx, p. 17, 1901.

(18) Spiller.—*Univ. Penn. Med. Bull.*, xiv, 1903 (ref. in *Arch. of Ophth.*, xxxii, p. 67, 1903).

(*March 13th*, 1900.)

Digitized by Google

3. *Rectangular connective-tissue film veiling the optic disc.*

By N. Bishop Harman, M.B.

(With Plate XIV, fig. 1.)

R. B—, female, æt. 25 years, presents a peculiarity of the right disc, noticed during routine examination of eye. Complaint had been made of fatigue on near work; this arose mainly from considerations of general health.

R. and L. V.=$\frac{6}{6}$. Refraction by retinoscopy: R. +0·5 D. sph., $\bar{c}$ +0·5 D. cyl. ax. vert.; L. +0·5 D. sph. L. fundus normal.

R. fundus, optic disc peculiar owing to the greater part of it and the trunks of the retinal vessels being veiled by a rectangular film, looking like a plate of thin mica. The disc is a perfect circle. The artery appears a little to the nasal side of the centre; its division is curious, since it immediately branches into four equal-sized trunks which separate at right angles like the arms of a St. Andrew's cross, forming fronto-nasal, naso-maxillary, maxillo-temporal, and temporo-frontal divisions directed to these intermediary positions. All these vessels are superficial to the veins. The further arterial branching also shows more than usual symmetry. The vein penetrates the disc at its centre; its branches follow a usual course, save that the smaller peripapillary venules are tortuous, apparently by reason of their connection with the abnormal film.

The film lies superficial to all the vessels on the disc. Its most defined and rectangular part lies over and overlaps the nasal half. Three of its edges cross at right angles the arterial trunks. The upper angle is attached to a tributary of the superior vein; the venule is bent at right angles to its effluent. The nasal edge passes thence over the arteries to a nasal angle attached to a small displaced venule of the lower group; this angle is definitely continuous with a delicate coat around the venule. The lower edge passes over

Digitized by Google

Digitized by Google

PLATE XIV.

FIG. 1 illustrates Mr. N. Bishop Harman's Rectangular Connective-tissue Film veiling the Optic Disc (p. 254).

FIG. 2 illustrates Mr. N. Bishop Harman's communication on a Minimal form of Fissura Facialis (p. 256).

Digitized by Google

FIG. 2.

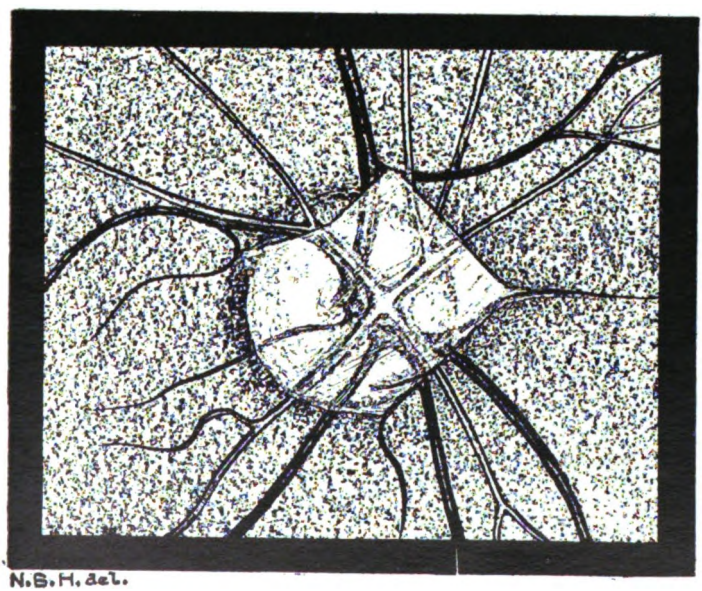

FIG. 1.

Adlard & Son, Imp.

Digitized by Google

Digitized by Google

arteries and veins, splits into superficial and deep layers about the lower edge of the disc; the superficial layer bends towards the disc-centre and is lost; the deep is attached to a small bent venule at the disc-edge, thence it follows the curve of the disc, covering the vessels, to be lost on the temporal border. The upper edge of the film passes over the frontal vessels on to the disc, where it appears to be fixed; continuing outwards, it is lost on the wall of a tributary of the upper temporal vein, which is bent towards the film so that it debouches into the larger vein at a reverse angle of about 120°. All the vessels on the disc are seen to have delicate peri-vascular thickenings. There is no trace of the hyaloid artery.

Connective-tissue films over the disc have been noted. Cases have been collected and summarised by De Beck *; in one of these (by Schaumberg, "double contoured disc") the film was rectangular. De Beck believes the occurrence to be consequent on a greater or less degree of persistence of the hyaloid artery. In another case recently shown before this Society, together with marked abnormal features of the disc was a triangular reticulated film overlying part of it; there was a belief that this condition was the result of some peri-papillary choroiditis.†

The case here described is noteworthy owing to its marked character, the connection of the film with the veins, and the peculiar branching of the artery. There is no trace of any remnant of the hyaloid artery, and the definite connection of the film with the veins seems to exclude the suggestion that it may be a vestige of the hyaloid artery. It can hardly be a thickening of the hyaloid membrane, since the fibrillary structure of the vitreous has been shown to be of ectodermal origin,‡ and this film in its continuity with the perivascular sheaths appears to be mesodermal.

* De Beck, D., "Persistent Remnants of the Fœtal Hyaloid Artery," 1890.

† Roll, G. W., *Trans. Ophthal. Soc.*, vol. xxii, p. 204.

‡ Van Lenhossek, M., "Die Entwicklung des Glaskorpers," 1903.

Digitized by Google

It is probably to be regarded as an exaggeration of the perivascular connective tissue so frequently seen about the disc. Its rectangular disposition would appear to be due to a regular traction in the growth of the globe. In the fœtus the retina is for a while thrown into folds owing to the smallness of its fibrous capsule; with the growth of the capsule the folds are smoothed out. Granting the presence of loose perivascular mesoblast over the disc when the retina is folded, a regular expansion of the globe—as is here indicated by the symmetry of the fundus, circular disc, the regular St. Andrew's cross formed by the arteries, and their relation to the straight edges of the film—would produce such a shape. The distortion of the venules to which the film is attached is obviously due to the restraining influence of the film during vascular growth. (*March 13th*, 1903.)

Mr. ROLL said the case he showed had a network pattern on it. It was triangular, and he thought it was a remnant of the hyaloid artery. It came forward to one side from the optic disc.

---

4. *A minimal form of fissura facialis.*

By N. BISHOP HARMAN, M.B.

(With Plate XIV, fig. 2.)

ERNEST M—, æt. 4½ years. On either side of the bridge of the nose, just within and below the inner canthus, is a small opening. The right opening was noticed immediately after birth, the left not until some few months later. The mother had not at any time observed any discharge from the openings, but the father stated he had seen small plugs of "white stuff" in the mouth of the right opening on some mornings.

Digitized by Google

The right and deeper depression is situated 4 mm. inwards and downwards from the inner canthus, on a line deviating seventy-five degrees from a perpendicular drawn through the edge of the canthus. A No. 1 Bowman's probe can be passed into its mouth upwards and outwards towards the canthus, when the point of the probe can be moved laterally for 3 mm. Coloured fluid driven in by a syringe at once appears in the nose and throat; an increase of fluid is noted in the lacus lacrymalis, but this is apparently only an excess of lacrymal secretion, as it is colourless. The tear ducts are normal save for the apparent connection of this depression with the saccus.

The left opening is very small. It is placed 6 mm. downwards and inwards from the inner canthus, on a line diverging thirty-five degrees from the perpendicular drawn through the edge of the canthus. It will admit a bristle for 2 mm. directly upwards. On driving fluid into the opening from a syringe the site swells momentarily and the fluid regurgitates. There is no evidence of communication with the tear duct. The lacrymal apparatus is normal.

The region of each depression is quite healthy; there is no evidence of any past inflammation. The child is healthy and well-developed; there is no other abnormality, either of the body or eye. The parents present no anomalies.

Eva M—, æt. 4¾ years. The face presents similar but more nearly symmetrical openings. They were noticed immediately after birth. The right is placed 6 mm. downwards and inwards, on a line deviating thirty-five degrees from a perpendicular through the edge of the inner canthus, whilst the left is 5 mm. on a line deviating twenty-five degrees from the canthus. They are of practically equal size, their mouths look downwards, are guarded by small arcuate folds of skin, and admit No. 1 probes readily. Occasionally a small white plug has been seen filling them; this material I have seen; it is indistinguishable

Digitized by Google

from sebum. On injecting them with coloured fluid there is a momentary swelling of the region, but the fluid quickly regurgitates; none appears in nose, throat, or eye. The tear passages are normal. The child is well-developed and bright; there is no other abnormality, either of body or eye.

The Mother of this girl has at the inner angle of the left eye, 4 mm. downwards and inwards from the canthus, a small depression, raised upon a thickening of the dermis, the size of a pea. It was first noticed at the age of seven years, after an attack of measles, as a small hole in the face, like those present in her daughter. After puberty, the site swelled up with each menstrual period; once or twice it became inflamed and discharged. The tear passages appear to be normal. She objected to the use of the syringe, but there is no epiphora or mucocele, nor has there been at any time. It is probable that the unilateral condition found in the Mother was in her earlier years like her daughter's, the thickening being caused, as she asserts, by much handling.

Remarks.—These anomalies appear to be of considerable rarity. I can find records of only two cases at all resembling them, whilst there are very many cases of malformed lids, and gross forms of fissura facialis are by no means rare.

Agnew * reports a case of congenital lacrymal fistula in a girl aged three years; he writes, "The openings, being very small and not in the least raised above or depressed below the surface of surrounding skin, were scarcely distinguished except when a little dew-like moisture exuded." There is no note that the connection of these holes with the tear ducts was determined by syringing or otherwise.

Max Sperling † describes the conditions found in an

* C. R. Agnew, M.D., *Ophthalmic Notes*, New York, 1874, "A Case of Double, extremely Minute, and apparently Congenital Lachrymal Fistula."

† Max Sperling, "Ein Fall von beiderseiten Hirnbruch an den innern Augenwinkeln bei einen Neugeborenen nebst Bemerkungen über die an dieser Stelle vorkommenden angeborenen Bildungsfehler,' M.D. Thesis, Konigsberg, 1889.

Digitized by Google

infant, of which two photographs of the face and drawings of dissections are given. There were on each side fairly large holes, that on the left side being situated on a swelling. The dissections show the deformities were gross; there were widely open passages through the roof of the nose on either side the septum into the brain case.

The significance of the conditions.—From our knowledge of the development of the face it seems reasonable to conclude that these depressions represent a minimal form of "fissura facialis," a small deficiency in the union of the lateral, nasal, and maxillary processes, which, with the fronto-nasal process, go to form the face. The depressions are exactly in the line of these normally obliterated fissures. The small variability in their positions is covered by the extent of the fissures. The occurrence of the gross form described by Sperling falls into line with this explanation.

In the dissection of many fishes in 1898 * I noted the presence of blind "nasal pouches" at the anterior angles of the eye. They were particularly well marked when, for special purposes, the bony margin at this part of the orbit was deficient, *i. e.*, when the union of lateral, nasal, and maxillary processes was incomplete.

The communication found on the right side of the boy between the opening and the saccus lacrymalis has a bearing of some interest. It was formerly held that the tear duct was formed by the persistence of part of the cleft between the lateral, nasal, and maxillary processes. Born † has, however, shown that in many animals the duct arises after the closure of the fissure, by the formation of a cord-like thickening of the rete mucosa, which sinks into the dermis, and later becomes canalised. On these observations of Born one must suppose that in this boy the fissure closed, the tear duct formed, and the fissure re-

* N. Bishop Harman, "The Palpebral and Oculo-motor Apparatus of Fishes," *Journal of Anat. and Physiol.*, vol. xxxiv, p. 7.

† C. Born, "Die Nasan hohle u. der Thranennasengang der amnioten Wirbelthiere," *Morph. Jahrb.*, 1879 u. 1883.

Digitized by Google

opened and communicated with the duct; on the earlier theory of origin of the duct it is easy to account for the fistulous communication on a supposition of simple failure of union.

The occurrence of the anomaly in mother and child is noteworthy, and the fact that the children were born within a few months of each other in the same block of houses, and did not bear any relationship to each other, is an example of the curious accidents of chance.

(*November 14th*, 1902.)

Mr. Treacher Collins said that it was interesting to note that in all three of Mr. Harman's cases the little sinus was situated at about the same distance from the inner canthus, also that they were situated in a position which corresponded to that in which the "lacrymal sinus" was located in some animals, most markedly in stags and antelopes. This "lacrymal sinus" formed a depression a short distance from the inner canthus and secreted an oily fluid. He had cut sections of the lining membrane, and found in it a quantity of sebaceous glands. If it was proposed in any way to remove the sinuses in Mr. Harman's cases, it would be interesting if a piece of the lining membrane could be obtained for microscopical examination, so that it might be ascertained if it contained an abnormal number of sebaceous glands.

---

5. *A rare form of nystagmus.*

By E. W. Brewerton.

M. U—, æt. 22 years.

Previous history.—Three years ago, when in usual health, patient's friends found her unconscious one morning, and for two hours were unable to rouse her. Patient felt no ill effects, and remembered nothing of this "fit."

Digitized by Google

A few weeks later she had an attack of influenza, and the doctor who attended her drew her attention to the nystagmus. Up till that time only the divergent strabismus of the R. had been noticed.

Present condition.—A varying amount of horizontal nystagmus is present; this is sometimes almost imperceptible. There is external strabismus of the R. All movements excepting convergence are good, but performed in a somewhat jerky manner.

On covering the R. well-marked horizontal nystagmus of both eyes is at once produced, greater in R. than L. When the left or fixing eye is covered, or its fixation interfered with, the nystagmus is extreme, and again greater in R. than L.

Prisms and coloured glasses produce neither nystagmus nor diplopia. With a Maddox rod in front of the L. a slight convergent strabismus is produced in the R. with homonymous diplopia and without nystagmus. The rod in front of R. produces nystagmus at once.

V. with both eyes open = $\frac{6}{9}$. R. alone = $< \frac{6}{60}$, and J. 20 with difficulty. L. alone = $\frac{6}{12}$ partly.

$$\text{R.}\ \begin{array}{c} > +1 \\ -\!\!|\!\!- > +4 \end{array} \qquad \text{L.}\ \begin{array}{c} > +1 \\ -\!\!|\!\!- > +2 \end{array}$$

Fundus normal in each eye.

Patient complains that both nystagmus and squint are increasing.

(*Card specimen. November* 14*th*, 1902.)

---

6. *Two cases of aniridia and one of coloboma of the iris in the same family.*

By Charles Blair and Bernard Potter.

Thos. P—, æt. 37 years, the father of the two cases described below. In the left eye there is a large colo-

Digitized by Google

boma of the iris, down and in, with slight notching of the lens; also fine dotted opacities at the anterior surface of the lens. In the right eye there is a peculiar discolouration of the portion of the iris corresponding to the coloboma in the left eye, which is inactive and unaffected by a mydriatic, while the rest dilates freely.

Florence P—, æt. 14 years, daughter of the above. In the right eye there is an absence of the iris, except a narrow piece internally. The choroid is defective below and internal to disc, where there is a circular, whitish area, about half the size of the disc, near which are other similar but smaller patches. In the left eye there is a similar defect of the iris, with some remains of iris visible on the inner side, but no choroidal defect as in the right eye. There is no deformity or opacity of the lens in either eye; also no glaucomatous cupping or increase of tension.

R. V. $< \frac{6}{60}$, J. 1 with difficulty, $\bar{c}$ $\frac{-10 \text{ D. sph.}}{-1 \text{ D. cyl. ax. hor.}} = \frac{6}{12}$.

L. V. $< \frac{6}{60}$, J. 1 with difficulty, $\bar{c}$ $\frac{-8{\cdot}5 \text{ D. sph.}}{-1 \text{ D. cyl. ax. } 10 \nearrow} = \frac{6}{12}$.

George P—, æt. 11 years, brother of the last case. In the right eye the iris is apparently entirely absent. The lens is deficient at its lower edge, and has an anterior pyramidal cataract. In the left eye the iris is absent, except at the upper and inner part, where some slight remains are visible. There is in this eye also an anterior pyramidal cataract. Both corneæ are clear, and there is no history of any inflammatory affection in infancy or later. There is a marked cupping of each disc, but it does not seem to extend over the whole papillary area. No ciliary processes can be seen.

R. V. $< \frac{6}{60}$, J. 4, $\bar{c}$ $\frac{-10 \text{ D. sph.}}{-6 \text{ D. cyl. ax. } \nearrow} = \frac{6}{60}$.

L. V. $< \frac{6}{60}$, J. 2, $\bar{c}$ $\frac{-7 \text{ D. sph.}}{-6 \text{ D. cyl. ax. } 160 \nwarrow} = \frac{6}{18}$.

Tension normal.

(*Card specimen. December 11th*, 1902.)

Digitized by Google

7. *Congenital malformation of lower eyelids.*

By F. A. C. Tyrrell.

History.—George W—, æt. 16 years, is stated to have had this peculiar condition of the eyes since birth. There is no history of any congenital abnormality in other members of his family.

Description.—This patient shows in a very slight degree an arrest of development of the lower portion of the orbit and lids. There is a slight indication of a notch in each lower lid, more marked in right eye near outer canthus. The malar prominences are poorly developed, causing a noticeable flattening of the face in the region of the deformity. The face, as a whole, is somewhat better developed on the left side than the right.

The refraction is normal. V. = $\frac{6}{6}$, and J. 1. No abnormality in fundi, except a slight notch at outer side of right disc. (*Card specimen. January 29th*, 1903.)

---

8. *A child with multiple deformities of the eye, eyelids, etc.*

By Robert W. Doyne.

Rose Gertrude F—, æt. 2 years. Examined May 7th, 1903.

No family history of any deformities. The patient's two brothers, aged respectively eight and four years, have nothing amiss with them. The patient was born at term, with a lump in the corner of her right eye, a swelling of the corresponding lid, and a discharge from the eye.

Present condition.—R.: a deep triangular cleft present in the upper lid, at the junction of the inner third with the outer two-thirds of the latter. A second cleft, down and in, occupies the position of the inner canthus at the junction of the two lids. The puncta lacrymalia are present and patent. There is a coloboma of the iris down and in, and, upon ophthalmoscopic exam-

Digitized by Google

ination (no easy task), a coloboma of the choroid is seen in a corresponding position. The interval between the inner canthus and the nose is occupied by an elastic swelling, the distended lacrymal sac. This portion of the face is obviously much widened as compared with the other side. From the inner canthus of the right eye to the mesial point of the root of the nose measures 22 mm. on the right side and 15 mm. on the left side. The right side of the nose is dwarfed, and the right nostril is only large enough to admit the end of a hair-pin. On pressing over the right lacrymal sac there is a flow of muco-pus from (*a*) the puncta lacrymalia of the right eye, and (*b*) the right nostril. Beyond a highly arched palate, there is no other deformity or peculiarity to be found about the child. (*Card specimen. May 8th*, 1903.)

---

9. *A case of deformity of the head, and proptosis.*

By E. Donaldson (Londonderry).

(With Fig. 14 in text.)

A little boy, æt. 2½ years, was brought to me by his parents on the 16th March, 1903, on account of prominence of the eyeballs. There was nothing in the family history to throw light on the case. The patient was the youngest of three children, the other two having no deformity. He was born at full time, after a rather tedious labour, without instrumental aid. The proptosis was present at the time of birth, and the child's Mother did not think it had increased since. The projection of the eyes was not only unsightly but a source of some anxiety. On about half a dozen occasions the right eye came well outside the eyelids, so that the child's father was obliged to push it back by gentle pressure with a soft handkerchief, at the same time throwing the head back. Moreover, the eyes from their position were subject to slight knocks.

Digitized by Google

When I saw the child he could walk well, and he seemed in fair health and of average intelligence, and his muscles could not be called flabby, although he showed some signs of mild rickets, *e. g.*, slight beading of the ribs and sweating of the head. This derangement of the health was not surprising, as his mother was still suckling him. His height was about two feet eight inches, and his hearing was good. The proptosis and the misshapen forehead, two leading features of the case, are well shown in the accompanying photograph (see Fig. 14). When the eyes were in the primary position, or as nearly as it was possible to get them, the margins of the upper eyelids just touched the tops of the corneæ, and in some other positions of the eyes the sclerotics were exposed above the corneæ. There was horizontal nystagmus of short range in each eye. Patient could shut his eyes, and did so when told.

FIG. 14.

The eyes were capable of considerable movement to either side, up and down, and could converge, but usually there was some divergence, especially in right eye. No

Digitized by Google

pulsation could be felt in the eyeballs, and they could not be pushed back into the orbits. I felt the upper margins of the orbits and the upper orbital walls as far as I could with my finger, but could not be sure of deformity in this region. The forehead was high, its sides were depressed, its centre projected, resembling somewhat the keel of a boat. The coronal suture could easily be felt and traced by the finger, and the anterior fontanelle was closed. When the hand was placed on the top of the head the upper part of the forehead was felt to be distinctly raised and keel-shaped. The following measurements were taken:—circumference of the head just above the ears 18½ inches, between the ears over vertex 10½ inches, arc from root of nose to occipital protuberance 12¾ inches, arc from root of nose to anterior fontanelle 5½ inches. Sight was defective, as shown by his not recognising objects at some distance from him, but he could see well enough not to knock against objects in the room. There was no opacity of the corneæ, and there was considerable pallor of the optic discs. I ascertained from the nurse that during sleep the corneæ were nearly covered by the upper eyelids. The palate was highly arched. The great toes were broad, and hallux varus was present on each side.

As regards treatment, the diet was altered, and I suggested tarsorrhaphy on right side, but did not insist on it as the displacement of right eye was said to occur less often than formerly.

Remarks.—When trying to make a diagnosis in this case one could with confidence exclude pulsating exophthalmos, exophthalmic goitre, hydrophthalmia, myopia, protrusion from swellings, and tumours. When I first saw the child I was reminded of Mr. Henry Power's case in the *Transactions of Ophthalmological Society*, vol. xiv, p. 212. The deformity in my case is not nearly so great, but I think it is of the same nature. If so, the proptosis would be caused by shallowness of the orbits, arising from premature synostosis in the way pointed out by Mr. Swanzy in the *Transactions of Ophthalmological Society*, vol. xviii, p. 15.

Digitized by Google

The deformity of the head present in the foregoing case is known as oxycephaly. (*May 8th*, 1903.)

---

10. *Case of congenital maldevelopment of the cornea and sclerotic.*

By Leslie Buchanan, M.D. (Glasgow).

A. M'C—, a girl æt. 9 years, whose eyes exhibited this unusual form of maldevelopment, was brought to the Glasgow Eye Infirmary on account of an injury to the left eye. Owing to the severity of the injury (a corneal wound inflicted by iron wire), the eye was excised a few days later. During the operation, the eyeball collapsed, its contents being very completely extruded.

When the remains of the eye were examined, the cornea and sclerotic were found to be very unusually thin, the former being estimated at *three-fifths* and the latter at *one-third* the normal thickness.

The child's right eye presents appearances which are very striking. The globe is of the normal size in all respects so far as can be seen, but the sclerotic is bright blue in colour, about the same tint as a very thin ciliary staphyloma. The colour is uniform, however, and is clearly not the result of local distension. The conjunctiva is freely movable, and the pigmentation is manifestly beneath it. The tension of the eye is normal, but the sclerotic gives the impression of being very thin. The cornea of this eye is found to be conical in a moderately high degree, and the refraction of the eye is myopic about 6 D.

Histological examination of the excised eye shows that whilst the fibres of which the cornea and sclerotic are formed are of about the normal size, they are abnormally few in number.

The corneal epithelium is normal. The anterior elastic lamina is completely absent over all parts, the defect

Digitized by Google

being evidently the result of congenital maldevelopment, not of injury. The cornea has only about half the usual number of fibres in its thickness, so that the epithelium on its anterior surface appears to be unusually thick. The posterior elastic lamina is normal, but the endothelial layer which usually covers its posterior surface is absent, probably having been removed during excision.

The sclerotic is proportionately thinner than the cornea, being so slender that the addition of the tendon of the internal rectus muscle fully doubles its thickness.

The child's parents are quite certain that the eyes presented precisely similar appearances before the left was injured, both being blue in colour, and also that the eyes were of the same colour at birth, and have shown no tendency to change since then.

Remarks.—The condition here present is evidently a very uncommon one, and is most satisfactorily explained by the assumption that it is due to a congenital defect of development.

The complete absence of anterior elastic lamina is a very striking feature, and presents several points of embryological as well as clinical significance.

Although the condition has been previously noticed clinically, no histological examination has been made.

The only references which can be found in literature are by von Ammon, Wilde, and Warlomont.

Von Ammon depicts an eye which presented appearances closely similar to those seen in the right eye of A. M'C— in his *Klinische Darstellungen der Krankheiten und Bildungsfehler*, T. iii, Taf. xv, No. 2.

Wilde, in *On Malformations and Congenital Diseases of the Organs of Sight* (p. 43), says, "But there are instances on record in which the conjunctiva has been observed of a dark blue colour in the white races." He is here very probably referring to the same condition as is present in A. M'C—.

In the French edition of McKenzie's work on *Diseases*

Digitized by Google

of the Eye, vol. ii, p. 509, it is noted that "the sclerotic presents sometimes, it may be as a whole or only in parts, a thinning, which gives it a blue colour. An arrest of development quite adequately explains this defect, which is often accompanied by other congenital defects of the eye."

No case can be found, however, recorded in recent literature.

(*Card specimen. March 13th*, 1903.)

Sections of the cornea and sclerotic were shown under the microscope.—*Editor.*

11. *A case of microphthalmos, etc.*

By Robert W. Doyne.

The patient, a girl æt. 13 years, is not bright mentally. R. V. No. 16 J., and fingers at 1 mètre. L. V. less than No. 20 J., and hand-reflex. The sight is stated always to have been defective. The corneæ are small, measuring about 9·5 mm. (transverse diameter). There is nystagmus. T. n. Coloboma of the right iris inwards, and of the left iris inwards and upwards. There are opaque striæ in the right lens, but a fundus-reflex can be obtained with the ophthalmoscope mirror. The left lens is wholly opaque. (*Card specimen. May 8th*, 1903.)

12. *A case of congenital defect of movement of one eye associated with a slight degree of enophthalmos.*

By Herbert L. Eason.

W. F—, æt. 5 years, attending at the Royal London Ophthalmic Hospital as a patient of Mr. E. Treacher Collins for defective movement of the right eye. The defect is on

Digitized by Google

one side only, has existed since birth, and no other member of the family suffers from any similar defect.

When the child looks straight forward it is noticed that the right eye diverges slightly, and is sunken to a small degree. There is slight ptosis of right lid. When the patient looks up with the left eye the right eye does not look upwards, but turns inwards and becomes distinctly more retracted. The lid remains stationary. On looking down with the left eye the right eye rotates a little in the direction of the hands of the clock, and turns down and out and a little forward. There is no movement of the right eye towards the left. On looking to the right, the right eye moves outwards to the same extent as the left, but the ptosis becomes more marked. Patient has some hypermetropic astigmatism, and with glasses R. V. = $\frac{6}{12}$; L. V. = $\frac{6}{18}$. Pupil and light reflexes normal.

Remarks.—The case is apparently one of congenital defect of that part of the third nerve supplying the extrinsic muscles of the right eye, omitting the fibres supplying the iris and ciliary muscle. The lesion is therefore probably nuclear, and is in the nature of a non-development of the cells in that part. There is no history of injury at birth: the labour was simple, and no instruments were used.

Many cases of congenital ocular defects have been described, notably by Lawford (1), Heuck (2), Hirschberg (3), Maclehose (4), Julius Wolff (5), Alling (6), and Knapp (7), but the case most nearly resembling the present is one mentioned by Mr. Silcock at the close of Mr. Lawford's paper at the Ophthalmological Society, in which there was paralysis of the muscles supplied by the third nerve on one side only. The eyes were normal in early childhood in that case, so the lesion was probably due to a condition similar to infantile paralysis. The cause of the enophthalmos is doubtful. In a paper on the subject in 1899 Mr. E. Treacher Collins (8) suggests the possibility of the absence or faulty insertion of the check ligaments.

(*Card specimen. June 11th*, 1903.)

Digitized by Google

REFERENCES.

(1) *Trans. Ophth. Soc.*, vol. viii, 1888, p. 262.
(2) *Klin. Monatsbl. f. Augenheilkunde*, July, 1879.
(3) *Klinische Beobachtungen*, 1874.
(4) *Trans. Ophth. Soc.*, vol. xvi, 1896, p. 299.
(5) *Archives of Ophthalmology*, vol. xxix, p. 297.
(6) *Ibid.*
(7) *Ibid.*
(8) *British Medical Assoc.*, Section of Ophthalmology, 1899.

Mr. N. BISHOP HARMAN said there appeared to be some action of retraction of the lid, and since the levator palpebræ superioris is developed from the rectus superior, the existence of the levator palpebræ argued the existence of the rectus superior. In some fishes (*e. g.*, herrings) one or more of the ocular muscles are shortened and attached to the eye beside the optic nerve. Possibly that condition might be present in this patient. The eye muscles might be there but attached to the posterior pole of the globe. That would account for the retraction of the eyeball, and also for the partial movements of the lid in the lateral displacement of the eye. He did not know whether such a condition had been examined after death, but he had found it in fish where the eyeball was too large for the cavity in which it had to grow, so that the muscles did not grow and pass round to the proper attachment.

Mr. H. L. EASON, in reply, said he believed there was no reason to suppose that the lesion should not be in the nuclei at the base of the brain, for the cause of paralyses of the extrinsic muscles of the eye supplied by the third nerve, the pupillary reflex for light and accommodation being left intact, was generally found to be in those nuclei. The cells might be defective congenitally, and it was possibly analogous to a congenital monoplegia. In the one case where a *post-mortem* examination had been made the condition mentioned by Mr. Harman did exist, the muscles being inserted too far back.

Digitized by Google

13. *Coloboma of the optic nerve sheath, with microphthalmos.*

By L. Werner, M.B.(Dublin).

Margaret E—, æt. 19 years. Twelve months ago discovered that sight of right eye was defective; it was never as good as left, and was always smaller than the latter. All other members of the family have good eyes, as far as she knows.

Present condition (February 3rd, 1902).—Right slightly divergent. Cornea and whole eyeball smaller than normal. Palpebral opening narrowed. Diameter of cornea horizontally = 10 mm., and radius of curvature = 8 mm. in meridian of lowest refraction, 7·5 mm. in the other. Astigmometer 6 D As. $/^{30°}$. Retinoscopy + 5 cyl. $/^{30°}$. V. = fingers at outer side. L.: transverse diameter of cornea 11·5 mm. V. = $\frac{6}{12}$. Slight H. As. O. D. rather white, and upper margin slightly indistinct.

Ophthalmoscopically.—Right eye (in erect image) shows the following condition. O. D. replaced by a large deep excavation, with partly pigmented border, measuring four disc-diameters vertically. The lower edge of the pit is narrow and rounded, and a few small retinal vessels curve round it, but their origin is invisible, as the lower part of the excavation dips down and is hidden from view. The upper wall slopes backwards from the edge above, and stops rather abruptly almost halfway down, to form the boundary of a deeper cavity, inside which and to the left is a still smaller, grey, depressed area. A large retinal vessel springs from the inner side of the coloboma above the centre. The colour of the excavation varies from a brilliant white to a pearly grey, and here and there a pink vascular tinge is visible near the surface. This is a minor degree of the same condition which leads to the production of anophthalmos with congenital cyst of the lower lid. In

Digitized by Google

coloboma of the nerve-sheath, the cystic excavation is usually most pronounced below.

(*Card specimen. January 29th*, 1903.)

---

14. *Chorio-vaginal veins in the myope and hypermetrope.*

By W. Ernest Thomson, M.D., and A. J. Ballantyne, M.D.

It has been stated by Oeller (1) that "venæ vorticosæ chorio-vaginales" are of rare occurrence, and by Haab (2) that "as these vessels do not appear to occur in albinos or in any poorly pigmented eye unless it is myopic, we may assume that they have some connection with myopia."

We have each seen several cases in which a larger or smaller number of veins in one or both eyes converged towards the sheaths of the optic nerves, and we here exhibit the fundus appearances of two hypermetropes and one myope presenting this condition.

No. 1 is the right eye of a myope of 6 D. with astigmatism (Maggie Y—). Five choroidal veins converge towards the disc, one of which can be traced across the crescent to disappear alongside the nerve. The other fundus is almost exactly similar. Corrected V. = $\frac{6}{9}$ R. and L.

No. 2 is the left eye of a hypermetrope of ·50 D. (Jas. D—). Five or six choroidal veins converge towards the disc, most of which manifestly run backwards close to the nerve. Two of these veins are seen to cross the white temporal crescent, somewhat as in Case 1. In the R. the condition seemed to be similar, but the choroidal vessels could not be so easily traced. The patient was suffering from tobacco amblyopia.

No. 3 is the right eye of a hypermetrope of 1·5 D. (Alex. U—), both of whose fundi were very little pig-

Digitized by Google

mented. In both eyes the choroidal veins were well mapped out, and appeared to converge towards the disc, but only in the R. could any of them be actually traced up to the disc edge. It is to be presumed that but for the increased amount of pigmentation towards the temporal side other veins than those actually observed would be found to take a similar course. R. V. = $\frac{6}{5}$, L. amblyopic.

While admitting that abnormalities seem to be particularly prone to occur in the myope, we would suggest that "posterior venæ vorticosæ" or "chorio-vaginal veins" may be observed with moderate frequency in poorly pigmented fundi, whether myopic or not.

References.

(1) Oeller.—*Atlas seltener Ophthalmoskopischer Befunde*, 1900.

(2) Haab.—*Atlas and Epitome of Ophthalmoscopy*, 1901.

(*Card specimen. June 11th*, 1903.)

---

15. *Congenital bilateral pigmentation of the cornea.*

By W. Ernest Thomson, M.D., and A. J. Ballantyne, M.D.

This rare condition is apparently identical with that described by Krukenberg,* and by Stock.†

Agnes W—, carpet setter, æt. 22 years, complains of defective vision. R. V. $\frac{5}{60}$, L. V. $\frac{2}{36}$; J. 1 with either.

In the middle of each cornea there is a faint brown vertical line. On oblique illumination, especially when assisted by magnification, it is seen that this line is com-

* Three cases, *Klinische Monatsblätter für Augenheilkunde*, 1899, pp. 254, 478.

† Two cases, *Klin. Monats. f. Augen.*, September, 1901.

Digitized by Google

posed of a great number of minute, chocolate-coloured dots. The largest and densest mass of dots is opposite the centre of the pupil. From this point downwards for a distance equal to one-fourth the corneal diameter the dots are fewer and spread out like the tail of a comet, the centre of the tail being denser than its edges. The pigment is interstitially placed, but its exact depth is difficult to determine.

Close questioning of the patient and of her Mother elicits the definite statement that never at any time has there been any inflammation of the eyes, except styes in childhood. Inquiry as to difficult labour, such as might account for a traumatic keratitis, reveals the fact that labour was particularly easy. No trace of iris-adhesion, indicating a previous irido-keratitis, can be found. The iris is normal in every respect, and there are no visible remains of a pupillary membrane. There are no vitreous opacities.

Ophthalmoscopically.—There is a partial coloboma of each disc. The refraction is myopic without any irregular astigmatism, and the pigmentation does not prevent a perfect view of the fundus. After correction V. = $\frac{6}{9}$ with either eye.

Remarks.—That the condition is a congenital one seems certain, because:

(1) The symmetry is perfect.

(2) The dots are all of the same size.

(3) The dots are interstitial, and not on the posterior corneal surface.

(4) There are no indications of former inflammation.

(5) The eyes are myopic, and present a congenital anomaly of the discs.

The exact cause of the pigmentation is obscure. Krukenberg, basing his opinion largely on the fact that in two of his cases the colour of the irides was the same as that of the corneal pigment (*viz.*, chestnut colour), while in the third case the pupillary region of the iris had a brown colour, concludes that the anomaly has some con-

Digitized by Google

nection with the development of the anterior part of the uveal tract. In our case, however, the irides were light coloured throughout. Krukenberg is unable to offer any explanation of the constant vertical position of the *Pigmentspindel.*

It is worthy of note that in all four cases (Krukenberg's and our own) the refraction is myopic, and that in two of them there is a congenital abnormality of the disc.

The absolute correspondence of the main features of the four cases indicates that we have here a condition dependent on a definite and constant cause.

(*Card specimen. June 11th,* 1903.)

---

16. *Congenital (? and hereditary) development of choroidal tissue in the optic nerves of two brothers.*

By W. Ernest Thomson, M.D., and A. J. Ballantyne, M.D.

Two brothers (William McG— and Matthew McG—) presented themselves at the Glasgow Eye Infirmary on the same day complaining of short-sight. Both were found to be myopic, and both presented a bilateral fundus appearance of choroidal tissue in the temporal third of the optic nerves. In the right eye of Matthew, the pigment is densest, and in this eye the choroidal vessels can be distinctly traced over on to the optic nerve. In all four eyes the fundus pigment to the temporal sides of the nerves is much disturbed. The amount of myopia in M. McG— is 10 D., and distant vision corrected is only $= \frac{6}{24}$.

The Father and an elder brother of these patients were found to have normal eyes. The Mother and another brother could not be examined.

(*Card specimen. June 11th,* 1903.)

Digitized by Google

Digitized by Google

PLATE XVI.

FIG. 1 illustrates Drs. Thomson and Ballantyne's case of Crater-like Hole in the Optic Disc (p. 277).

FIG. 2 illustrates Drs. Thomson and Ballantyne's Pigmented Coloboma of the Optic Disc (p. 277).

Digitized by Google

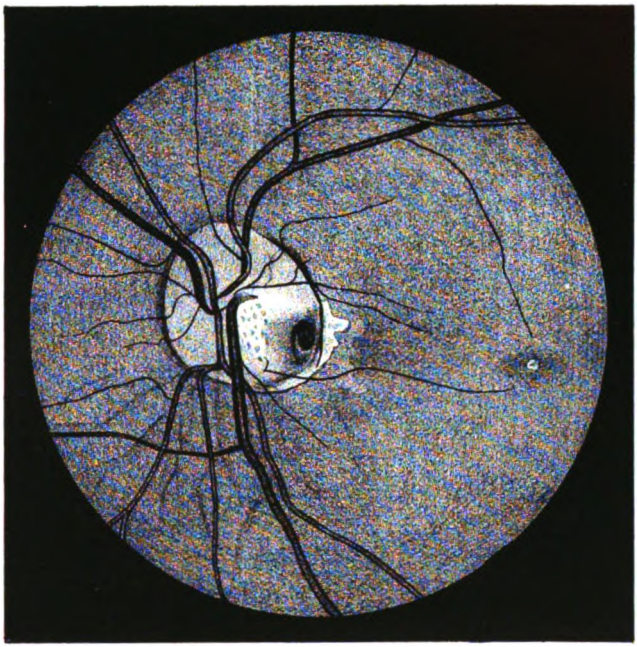

Fig. 1.

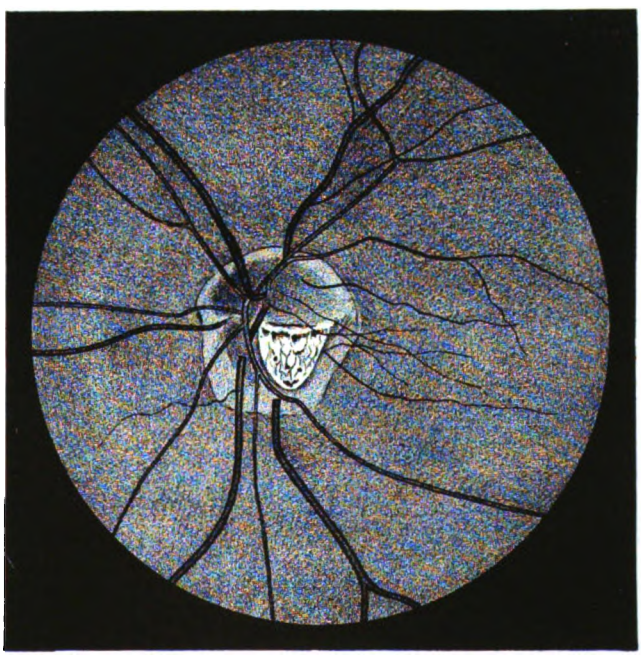

Fig. 2.

Digitized by Google

Digitized by Google

17. *Crater-like hole in the optic disc.*

By W. Ernest Thomson, M.D., and A. J. Ballantyne, M.D.

(With Plate XVI, fig. 1.)

Myope (Jas. McL—). Right eye 2 D., left eye 6 D.; presents an unusual appearance of the left disc. The disc itself appears as if it were unduly extended to the temporal side, and in this particular portion there is a vertically oval area, about one-third the disc's diameter in length, which presents a gradation of shading from circumference to centre. That this appearance represents an actual hole is proved by focussing. The R. disc is normal. Corrected V. = $\frac{6}{6}$, R. and L.

(*Card specimen. June 11th,* 1903.)

---

18. *Pigmented colobomata of the optic discs.*

By W. Ernest Thomson, M.D., and A. J. Ballantyne, M.D.

(With Plate XVI, fig. 2.)

A myope of 9 D. (Mrs. G—) presents two very unusual optic papillæ. In the R. the disc presents the appearance as if a wedge had been cut out of its outer and lower portion. This coloboma-like wedge contains a *network* of brown pigment, situated 1 D. below the level of the disc surface. The pigment has somewhat the "bone corpuscle" arrangement of retinal pigment in retinitis pigmentosa, but is distinctly brown in colour. In the L.

Digitized by Google

(see Plate XVI, fig. 2) the pigment is similar, but instead of extending to the very edge of the disc it is separated from it by a narrow band of nerve tissue. The emergence of some of the veins through canals in the nerve is also peculiar. Round the greater part of this disc there is an area of partial choroidal atrophy. The vision comes up well with glasses.

(*Card specimen. June 11th*, 1903.)

Digitized by Google

XIII. INJURIES.

1. *Thrombosis of the inferior temporal branch of the arteria centralis retinæ in an eye with a persistent hyaloid artery and vein; ? caused by exposure to direct sunlight.*

By Cyril H. Walker.

(With Fig. 15 in text.)

F. H. B—, a healthy man, æt. 22 years, had never noticed any defect of vision until October 4th, 1902. Whilst singing in the choir at a musical festival rehearsal, he suddenly noticed a dazzling sensation in the right eye. At the same time he noticed that the upper half of every object he looked at was indistinct. It was a bright afternoon, and for more than an hour direct sunlight fell on his eyes as he faced the conductor. The patient has practically had no illness, and with exception of the exposure to sunlight there is no discoverable cause. Since this occasion he has always noticed a positive scotoma in the upper part of his right field of vision, which has not altered in any way.

On examination R. V. $= \frac{6}{6}$; L. V. $= \frac{6}{5}$. Pupils equal and normal. In the right eye there is a persistent hyaloid artery and vein. These vessels apparently spring from the inferior division of the retinal vessels and run forward into the vitreous, so that the summit can be seen with a + 14 D. lens. The vessels are twisted like the strands of a rope, so that the apex of the loop has undergone two complete revolutions. The light and dark columns of blood of the artery and vein respectively, running in their glistening sheaths, pulsate distinctly, and are about as large as the nasal branches of the retinal

Digitized by Google

vessels. The lens and anterior portion of the vitreous are normal. The retina presents a large patch of swelling, extending from the inferior retinal vessels to the lower edge of the macular halo, and for a similar distance towards the temporal side of the macula. The upper edge of the swelling is abrupt; below it shades off gradually into healthy-looking retina. A much dis-

Fig. 15.

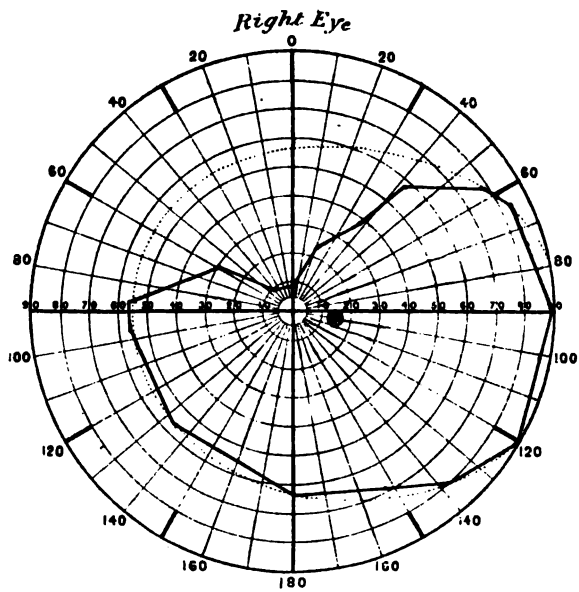

tended artery and vein (the inferior temporal branches) lie upon this white area, and about fifteen small tortuous twigs from them converge towards the macula. Two small and very tortuous vessels are conspicuous, close to the lower and outer margin of the disc. All the remaining retinal vessels are considerably distended. No obstruction of any vessel is visible: the bifurcation of the inferior retinal vessels is hidden by the hyaloid vessels. The general appearance of the area of œdema closely resembles that depicted in fig. 26 of Haab's *Atlas*

Digitized by Google

of Ophthalmology. The field of vision corresponds pretty closely with the area of retinal œdema. The left eye is normal in every respect.

November 23rd, 1902.—The patient has been seen on several occasions, on each of which the field showed practically the same defect. L. V. $\doteq \frac{6}{6}$; slight micropsia. The swelling of the retina is slowly subsiding, but the small tortuous vessels near the lower and outer side of the disc are getting more conspicuous. Patient is at work, and experiences very little discomfort.

(*October 16th*, 1902.)

---

2. *Traumatic dislocation of eyeball forwards through the palpebral opening; immediate reduction by taxis; complete recovery.*

By H. Clifford Baldwin (Huddersfield).

(Communicated by E. Nettleship.)

In October, 1897, Mrs. M—, æt. 40 years, was coming up the cellar steps when she struck the left side of her face against the triangular globe-holder of a gas-bracket (the globe had been removed). She felt the prong of the holder strike against the outer side of the eyebrow. I saw her within fifteen minutes of the accident, and found the left eyeball driven forwards out of the orbit in front of the eyelids. The lids had the appearance of having closed on the posterior aspect of the globe; the eye was simply "gouged out," and the patient told me afterwards that she had had to hold the eye up with her hand until I came. There was no wound of any of the tissues of the eyeball, and neither wound nor abrasion on the face or side of the head. With gentle taxis I reduced the dislocated globe, and felt it spring back into the orbit with an elastic click.

Digitized by Google

The patient was put to bed in a dark room, and iced compresses were applied to the eye. She remained in bed in the dark for a fortnight, and for some three months afterwards wore smoked goggles. There were never any inflammatory or untoward symptoms, and after the disappearance of a slight blood extravasation on the outer side of the eyeball, the only visible result of the accident was a crinkled appearance at that part, as if some of the structures of the globe had been stretched. The eye was weak for some months, and the patient complained of darting pains in the other (right) eye; indeed, she said that the uninjured eye gave her more trouble throughout than the dislocated one.

I have seen Mrs. M— several times since the accident, and as recently as last July (1902). On that occasion I examined the eyes carefully, and found vision perfect in each eye, both for near and distant types, and the refraction normal. The eyes were not prominent, and there was nothing in the contour of the orbits to suggest that they were shallow, or the eyeballs predisposed by any anatomical peculiarities to come forwards. The slightly crinkled appearance on the outer side of the globe that was observed soon after the accident was still present, but no other trace remained.

(*October 16th*, 1902.)

Mr. W. M. Beaumont said he had seen one case comparable to that of Mr. Baldwin's in an infant which was brought to him when twenty-four hours old with a dislocated eye. Forceps had been used during delivery. The eye was easily reduced, and, except for some chemosis and swelling of the orbital tissue, there was not much harm done. For some time there was a nebulous condition of the cornea, but it cleared up. His theory was that the blade of the forceps had acted much in the same way as a speculum acted when an operator dislocated an eye forwards during enucleation.

Digitized by Google

3. *Traumatic separation of the ciliary body, due to rupture of the pectinate ligament.*

By LESLIE BUCHANAN, M.D. (Glasgow).

THIS somewhat uncommon injury has been present in five eyes examined in the pathological department of the Glasgow Eye Infirmary during the past eight years.

The cause of the injury in the various cases was as follows:

(1) The use of a scoop during the removal of a dislocated lens.

(2) A blow from a leaden pellet.

(3) A blow with a leather belt.

(4) A blow with a chip of iron.

(5) A blow with a wooden box.

The condition probably occurs in the following manner:—Owing to a blow on the front of the eye, usually with a blunt object, the corneo-scleral junction is much indented. The pectinate ligament is thus subjected to severe stretching, and is torn near its insertion into the cornea. The point of firmest adhesion of the ciliary body being thus loosened, that structure slips backwards away from the corneo-scleral junction, leaving a crescentic portion of sclerotic exposed. The iris may be torn from the ciliary body or may remain adherent to it, the exact nature of the force probably being the determining factor.

The ciliary body, being thus separated from the sclerotic, will be still further removed by the passage of aqueous humour into the space which is continuous with the anterior chamber. If no inflammatory reaction results, the ciliary body will remain in its unnatural position; but if the reaction be severe, and inflammatory exudation be formed between the sclerotic and the choroid, the contraction of the exudation will have the effect of drawing the ciliary body towards the sclera again, and re-attachment will be effected.

Of the five cases seen, re-attachment had taken place in

Digitized by Google

three (Nos. 3, 4, and 5). The extent of the rupture of the pectinate ligament varied from a quarter to a half of its peripheral extent, so that a portion of ciliary body, from a quadrant to a semicircle in extent, was separated. In two cases the iris was not torn from its ciliary attachment (Nos. 1 and 2). In one it was almost completely separated, whilst in the others there was partial irido-dialysis.

In the cases in which re-attachment had taken place the medium of fixation was plastic inflammatory action, and the portion of sclerotic exposed was more or less completely covered by newly-formed fibrous tissue.

There was no external wound of the eyeball in three cases (Nos. 2, 3, and 5). The lens was dislocated in all the cases, and there was hæmorrhage into the vitreous.

In the instance in which the use of a lens-scoop was the cause of the injury, it is presumed that the ciliary body was drawn forwards from below as it was separated below, although the extraction was by superior section.

The *clinical recognition* of the condition is very uncertain, as there is extensive hæmorrhage into the anterior chamber. At a later stage, however, when the blood is absorbed, two signs of some importance may be looked for. If re-attachment does not occur the anterior chamber may be found to be unusually deep at one part, whilst if re-attachment is effected the iris will be found to be drawn behind the corneo-scleral margin, and may ultimately disappear almost entirely from one side of the anterior chamber.

In Case 3, for instance, which was seen clinically a few hours after the accident, there was a radial rupture of the iris, and although the pupil was moderately wide at first, it became more dilated afterwards in spite of the free use of eserine. On the tenth day after the accident the iris could not be seen at all at the nasal side, where the separation was subsequently found, but by the twentieth day it had reappeared to a slight extent. A state of glaucoma supervened, owing probably to obstruction of the filtration area by inflammatory exudation. Glau-

Digitized by Google

coma also supervened in Case 4, whilst in the remaining cases the eye became atrophic.

Two references only to this subject can be found in literature. Mr. E. Treacher Collins* first described the condition in connection with a case of Mr. Lang's. Praun† refers somewhat obscurely to the occurrence of the condition in connection with cases of rupture of the sclerotic.

(*Card specimen. March 13th*, 1903.)

The PRESIDENT (Mr. William Lang) had seen a condition such as was described by Dr. Leslie Buchanan follow an injury to the eye.

---

4. *Concussion injury; coloboma of disc.*

By G. H. GOLDSMITH.

H. B—, æt. 36 years, stage carpenter, was shifting scenery on February 15th, when he was struck in the right eye by a sharp piece of timber. The upper lid was injured and the wound stitched up at once. Patient knows his sight was good previous to the accident, as he was constantly using the right eye alone. First seen March 7th.

V. = fingers at 2 feet. Refraction at macula $-\left|\begin{matrix}-+\ 1. \\ +\ 0{\cdot}25.\end{matrix}\right.$

Fundus.—About one disc-diameter to the outer side of the macula is a patch of disturbance about the size of the disc, surrounded by a pale halo. Within this is a ring of irregularly grouped masses of pigment, succeeded by an area showing choroidal vessels and the white sclera. A vessel from the disc courses over the patch, and a vein leaves its upper and outer angle. There are many retinal hæmorrhages as well as linear hæmorrhages in the vitreous.

The disc.—The outer and lower third of the disc is occu-

* *Researches into the Anatomy and Pathology of the Eye*, 1896.

† *Die Verletzungen des Auges*, Wiesbaden, 1899.

Digitized by Google

pied by a deep cavity with an oval outline, bounded at its retinal margin by a bright white band as broad transversely as the diameter of an artery on the disc. A vein curves sharply over the edge of the hole at its lowest point, and cannot be traced farther; two small arteries also leave the cavity. The bottom of the hole cannot be illuminated, but there are faint indications of terracing on its upper and outer wall just below the general level of the disc; for the rest, it is filled with a bluish darkness. (*Card specimen. March 13th,* 1903.)

The PRESIDENT (Mr. W. Lang) said he brought forward a case which was recorded in the twenty-first volume of the *Transactions,* with an illustration. It was described as rupture of the lamina cribrosa and optic nerve-fibres of the papilla. The accident was caused by a clothes-prop being thrust against the lower lid and driving the eye upwards. The present accident appeared to have been caused in much the same way. The rupture in Mr. Goldsmith's case was a little more outwards than in his own. Mr. Goldsmith had not mentioned the condition of the field of vision, which was of importance for diagnostic purposes. In his own case the field of vision showed that the nerve-fibres were torn across, so that the upper part of the field, corresponding to the rupture below, was absent. The field of vision in his (the President's) case remained stationary. He hoped Mr. Goldsmith would bring the patient up again. It would be interesting to have a drawing made.

Mr. W. ADAMS FROST inclined to the view that it was a congenital malformation. It presented a feature common to most such cases—namely, a difficulty in defining the floor of the excavation. A somewhat similar appearance is depicted in a case published by him in 1896.*

Mr. R. W. DOYNE, who had seen a similar case, agreed with Mr. Frost's view.

The PRESIDENT said he had seen the cases referred to by Mr. Doyne and Mr. Adams Frost, but the holes in them

* *Fundus Oculi*, p. 83, fig. 35.

Digitized by Google

had been round, and not slit-like. But, until the state of the field of vision was ascertained, one would not say definitely that it was a rupture. If the field corresponding to the apparent rupture were missing, he would regard it as rupture.

---

5. *A case in which paralysis of the right sixth and seventh nerves was present at birth in a child delivered by forceps; recovery.*

By E. Nettleship.

This female infant, the firstborn, was delivered at full time by forceps after a labour that lasted twenty-four hours, and was specially difficult owing to early rupture of the membranes, a brow presentation, and a pelvis rather narrow in the antero-posterior diameter. The Mother's age was thirty years. One blade of the forceps was applied behind the right ear, its anterior limb leaving a vertical mark on the mastoid region; the other blade was partly on, partly in front of the left ear, its posterior limb leaving a mark on the external ear. The head was squeezed into a somewhat conical shape by the pelvic brim, and there was a large caput succedaneum. The child was of good colour, and cried immediately after birth. There was no swelling of the eyelids, and little, if any, extravasation on the eyes.

Almost immediately, before the doctors left the house, it was seen that the infant's right eyelids remained open when the left ones were closed, and that the right eye squinted strongly inwards. During the next few hours some spasmodic twitching of the hands and arms occurred, but this soon ceased, and no other symptoms followed.

The birth took place early on 9th January, 1902. I saw the baby on the 12th, when just three days old, and found paralysis of all the right facial muscles, including the frontalis and orbicularis oculi, with inward squint of

Digitized by Google

the right eye. The squint was extreme, no sclerotic being visible on the nasal side; and, although the eye did sometimes move out a little, it certainly never passed the middle line. The associated inward and outward rotation of the other (left) eye was full and often rapid. The pupils acted promptly to light, but the range was only from about 2·5 mm. to 3 mm. No extravasation was visible either on the eyeball or eyelids of the right (paralysed) eye, but there was a small one on the left eyeball. No swelling of lids and no proptosis.

A more detailed examination was made on the 14th (baby then five days old). The paralyses were unaltered; the fifth nerve seemed equally sensitive to pin-pricks on each side; the child took no notice of noises with either ear; the twitchings of the hands and arms had ceased; there were no signs of hemiplegia. The pupils dilated to 5 mm. under homatropine and cocain, and the central parts of the fundi were well seen by the indirect method. There was a single, roundish, dark hæmorrhage just below the optic disc (true position) of the right (paralysed) eye equal to about one-third the optic disc area. Both optic discs were clear and of good colour, and the retinal vessels normal; no hæmorrhage was seen in the left fundus.

Just behind the right ear (paralysed side), and running parallel to its length, a slightly elevated ridge could be felt, and behind the ridge a shallow depression; either the ridge or the furrow corresponded to the front limb of the forceps blade. Immediately in front of the ear, over the articulation of the lower jaw, the tissues felt a trifle thicker than on the other side, and it was thought that this might have been caused by pressure against the pubic arch.

On 26th (seventeen days) the facial muscles were certainly better and the squint rather less, a little sclerotic being visible at the nasal side; and on 28th (nineteen days) the nurse noticed that the eye began to move better.

On February 6th (twenty-eight days) I found the paralyses much improved. There was still slight convergent squint, but the eye moved outwards much better, and

Digitized by Google

would occasionally for a moment reach to the outer canthus; the oral and cheek muscles acted a good deal although far from perfectly, but the orbicularis oculi showed very little action. The first and second divisions of the fifth nerve seemed natural. It was still impossible to test the hearing satisfactorily. The inequality behind the right ear remained, and it was now clear that the furrow was due to slight depression of the bone; the slight thickening over the zygoma had disappeared. The hæmorrhage below the right optic disc was much smaller, but there was now another small one on the opposite side of the optic disc. I thought the optic disc itself greyer and less clear than the left.

On the 7th instant (nine months) one could still detect at times a trace of defect in the orbicularis oculi and at the angle of the mouth, and there was occasionally a slight inward squint; but practically recovery was complete. I satisfied myself that the child heard the watch about equally well with each ear. The right optic disc showed some disturbance of pigment at its border, but its colour was not different from the left, and I should say that both optic discs, though streaky, were normal.

It is curious that not long after birth a small quite superficial patch of capillary or fine venous nævus appeared on the right (paralysed) upper lid, and remained for several months. It has now disappeared.

In this case there is no reason to suppose that the sixth nerve or external rectus muscle was injured by hæmorrhage into the orbit and the facial nerve by direct pressure in the parotid region. There was never any indication of blood in the orbit, and only very doubtful evidence of pressure by the pelvic rim over the zygoma on the affected side. I think the damage was intra-cranial.

Further, it seems likely that the lesion was single, because both nerves were at first completely paralysed. Both began to improve, so far as we could tell, at the same time (about the seventeenth day), and in both recovery seemed to progress at the same rate and to the same degree.

The only question seems to me to be whether the seat of

Digitized by Google

the lesion was at the closely associated nuclei of the sixth and seventh nerves, or at the base where the two nerve-trunks are near together on the petrous bone. In either situation we must suppose that the actual injury was inflicted by extravasation of blood. It appears most likely that the damage was at the base, and that it was caused by the pressure of the forceps over the outer (basal) aspect of the petrous bone, this pressure either producing hæmorrhage that compressed the nerve-trunks, or perhaps actually displacing the bone itself.

The nuclear hypothesis seems to me extremely unlikely in view of the depression actually produced by the forceps over the base of the petrous bone. Moreover, if the lesion had been at the combined nucleus, I suppose that the orbicularis oculi and frontalis muscles, which, we are told, are supplied by fibres derived from the oculo-motor nucleus, might be expected to be less affected than the inferior facial muscles that are supplied by the cells of the combined nucleus itself. But in the present case the orbicularis oculi muscle recovered after, rather than before, the muscles of the mouth and cheek. The hæmorrhage at the optic disc of the right eye is also more consistent with damage at the right base than with a nuclear lesion; although it may have been due merely to venous congestion, and independent of the paralysis.

Cases of birth-palsy of the sixth alone, with forceps scars on some parts of the face, have been recorded by Bloch,* and probably by others; but I have not, so far, found any example like the one just narrated, although I do not suppose my case to be unique.

In the new edition of Graefe-Saemisch, Alfred Graefe† gives several cases of congenital paralysis of the sixth, but I find no mention of the facial nerve in any of them; nor do I find obstetrical ocular paralysis mentioned by Bernheimer ‡ in his chapter in the same edition.

* Bloch, *Hirschberg's Centralblatt*, xv, 134 (1891).

† Graefe-Saemisch—Alfred Graefe, Lief. 2, p. 86 (1898).

‡ Bernheimer, *ibid.*, 37—39 (1902).

Digitized by Google

Several cases are on record of complete permanent congenital paralysis of the facial and sixth nerves on both sides, and in some of these other congenital defects have been present. These double-sided cases are believed to be due to want or arrest of development of the corresponding centres, and have no bearing on our present case.

Returning for a moment to the problem of single or double lesion in a case such as I have related, I will mention for contrast another case in which there were almost certainly two lesions, one for the sixth nerve, the other for the seventh. The patient was a boy, æt. 5 years, who had on the left side defective action of some of the facial muscles and of the external rectus, with convergent squint. There was a large conspicuous forceps scar in front of the ear on the side of the paralysis, and on the same side irregularity of the neighbouring part of the corresponding orbital rim. The facial nerve had doubtless been directly compressed by the forceps in the parotid region, and either the external rectus muscle or the sixth nerve in the orbit damaged by hæmorrhage into the orbital tissues. The history was that he was the firstborn, his Mother being thirty-four years of age at the time; that the labour was very tedious with face presentation; that forceps were used; that the eyelids were much swollen for some time after birth, and that the squint was noticed as soon as the child was able to open his eyes. I saw this child at Moorfields in 1887. (M. O. P., 2, 106.)

(*October 16th*, 1902.)

Dr. BEEVOR said that the question was whether there was a lesion of the facial nerve and sixth nerve, or of the facial nucleus and the nucleus of the sixth. He had no doubt that Mr. Nettleship had given the right opinion, that the lesion was of the nerves and not of the nuclei, because it was the whole of the facial which was affected; and also with regard to the external rectus, it was only the rectus of one

Digitized by Google

side, and not the internal rectus of the other. There was no conjugate paralysis, and if the facial nucleus had been involved and not the facial nerve he thought it much more likely that some part would have escaped. Probably the orbicularis oris would have escaped, also the orbicularis palpebrarum, those being supposed to be supplied by the hypoglossal nucleus and by the third nucleus respectively. Another point was that the case almost completely recovered. If the nuclei had been involved recovery would have been much delayed, even if it occurred at all. With regard to the lesion, he thought it was hæmorrhage, from the fact that there was also hæmorrhage into the retina, and hæmorrhage was the most common occurrence in difficult obstetrical cases, as has been shown by Dr. Spencer in a paper in the Obstetrical Society's *Transactions* on "Visceral Hæmorrhages in Stillborn Children."

Mr. J. H. Fisher thought that the chief difficulty in accepting the explanation of a single hæmorrhage involving the two nerves was, that such an extravasation must have implicated the nerve-trunks shortly after their origin from the pons, must have been of considerable size, and have been entirely intra-dural in position. The facial nerve had its superficial origin in association with the auditory at the lateral part of the lower border of the pons, and nowhere perforated the dura mater, but passed out of the posterior fossa of the skull by the internal auditory meatus. The sixth nerve emerged at the lower border of the pons close to the mid-line, at the upper end of the pyramid of the medulla; it ran upwards and forwards between the ventral aspect of the pons and the base of the skull for not more than three quarters of an inch before perforating the dura mater, to take its course on the outer side of the inferior petrosal sinus over the apex of the petrous bone. If a hæmorrhage were large enough to take these divergent nerves intra-durally, it must have pressed considerably upon one side of the pons and produced more symptoms than appeared to have been detected in a very careful examination of the case. On

Digitized by Google

the other hand, the fact that one blade of the forceps was passing behind the right ear seemed to be in favour of the view that the facial paralysis was due to the pressure of the forceps. If one examined the young child's skull one was struck by the conspicuous position of the stylo-mastoid foramen; so far from it being a basal foramen, as in the adult, it was really a lateral foramen in the skull of the newly-born child. That was explained by the want of development of the tympanic ring and of the mastoid process of the temporal bone at this stage. The blade of the forceps which lay behind the pinna could scarcely have avoided pressing on the seventh nerve as it emerged from this foramen. The situation of the blade was therefore in favour of direct forceps pressure being the cause of the facial paralysis; and the necessity of the hæmorrhage being of sufficient extent to take in the two nerves in the intra-dural portion of their course seems to be an obstacle to the explanation which assumed a single hæmorrhage. Such a hæmorrhage, besides involving the pons, must have taken the auditory nerve in conjunction with the seventh on the right side. The fifth nerve was hardly associated with the sixth until the front of the apex of the petrous bone was reached. He was inclined to think there were two lesions; that the facial nerve was injured by the pressure of the forceps in the region of the stylo-mastoid foramen, and that the damage to the sixth nerve was due to hæmorrhage, possibly from the inferior petrosal sinus, on the outer side of which the sixth nerve passed after piercing the dura mater. It was conceivable that movement imparted to the apex of the petrous bone by the pressure of the forceps on its base may have caused a laceration of the wall of the inferior petrosal sinus. There was no information as to the frequency of retinal hæmorrhages in the newly born child. We knew, however, that the inferior petrosal sinus helped largely to drain the cavernous sinus, into which anteriorly flowed the ophthalmic veins. A lesion of the inferior petrosal sinus might reasonably be expected to have caused congestion of the

Digitized by Google

veins of the retina, and be invoked to explain the retinal hæmorrhage which Mr. Nettleship had observed.

Mr. NETTLESHIP thanked Mr. Fisher for his lucid explanation of the probable seat and nature of the damage, and thought it perhaps agreed better than any other with the clinical facts, but thought the simultaneous and equally good recovery of both nerves a possible difficulty in Mr. Fisher's hypothesis.

---

6. *Avulsion of eyeball by midwifery forceps.*

By SIMEON SNELL.

ON June 16th last (1902) a baby, aged 1 day, was admitted into the Sheffield Royal Infirmary. The left eyeball was lying on the cheek, being connected to the orbital tissues by little more than bands of conjunctiva. The cornea was dull and opaque. The child appeared to suffer no pain. There was a mark as of forceps above the left eyebrow, and there was a noticeable depression about one inch long on the right temple, probably caused by the sacral promontory. There was facial paralysis on the right side affecting only the lower half of the face, the eyelids escaping. The child was fully developed, and appeared quite healthy. The eyeball was removed on June 17th by severing the bands that were still holding the globe. The optic nerve was found to have been torn through, leaving fully an inch attached to the eyeball.

The following particulars were kindly supplied by the medical man who had been in attendance:—The Mother was a small woman with a contracted pelvis. The doctor was called to her at 4 a.m. on the day before the child's admission to the infirmary (June 15th), but previously to

Digitized by Google

this, a midwife had been in attendance for several hours. He found the head jammed fast in the brim of the pelvis. He put the patient under chloroform, and applied the forceps high up. The patient was so small and the pelvis so contracted that he considered version would not improve matters as far as the head was concerned. He anticipated he would have to use the perforator, but after considerable traction the head moved a little, and the labour was terminated.

Very curiously, a few weeks after this case, another instance of injury from midwifery forceps came under my care. The child was born on July 25th, 1902, and was admitted into the Sheffield Royal Infirmary the next day. It appears that the child presented in the right occipito-anterior position, and was delivered with forceps at 6 a.m. on the 25th. At 9 a.m. the doctor was sent for again, and he noticed œdema of the eyelids, which were apparently normal at birth. By 3 p.m. the conjunctiva of the left eye was bulging between the eyelids. On the next day, when the child was admitted into the infirmary, the conjunctiva of the left upper lid was swollen and protruding from the palpebral fissure, forming a tumour about half the size of a cherry, with very little œdema or discoloration of the lids. The eyeball was unaffected, and the left eye and lids were normal. The portion of the protruding conjunctiva sloughed, but otherwise recovery was perfect.

Remarks.—The foregoing are the only cases of eye injury occurring at the time of birth from the use of forceps that have, so far as I recollect, come under my notice. In the first the injury was of an unusually severe character. My search into the literature has not disclosed a similar case. Several text-books have been looked through, and although in many the possibility of injury with forceps is alluded to, such a complete avulsion is not mentioned.

The nearest approach to a similar case that has fallen under my notice is one recorded by Dr. Beaumont,* but that instance was very much less severe. The globe was

* Beaumont, *Provincial Medical Journal*, 1892.

Digitized by Google

protruded, the sclerotic was visible as far as the centre of the globe, and the two eyelids were drawn back behind the eye. Under chloroform, the globe was readily replaced.

(*November 14th*, 1902.)

---

7. *A clinical and pathological account of some of the injuries to the eye of the child during labour.*

By W. Ernest Thomson, M.D., and Leslie Buchanan, M.D.

(With Plate XVII, figs. 1—4).

Introduction.

In amplification of the observations recorded by one of us upon the subject of traumatic keratitis of the new-born in these *Transactions* (1), we intend, in the present communication, to deal more fully with the whole subject of "obstetric" injuries to the eye of the infant.

We have been fortunate in obtaining a considerable amount of material for pathological examination, and by the kind permission of Prof. Robert Jardine and Dr. Munro Kerr we are also enabled to give in *résumé* the obstetric history of the various cases which we are about to record and to discuss.

While admitting that we do not offer very much that is entirely new, we feel that the small amount of notice which has been taken of obstetric injuries to the eye justifies us not only in bringing forward our own cases, but also in giving a review of the literature of the subject, which is mainly French and German. Apropos the scanty attention paid to the subject we would point out that these injuries are not to be regarded merely as curiosities, but as possible factors in the causation of a number of visual defects which may be discovered only in later life. The term *congenital*

Digitized by Google

is frequently applied to various conditions of the cornea, choroid, retina, and eye muscles, because we are as yet in ignorance of the true cause of these defects; but it is our opinion that many of them may be due to traumatism at birth. Such, for example, are some corneal opacities, possibly certain cases of dislocation of the lens, and of cataract, almost certainly some cases in which pigmented or atrophic patches are found in the fundus, and at least a proportion of cases of amblyopia from damage to the optic nerve by bone pressure, or from hæmorrhagic effusion into the optic nerve or its sheath, or into the retina. Our experience of the extraordinary effects of pressure upon the eyeball leads us to the opinion that almost anything is possible in the nature of injury to internal structures.

Regarding the particular cases which gave origin to this inquiry, namely, traumatic keratitis with linear leucoma, we have discovered two previously placed on record, the one by H. Truc, and the other by de Wecker. Neither of these authors, each dealing with a solitary case, has been in a position to realise that the lesion which leads to this vertical or obliquely vertical leucoma right across the cornea is a definite one, and to the best of our belief we may claim originality in describing it, and in showing that these cases all belong to one group in which a particular degree of pressure is brought to bear upon the eye in a definite direction. This pressure, as we shall show, leads to rupture of the posterior elastic lamina, and sometimes of the posterior corneal lamellæ, with, presumably, the subsequent formation of fibrous tissue in the situation of the rupture.

Literature.

For a large proportion of the references here given we are indebted to the paper by H. Truc (2).

Leaving out of account œdema of the eyelids, conjunctival hæmorrhages, and chemosis, the following observations have been made as regards *normal labour*.

Königstein (3) found retinal hæmorrhages in 10 per

Digitized by Google

cent. of births, and even saw them in children born at seven and eight months.

Schleich (4) observed retinal hæmorrhages in 32 per cent. of cases.

Naumoff (5) found retinal hæmorrhages in 26·5 per cent. of cases, but none in premature births at the seventh and eighth months. The hæmorrhages observed by him were chiefly situated peripherally, and in the fibre and ganglion-cell layers. He found macular hæmorrhages in the inner nuclear layer. Three times Naumoff found choroidal hæmorrhage. Of these one was in the macular region, and caused a circumscribed separation of the retina. He states that retinal hæmorrhages are caused by pressure on the skull, driving cerebro-spinal fluid along the intervaginal space. This theory is combated by Von Hippel (6).

Still under the heading of normal labour, de Wecker (7) describes "the most extraordinary case which has presented itself to his observation," in which the obstetrician, mistaking an orbit in a face presentation for an anus in a breech presentation, gouged out the eyeball with his finger.

Homer (8) states that fracture of the orbit with retro-bulbar hæmorrhage has been caused by excessive uterine contraction under the influence of ergot.

Passing on to the consideration of *assisted labour*, Truc (2) states that pressure by forceps, whether applied antero-posteriorly or laterally, is responsible for excoriations, ecchymoses, œdema, exophthalmos, fracture of the orbit, paralysis of the lid muscles, corneal troubles, retinal hæmorrhages, optic atrophy, and strabismus with hypermetropic astigmatism. His authority rests on papers by a number of authors.

Pajot (9) reports two cases of exophthalmos.

Homer (8) has seen palpebral œdema, exophthalmos, and slight hyphæma after occipito-frontal application of forceps. Death of the child four days later. *Post-mortem.* —Fracture of roof of orbit; retro-bulbar extravasation of blood.

Digitized by Google

Lomer (10) refers to four similar cases.

Truc (2) states that fractures are generally of the frontal portion of the orbit; that they are caused either directly by depression in the antero-posterior application of forceps, or indirectly in the bilateral application; that there is always œdema of the lids, and almost always retro-bulbar hæmorrhage, and that death from cerebral complications usually results.

Paralytic ptosis and lagophthalmos, from injury to the third and seventh nerves respectively, are recorded by Truc and Valude (11), de Wecker (12), and Pajot (9).

On the subject of keratitis Truc has four cases, of which the first (his own) is most interesting as being the only one which we have discovered in which a linear leucoma has been recognised *later in life* as due to pressure during labour. We quote the case:—"Girl 4 years old. Strabismus convergens of right eye. Left eye normal. Right eye:—Fairly dense linear leucoma occupying the whole length of the cornea in the oblique meridian '1 to 7 o'clock.' H. ast. 4 D. The leucoma is congenital and consecutive to an inflammation caused by application of forceps, of which one blade pressed upon the eye and orbit."

The second case is by Dujardin (13). In this case there was a difficult delivery with forceps in a contracted pelvis. "The cornea hazy in almost its whole extent. Conjunctival hyperæmia and chemosis. Eight days later very little to be seen. Early complete disappearance of the opacity anticipated."

The third case is by Noyes (14). The title explains the case: "Total opacity of the cornea with palpebral œdema and chemosis; rapid cure." This case ended with an opacity of the cornea in its upper internal quadrant.

The fourth case is de Wecker's (7). After a difficult forceps delivery, the cornea was so opaque all over that it was impossible to see the iris even with oblique illumination. The forceps mark traversed the eyebrow. The

Digitized by Google

opacities cleared up in a month, leaving a faint, linear, obliquely placed haze.

Each of these four cases finds its parallel in one or other of those described by us either in this paper or in the previous communication (1).

In connection with the subject of corneal lesions, E. von Hippel (15) has recently undertaken important investigations regarding corneal endothelial changes and their significance in the production of different corneal diseases, and states (6) that he has seen rupture of the posterior elastic lamina without laceration of the corneal substance. Elsewhere (16) he notes, in reference to the subject of "ulcus corneæ internum," that he has seen a rupture of the posterior elastic lamina in the new-born eye, the cause of which he does not clearly understand. He supposes, however, that it is due to a sudden increase of intra-ocular pressure during birth.

Regarding retinal hæmorrhages in difficult labour, Königstein and Schleich state that they are not more frequent than in normal labour.

Von Hippel (6) states that hæmorrhages in the new-born may cause changes in the macula which lead to defective vision after they themselves have been absorbed.

The only case of injury to the lens of which we have found a record is by Peck (17), according to whom traumatic cataract was produced by pressure of forceps on the eye during delivery.

Optic atrophy as the result of severe forceps pressure has been reported by David de Beck (18). It is stated that occipito-frontal pressure by forceps appeared to have determined a crushing or fracture of the optic foramen. From the context this appears to be only an assumption, but the assumption is probably justified by our Case 5 (*quod vide*, p. 307).

Truc (2) holds that strabismus due to paralysis of muscles has not yet been proved. We are inclined, however, to regard it as an altogether probable accident, and Nettleship (19) has communicated to the Society in the present

Digitized by Google

session a case of birth-palsy of the sixth and seventh nerves on the same side. Mr. Nettleship thinks the cause of the affection was an intra-cranial hæmorrhage.

Avulsion of the globe has been described by Maygrier (20) and by Snell (21), and we know of at least one other case in which a similar accident occurred, but which has never been recorded.

Although these cases are referred to by their authors as *avulsion* of the globe, we prefer to consider that the accident is *extrusion* of the eyeball, the result of diminution of the cavity of the orbit caused by depression of bones. Neither in Maygrier's, Snell's, nor in our own case (*quod vide*, p. 307) was there any laceration of the eyelids, and in all three there was a well-marked depression of cranial bones.

Beaumont (22) reports that he has seen the eyeball dislocated after difficult delivery. The eye was restored to its normal position after twenty-four hours.

We have given an account of all the literature to which we have had access, either directly or indirectly. Doubtless there is a good deal more which we have not been able to find or to obtain; but it is clear that although we have given a score of references, and allowing that there are a good many more to be found, this number is very small indeed when compared with the total number of difficult deliveries. We make this remark merely in support of our thesis that the subject has been greatly neglected, especially in this country.

How does it happen that in about two years we have seen examples of most of the injuries which have been described, and that we are in a position to give a pathological account of three cases which present what we believe to be a hitherto undescribed lesion, the elongated rupture of the posterior elastic lamina which results in a linear leucoma? There are probably two explanations of this. In the first place, the slighter results of injury—such, for example, as œdema of the cornea—may pass unnoticed by the obstetrician and by the mother; while

Digitized by Google

the more severe, deep-seated lesions, like retinal and other hæmorrhages, are not visible by the unaided eye. In the second place, since Glasgow is notorious for rickets, and therefore for contracted pelves, obstetric injuries are probably more common than in most other large cities. If to these two explanations it be added that every one at the Glasgow Maternity Hospital is alive to the importance of, and on the look-out for these cases, the comparatively large number we have seen is at least partially accounted for.

Cases.

We shall next present the details of our cases, which are unavoidably somewhat long, and afterwards discuss only the more important features from the clinical and pathological standpoints.

During the past two years or so we have seen eight cases of traumatic keratitis involving twelve eyes; one case of corneal opacity with blood in the anterior chamber, seen first some hours after death; one case of retroversion of the lens and vitreous without rupture of the globe; one case in which the left eye was extruded from the orbit, and the optic nerve and the muscles severed, while the right eye exhibited traumatic keratitis; and one case of exophthalmos. Some of these eyes have exhibited retinal, choroidal, and optic nerve hæmorrhages as well. It is of interest to note that the retroversion of the lens and vitreous occurred during craniotomy, and that the children in the cases of exophthalmos and of extrusion of the eye both survived.

Case 1. *Obstetric history.*—Nineteen-year-old primipara. Contracted pelvis (C. V. three and a half inches). First and second stages twenty-four hours. Child, female, 7¾ lbs., could not be got to breathe in spite of good heart action. Very difficult forceps delivery; vertex presentation. One blade of forceps applied over outer angle of right orbit.

Digitized by Google

Digitized by Google

PLATE XVII.

Illustrates Drs. Thomson and Buchanan's communication on some of the Injuries to the Eye of the Child during Labour (p. 296).

FIG. 1.—Diagram of the posterior surface of the cornea of Case 1. The dark coloration represents blood on the posterior elastic lamina. The light bands show where the elastic lamina is interrupted.

FIG. 2.—Meridional section of the cornea of Case 1, magnified 15 diameters, showing three of the ruptures. Two of them show involvement of corneal lamellæ, the third interruption of posterior elastic lamina only: The layer of blood is also visible.

FIG. 3.—Meridional section of the cornea of Case 5, magnified 18 diameters, showing rupture of the posterior surface of the cornea. The appearance of the torn surface contrasts strongly with that in Fig. 2. (See pp. 309 and 314.)

FIG. 4.—Appearance of the posterior surface of the cornea in Case 2, high power, showing the separation of the posterior elastic lamina, with massing of pigment. (See p. 304.)

Digitized by Google

Fig. 1.



Fig. 4.



Fig. 2.

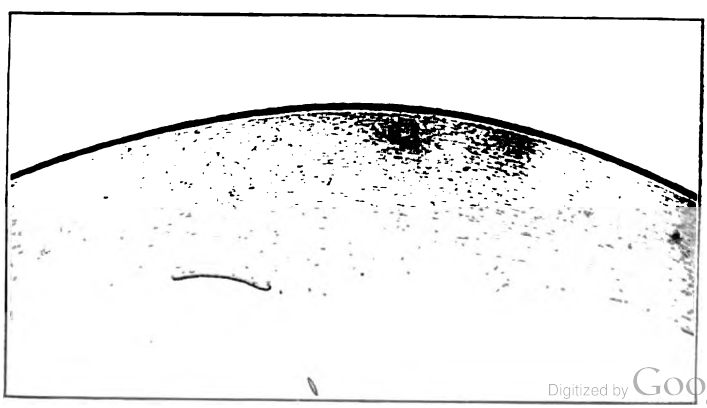

Fig. 3.

Digitized by Google

Digitized by Google

Ophthalmic account: right eye—macroscopic.—A.C. full of blood. Cornea very cloudy, and showing vertical bands. On horizontal antero-posterior section of eyeball, after washing out the blood from the anterior chamber there remains a layer of blood on the posterior surface of the cornea, interrupted by four clear bands, close together, and running approximately vertically across the cornea (Plate XVII, fig. 1). These clear bands are due to absence of the layer of blood. The widest band measures 1 mm. at its middle, and tapers above and below. The other bands are from one-half to one-quarter this width. Iris, lens, and vitreous are normal in appearance.

The posterior part of the retina is thickly studded with small irregularly-shaped hæmorrhages. There is a hæmorrhage in the centre of the optic nerve two millimetres behind the lamina cribrosa.

Right eye—microscopic.—The four clear bands on the posterior corneal surface correspond with gaps due to ruptures of the posterior elastic lamina. The principal rupture, in sections at right angles to its course, shows that the severed ends of the lamina are widely separated, and that approximately five layers of the cornea are also ruptured (Plate XVII, fig. 2). The torn ends of the lamina are turned forwards and adhere to the corneal structure. The floor of the concavity formed by the retraction of the ruptured corneal lamellæ is smooth, because the ruptured fibres are sealed down by fibrin. There is very little disturbance of neighbouring corneal tissue. The next largest rupture shows destruction of only one corneal layer, and inversion of the ends of the posterior elastic lamina. The other two ruptures involve the lamina only. The retina and choroid show very numerous and extensive hæmorrhages, mainly situated posteriorly. In addition to the large extravasation in the optic nerve, its vessels are markedly congested.

Left eye—macroscopic and microscopic.—Slight general opacity of the cornea, which proved on histological exa-

Digitized by Google

mination to be due to œdema only. Numerous small circular and irregular retinal hæmorrhages confined to the fibre and ganglion-cell layers.

Case 2. *Obstetric history.*—Craniotomy case, child probably dead for several hours. When the perforated head was delivered, the right eye presented in the fenestra of the instrument. The left eye had been entirely destroyed. It was not kept by the obstetrician, but had probably been ruptured.

Ophthalmic account: macroscopic.—The eye is very oval horizontally, measuring 15·5 mm. horizontally, and 13 mm. vertically. There appears to be a layer of blood upón the iris. On section horizontally, what formerly appeared to be blood in the anterior chamber is found to be free pigment which escapes in quantity. The lens and vitreous are retroverted, so that the lens lies against the optic nerve. On placing the divided eye in water the lens and vitreous float out at once, the lens carrying with it the pigmented pars ciliaris retinæ, and leaving the ciliary processes almost denuded of pigment. The retina is much folded, but there are no *macroscopic* hæmorrhages. Close examination of the cornea reveals an obliquely situated, clear, pigment-free band on its posterior surface. Magnified with a hand lens the sectional appearance of this band is similar to that in Case 1.

Microscopic.—The corneal epithelium is entirely stripped off. The corneal spaces are distended by œdema. The posterior elastic lamina is ruptured over a large area, but there is no breach of the corneal lamellæ. A remarkable appearance is presented by one of the torn ends of the lamina (Plate XVII, fig. 4), which is coiled forwards on itself like a watch-spring. Between the coils, and upon the exposed corneal surface, there is coagulated lymph mixed with pigment granules. The endothelium is absent, not only over the torn portion, but over most of the attached portion of the posterior elastic lamina.

Digitized by Google

CASE 3. *Obstetric history.*—Twenty-eight-year-old multipara. Contracted pelvis (C.V. three inches). First and second stages twelve hours. Well-developed, large male child, could not be got to breathe in spite of heart action continuing for five minutes. Vertex presentation; very difficult forceps delivery.

Ophthalmic account: right eye—macroscopic.—Conjunctival hæmorrhages. No appreciable corneal opacity. Some blood in anterior chamber, chiefly in the upper part; no sign of rupture of the iris. Antero-posterior horizontal section of the eye reveals no abnormality of the cornea, iris, lens, ciliary body, or vitreous. In the retina a number of fine pigmented lines are seen arching round the macula from the papilla.

Left eye—macroscopic.—Conjunctival hæmorrhage. No corneal opacity. No blood in the anterior chamber. Eye bisected into an anterior and posterior half. No abnormal appearance of the former. The retina is œdematous, as shown by the antero-posterior curvature of the vessels and by convolution of the macular region. The veins are markedly tortuous. On the disc is an elongated hæmorrhage, and, on magnifying fifty diameters, several minute hæmorrhages are seen along the course of the vessels.

Post-mortem examination of the head by Dr. C. C. Douglas revealed a complete fissured fracture in the lower external part of the left frontal bone, about one-third of an inch above the orbital plate. Inside the skull, small hæmorrhages opposite the point of application of the forceps. Moderate effusion of dark blood over the cerebrum on both sides. No blood effusion in the region of the optic tracts or commissure.

CASE 4. *Obstetric history.* — Details wanting. Very large child delivered with forceps; stillborn. There is much head moulding and extreme mobility of the bones of the cranial vault. Deep forceps indentation over the outer

Digitized by Google

angle of the right orbit; other blade probably over ramus of left lower jaw.

Ophthalmic account: right eye—macroscopic.—Cornea cloudy, requiring focal illumination to see the iris properly. On equatorial section, no changes are seen in front of the ora serrata. The retina is increased in bulk, probably by œdema, so that it is thrown into at least seven meridional folds, which extend from the ora serrata backwards towards the optic nerve. The retina is folded also at the ora serrata, and overlaps the pars ciliaris retinæ in the form of a circular roll. The retinal veins are engorged, but not extremely tortuous. There are several large areas of retinal hæmorrhage. The choroid is deeply congested.

Right eye — microscopic.—The corneal epithelium is abraded, and its degenerated appearance suggests an *ante-mortem* cause. The corneal tissue exhibits changes indicative of inflammatory action, evidenced by widening of the interlamellar spaces (œdema) and cell proliferation here and there. The posterior elastic lamina is intact, but entirely denuded of endothelium.

Left eye—macroscopic.—This eye was also bisected equatorially. Blood-clot occupies almost the outer half of the anterior chamber. The retina presents folds similar to those in the right eye, but without evidence of hæmorrhage. The choroid is much less congested than that of the right eye.

Post-mortem examination of the head by Dr. C. C. Douglas. The head exhibits no evidence of fracture. Bones are extremely movable. On reflection of the scalp there is considerable hæmorrhage above and beneath the pericranium over an area corresponding to the caput succedaneum. Comparison of the two orbits shows distinctly greater mobility of the external wall of the right than of the left. This is due to depression of the external inferior angle of the frontal bone below the malar, at the fronto-malar joint.

Within the skull the great veins are engorged; there are small hæmorrhages over the right frontal convolutions

Digitized by Google

and over the right cribriform plate. There is a slight blood collection in the left middle fossa, and another upon the tentorium cerebelli, chiefly to the left side. There is a large quantity of clotted blood in both posterior fossæ. The optic nerves and chiasm appear to be free from hæmorrhage.

CASE 5. *Obstetric history.*—Thirty-eight-year-old multipara. Contracted pelvis (C.V. three inches). First and second stages eighteen hours. Child, female, 8½ lbs., with an unusually large head (in all diameters). Symphysiotomy one and a half years ago, and also upon this occasion. Head engaged in transverse diameter of pelvis. Milne Murray's axis-traction forceps were applied to the head in its antero-posterior diameter, but slightly obliquely. Traction was attempted in the Walcher position, but unsuccessfully. Forceps were then removed with difficulty, and were afterwards reapplied in the same diameter of the head; symphysiotomy was then performed. Delivery was effected without difficulty; the forceps were reapplied at the outlet in the biparietal diameter.

Ophthalmic account: condition at birth.—The left eye was lying on the cheek attached only by the conjunctiva and the external rectus. There was no bleeding. A large, shallow, spoon-shaped depression (due to pressure by the sacral promontory) involved the left frontal and parietal bones. This depression is guessed to have measured 6 cm. × 4·5 cm. This was elevated by counter-pressure by Dr. Munro Kerr.* The orbit appeared to be occupied by blood-clot, and digital examination was not made. There was no laceration of the eyelids, though the upper lid was ecchymosed and somewhat œdematous. The eye was severed from its remaining connections by the house-surgeon at the Maternity Hospital. The right cornea was uniformly hazy, and the pupil could only be seen with difficulty. No ecchymosis of lids or conjunctiva.

* The child was alive and well at the time of writing—five months afterwards.

Digitized by Google

Clinical progress.—The wounded left orbit healed in due course. The opacity of the right cornea increased day by day up to about the fourth day, at which time it remained uniformly over the cornea and was made up of flocculent-looking dots. There was slight loss of surface lustre, but no pericorneal injection or chemosis. The opacity was so great that the pupil could be seen only with strong focal illumination. From this date to the time of writing—five months later—the cornea has gradually cleared, at first rapidly and lately very slowly, from the superior nasal towards the inferior temporal region. At the present date the central and upper nasal portions are fairly clear, but a crescentic band of rather dense opacity occupies most of the rest of the cornea. The iris was at no time resistent to atropine, which was used alone in the early days of the case, and, later on, combined with red oxide of mercury.*

Examination of the left eye: macroscopic.—The eyeball has attached to it 16 mm. of optic nerve. It is not possible to determine absolutely whether the nerve has been cut by bone or simply torn; we lean to the former alternative. On casual inspection the cornea appears to be transparent, but after antero-posterior horizontal section of the eyeball a clear, almost vertical groove is seen on its posterior surface, extending across the whole cornea, and measuring ·75 mm. in breadth. This groove manifestly involves several layers of corneal substance. The anterior chamber is clear and of normal depth. The iris, lens, and ciliary body appear normal. There is slight œdema of the retina, and the retinal vessels are very small. No manifest congestion of the choroid or other changes of any kind are found.

Microscopic.—Interest centres around the cornea. No changes are observed in the anterior layers. The posterior elastic lamina is ruptured in several places, the most extensive rupture being near the centre in the region of

* October, 1903.—The opacity continues to clear, leaving a narrow, crescentic, dense opacity, similar to that seen in the linear form of leucoma.

Digitized by Google

the groove seen macroscopically. Particular examination of this groove shows that it is formed by the tearing of approximately eight layers of corneal tissue. The posterior elastic lamina is stripped off a still greater area than that occupied by the torn corneal lamellæ (Pl. XVII, fig. 3). It is particularly noted that the extremities of the torn corneal lamellæ present a shaggy, lacerated appearance, as if roughly torn asunder. There is no evidence of repair. The corneal substance immediately bordering upon the groove has a somewhat macerated appearance. The other situations at which the lamina is ruptured are small, and the underlying corneal tissue is not involved.

Case 6. *Obstetric history.*—Thirty-four-year-old multipara. Contracted pelvis (C.V. not known). First and second stages eight hours. Child, female, 7½ lbs. Vertex presentation. Forceps delivery. Of seven previous labours, two required craniotomy and five a forceps delivery.

Ophthalmic account.—At birth there was a depression on the upper portion of the right frontal bone (and probably the anterior part of the parietal) caused by the sacral promontory. The depression measured approximately 4 cm. by 3·75 cm. Its anterior edge was about 1 cm. from the upper orbital margin, and its mesial edge came almost to the middle line of the head. The right eye was proptosed to the extent of slightly preventing the closure of the lids. An hour afterwards, it was scarcely so prominent. There was only slight conjunctival ecchymosis; the movements of the eyes appeared to be normal; the cornea, iris, and anterior chamber were normal. The depression was elevated by Dr. Kerr about one hour after birth by fronto-occipital counter-pressure; the eye, however, remained slightly proptosed.

Three days later, the eye appeared to be still slightly in advance of its fellow; there was marked ecchymosis strictly limited to the eyelids, and only a moderate amount of conjunctival ecchymosis. The fundus was examined, and one or two small retinal hæmorrhages seen.

Digitized by Google

Eight days after birth, no prominence of the right eye could be observed. The lids remained extremely black. The child has not been seen again since leaving hospital.

Traumatic Keratitis.

Before discussing the pathological aspect of the cases in general we should like to say a word or two on the subject of traumatic keratitis of the new-born from the clinical standpoint.

In the first place, traumatic keratitis must be accepted as a rare complication of assisted labour, even when only really difficult deliveries are counted. We are not at present prepared to make any definite statement about the degree or the direction of the pressure required to produce injury to the cornea, although later on (p. 314) a suggestion is made that it is due to the actual forceps blade.*

The second point has reference to prognosis. Traumatic keratitis may be described as occurring in two forms, light and severe, according as the opacity is evanescent or not. In the light form the initial haze of the cornea clears away in a few days (23). In the severe form a more or less permanent opacity sooner or later succeeds this initial haze. The latter, so far as we have observed it in the eyes of children who survive, is almost perfectly uniform, flocculent, and interstitial, is accompanied by loss of surface polish, and disappears completely. The secondary opacity, the date of appearance of which varies, occurs in two forms—(1) indeterminate in shape and position, (2) in the form of a linear leucoma placed approximately vertically across the cornea.

As will appear presently, we incline to regard the initial haze as due to œdema of the cornea, and the secondary opacity as due to the formation of scar tissue in the situation of the rupture of the posterior elastic lamina.

* Since this was written, a case has occurred in which the head and arm presented. Forceps were not used. There was extreme head moulding, and a diffuse opacity of each cornea. Marked folding of the retina (much as in Case No. 4) was noted.

Digitized by Google

It is obvious that the prognosis at the time of birth requires serious consideration. A trifling initial opacity may clear away entirely, and no secondary appear. On the other hand, it may increase for several days until it becomes intense, and then as it gradually clears away, and the cornea regains its polish, a pronounced secondary may be found to remain. An intense initial opacity will almost certainly be followed by a marked secondary, but the prognosis as to vision is not nearly so bad as would be imagined from the early appearance of the cornea. Sufficient time has not yet elapsed to enable us to judge of the ultimate behaviour of these scars.

From the fact that so-called congenital leucoma is really rare in eye *cliniques*, it might be inferred that the opacity clears away in time, as do other leucomata of early post-natal origin. On the other hand, the total number of infants affected is very small; they are the children amongst whom the death-rate is highest, and in whom, if they survive, the least attention is likely to be paid to the condition.

The prognosis, therefore, is not very bad even in the worst-looking cases, but we must not be too optimistic as regards complete disappearance of the opacity. Truc's case (2) had 4 D. of hypermetropic astigmatism with convergent squint at four years of age. To this we would only add that in some cases an indication of the future position of a vertical scar may be seen while the initial opacity is still great, due possibly to a more intense œdema of the cornea over the line of rupture.

Ætiological and Pathological Considerations.

We shall now take up the ætiological and pathological aspects of some of the specially interesting points in connection with the subject.

Hæmorrhages.—Our study of the literature and our own observations have shown that hæmorrhages into various parts of the eye are frequently found. The principal point of interest in this connection is the precise cause of the

Digitized by Google

bleeding. Since, as has been pointed out by various writers, hæmorrhage into the retina is of frequent occurrence in children born by normal or even premature labour, it follows that extreme pressure on the head is not an essential factor. Further, we have seen eyes manifestly subjected to severe compression, in which, whilst other changes were present, there were no hæmorrhages into the retina.

We are inclined to the opinion that such effusions may be the result of increase of blood-pressure caused by obstruction to the placental circulation.

It is possible, however, that sudden relaxation of extreme pressure on the head at some period during labour, by allowing the full force of the blood to come suddenly into relaxed vessels, may give rise to hæmorrhages in the retina and choroid in certain cases.

Effusion of blood into the anterior chamber is probably the result of rupture of superficial vessels in the iris or ciliary body.

Extreme œdema of the retina has been seen in one or two instances, probably as a result of pressure upon the eye during a long labour, causing obstruction to the venous outflow.

Corneal Lesions.

The explanation of the various lesions of the cornea which occur during labour constitutes what is probably the most interesting and important part of our inquiry. Three varieties of change may be distinguished, namely:—

(*a*) A diffuse opacity, which is temporary.

(*b*) A diffuse opacity, indeterminate in position, which is permanent.

(*c*) An opacity which takes a linear form and is permanent.

The *first* form is of comparatively frequent occurrence, and is probably due to œdema without inflammatory action.

The *second* is due to œdema, with inflammatory action

Digitized by Google

following it in some instances, whilst in others, in addition, the posterior elastic lamina is more or less widely stripped from the cornea.

The *third* form is due to regular linear ruptnre of the posterior elastic lamina, and sometimes of corneal lamellæ, and in either case it may be assumed that there is subsequent formation of cicatricial tissue, which remains as a permanent scar.

The following facts support these statements. Regarding the first group, we have found in several of the eyes examined histologically, in which the cornea presented a diffuse opacity, evidences of œdema without indication of other change; and have also seen clinically instances in which the cornea presented at birth appearances quite similar to those above mentioned, but which cleared up entirely in the course of a few days. It is probable that the œdema in such cases is due to pressure upon the veins in the anterior part of the eye.

In other eyes examined, however, we have found that, whilst there is œdema, there is also evidence of proliferation of the corneal cells over a considerable area, thus constituting a true keratitis. These cases form the second group. Whilst much of the inflammatory tissue thus formed may be absorbed, some of it may remain as a source of permanent opacity. In the case (No. 2) in which it was noted that the posterior elastic lamina was stripped from a considerable area of the cornea, we have another explanation of the origin of the permanent diffuse opacity. It is highly probable that, had the child survived, the portion of cornea denuded would have been covered by fibrous tissue in the form of a cicatrix, which would, of course, be opaque and more or less permanent.

In connection with the third group of cases, we have seen two instances in which linear ruptures of the posterior layers of the cornea had taken place (Cases 1 and 5). These two cases, whilst similar in some respects, differ in others, the second forming an interesting complement to the incomplete histopathological picture formed by the

Digitized by Google

first. In both cases there was a nearly vertical rupture, or series of ruptures, of the posterior layers of the cornea (figs. 2 and 3), including the posterior elastic lamina; but whereas in Case 1 there were evidences of healing of the corneal tissue (fig. 2), in the other (fig. 3), Case 5, there were none.

The clinical history supplies the probable explanation of this interesting fact. It is easy to imagine, knowing the remarkable rapidity with which healing changes take place in the cornea and elsewhere in the young, that the difference may be due simply to the duration of the lesion. Thus, in Case 1 the cornea may have been injured early in the course of a tedious labour, whilst in Case 5 the injury may not have occurred more than a few minutes before the eye was severed from its vascular connections.

As regards the mode of origin of the corneal rupture in the three cases (1, 2, and 5), it is almost an unavoidable conclusion that it was caused by direct pressure upon the eyeball.

Since the lesion in Case 2 differed in some respects from that in Cases 1 and 5, and also since there were other peculiar features in the case (which will be remarked upon later), it is probable that the pressure which caused it was of a different nature from that exercised in the others. The presence in the anterior chamber of pigment, evidently derived from the iris, indicates that the cornea had been flattened out against that structure, and the separation of the pars ciliaris retinæ, lens, and vitreous body renders it probable that whilst thus pressed upon the eye it was subjected to a twisting or screwing action.

In Cases 1 and 5, on the other hand, it is probable that the pressure has been exerted directly upon the cornea, and has caused indentation of it in the actual meridian in which the ruptures took place. The reason for this assumption is that pressure upon the margins of the cornea would tend to increase its natural curvature rather than to neutralise it, whilst linear indentation would form a posterior convexity of cylindrical form, which would most

Digitized by Google

readily stretch and ultimately cause a linear rupture of the posterior layers of the cornea. The actual cause of the assumed indentation may be the edge of the blade of the instrument used.

The reason why the ruptures are vertical or approximately vertical in position in all the recorded cases is not easily determined. It is probable, however, that the instrument is so applied that it lies across the eye with its edge in a nearly vertical meridian. Why, however, the edge of the extremity of the blade of the instrument does not impinge upon the cornea in a transverse diameter is not clear.

We have thus been enabled to establish the fact that rupture of the posterior layers of the cornea gives rise to the appearance of vertical bands of opacity, such as have been seen in cases of keratitis after injury during labour, and are quite satisfied that had the two children (Cases 1 and 5) survived, the later appearances of the corneæ would have corresponded accurately with the clinical appearances in those cases previously described (1).

What relation this corneal lesion bears to the "ulcus corneæ internum" of v. Hippel is not absolutely clear, but it appears to us that the conditions are probably the same in origin.

It is matter for speculation and investigation what other pathological conditions of the eye may have their origin in this lesion, although some work has already been done on this subject by v. Hippel (16).

Retroversion of Ocular Contents.

In connection with Case 2 it has been mentioned that the lens and vitreous body were found to be retroverted, and this is so peculiar a lesion that it may be commented upon in greater detail.

The case being one in which craniotomy had been performed, it may be understood that very severe pressure was brought to bear upon the head of the infant. As before

Digitized by Google

indicated (p. 314), it is probable that severe direct pressure would hardly suffice to produce such an injury. The cornea and iris each bore evidence of having been severely crushed, but it is almost inconceivable that these structures could have been so extensively pushed backwards as to cause complete stripping of the pars ciliaris retinæ from the ciliary body. That the pars ciliaris retinæ was almost completely torn from its normal position is shown by the fact that, when the lens was closely examined with the aid of a magnifying glass, it was found that there were two concentric rings of pigment adherent to the zonule at its periphery. When these rings were more highly magnified they were found to be composed of fine radiating lines which branched at their extremities. These lines were evidently the result of the fibres of the zonule having drawn away the pigment from the pars ciliaris retinæ to which they are normally adherent.

We are entirely satisfied that the position in which the lens was found, namely, lying against the optic nerve entrance, was not the result of the pressure of the knife upon a simply dislocated lens in the act of bisecting the eye. We think it highly probable that torsion applied to the eye whilst it was strongly compressed antero-posteriorly was the cause of the lesion.

Extrusion of the Eyeball.

The last point to which we would call special attention is the occurrence of extrusion of the eyeball from the orbit in greater or less degree. Two cases of this nature have come under our notice, in one of which the eyeball was completely pushed out of the orbit, and left hanging on the cheek by the tendon of the external rectus muscle and conjunctiva only, whilst in the other the condition amounted merely to a marked exophthalmos.

It is worthy of note in connection with the ætiology of this accident that in each of these cases, as also in two

Digitized by Google

others of which we are aware (Snell's and Maygrier's), there was a well-marked depression of the cranial bones.

In each instance the depression was situated above the orbit on the side affected. The inference, therefore, appears to us to be justified, that the extrusion of the eyeball is dependent upon the cranial depression.

It is probable that the eyeball is pressed forwards by narrowing of the cavity of the orbit at its posterior part. The actual cause of this collapse, as it may be termed, of the orbit may be either depression or fracture of its bony walls.

Unfortunately no examination of the orbit by the finger has been made after expulsion of the eye in any recorded case, so that this point cannot yet be regarded as settled. It is improbable that the eye could be torn out with the blade of the forceps without the lids being very severely injured. In the case in which exophthalmos was present the eye did not return to its normal position immediately after elevation of the cranial depression by counter-pressure. This is not surprising, however, as it is probable that hæmorrhage had occurred behind the eye when the pressure in the orbit was relieved. Further, the elevation of the cranial vault does not of necessity imply elevation of the displaced wall of the orbit.

As regards the means by which the connections of the eye with the orbit were severed in the case of complete expulsion, we are of opinion that some part of the orbital wall had been fractured, and that a spicule of bone had been pressed into the cavity, and thus has cut across the various muscles, nerves, etc., at the posterior part.

Conclusion.

We have thus passed in review the main facts in the literature of this interesting and important subject, and have added to them the record of several cases which we venture to hope will be of service to those interested. As before remarked, we have been induced to go into the

Digitized by Google

subject more fully than we might otherwise have done because so little attention appears to have been given to it in the United Kingdom. It is probable that in the future further research and closer investigation will show that many injuries may occur to the eyes of the infant during labour other than we have been able to collect records of here; and if the attention of obstetricians and eye surgeons is drawn to the subject, and its possibilities more fully realised, we are confident that much that is of interest and importance in ophthalmology will be brought to light.

We have to acknowledge our indebtedness to Prof. Robert Jardine and Dr. Munro Kerr, the obstetric physicians to the Glasgow Maternity Hospital, for their kindness in bringing the cases to our notice, and supplying us with details of the clinical histories.

References.

(1) Thomson.—"Traumatic Keratitis of the New-born," *Trans. Ophthal. Soc.*, vol. xxii.

(2) H. Teuc.—"Lésions obstétricales de l'œil et de ses annexes," *Ann. d'oculistique*, 1898.

(3) Königstein.—*Wiener medicin. Jahrbücher*, 1881.

(4) Schleich.—*Mittheilungen aus der opthal. Klinik in Tübingen*, 1884.

(5) Naumoff.—"Ueber einige path.-anatom. Veränderungen im Augengrunde bei neugeborenen Kindern," *Graefe's Archiv*, vol. xxxvi.

(6) E. von Hippel.—"Pathologico-anatomical Changes in the Eyes of the New-born," *Graefe's Archiv*, vol. xlv.

(7) De Wecker.—"Les lésions oculaires obstétricales," *Ann. d'oculistique*, 1896.

(8) Homer.—"Fracture of the Skull of the Infant by the Application of Forceps," *Zeitschrift für Geburtshülfe und Gynäkologie*, Band x.

(9) Pajot.—"Des lésions du fœtus au cours de l'accouchement," *Thèse d'agrégation*, 1853.

Digitized by Google

(10) LOMER.—*Berlin. klin. Woch.*, 1884, No. 23.

(11) TRUC ET VALUDE.—*Nouveaux éléments d'ophtalmologie.*

(12) DE WECKER.—*Traité complet d'ophtalmologie.*

(13) DUJARDIN.—*Journal des Sciences méd. de Lille*, 1896.

(14) NOYES.—*Transactions of the American Ophthalmological Society*, Session 1895, Hartford, 1896.

(15) E. VON HIPPEL.—Referred to by Greeff in *Lehrbuch der speciellen pathologischen Anatomie*, Lief. 9, Auge; Hälfte I, p. 180, Berlin, 1902.

(16) E. VON HIPPEL.—"Hydrophthalmos congenitus," *Bericht über die* 26 *Versammlung der Ophthalmologischen Gesellschaft, Heidelberg*, 1897.

(17) PECK.—*Medical News*, November, 1898.

(18) DE BECK.—Quoted by Truc in the article "Lésions obstétricales." The following is the reference:—David de Beck, *Acad. de Méd. de Cincinnati*, 8 Avril, 1889; et *France médic.*, 7 Septembre, 1889, p. 1229.

(19) E. NETTLESHIP.—In a communication to the Ophthalmological Society of the United Kingdom, October 16th, 1902.

(20) MAYGRIER.—*Leçons de Clinique Obstétricale*, 1893.

(21) SIMEON SNELL.—In a communication to the Ophthalmological Society of the United Kingdom, 1902–3.

(22) BEAUMONT.—*Provincial Med. Journ.*, 1892.

(23) See one of the cases in the postscript to the article "Traumatic Keratitis of the New-born," vol. xxii of the Society's *Transactions*. (*March 13th*, 1903.)

---

8. *Notes of a case of dislocation of the eyeball.*

By J. B. LAWFORD.

ARTHUR B—, æt. 7 years, was brought to the Royal London Ophthalmic Hospital on December 6th, 1902, with the history that about an hour previously he had fallen, striking his face against an iron fender.

Digitized by Google

On examination, the left eyeball was found to be completely dislocated forwards, the globe resting on the cutaneous surface of the eyelids, which were depressed so that the eyelashes could not be seen. The ocular conjunctiva was slightly injected, and the tendons of the recti muscles could be plainly seen stretched beneath it. The cornea was dry, hazy, and anæsthetic; the pupil little, if at all, larger than that of the right eye. There was no bruising of the eyelids or other parts of the face, but there was a small superficial wound of the upper lid close to the inner canthus.

Although rather pale and subdued, the child did not seem to be in much pain, and examination and attempts to replace the globe were not resented.

Under chloroform, reduction of the displaced eyeball was easily effected by lifting the edge of the upper eyelid forwards with a squint hook, and at the same time pressing the globe backwards. A pad and bandage were firmly applied, and after a couple of hours' detention in the hospital, the child was allowed to go home.

Progress (December 10th).—No pain. Slight fulness of left eyelids. A few blood extravasations in the ocular conjunctiva, chiefly in the lower and outer part. Slight proptosis. Ocular movements apparently full and unaccompanied by pain. Cornea bright. Left pupil larger than right, and action to light not good, due probably to atropine applied at the first visit. The boy seems to see well with the left eye. Ophthalmoscopic examination reveals nothing abnormal.

13th.—Left pupil still larger than right. V.: R. $\frac{6}{6}$; L. $\frac{6}{18}$.

20th.—Left pupil now equal to right, and acts well to light. There is still a slight degree of proptosis, but no limitation of movement of the left eye. V. $\frac{6}{6}$.

January 3rd, 1903.—Appearances now normal, except that the left eye is very slightly more prominent than the right, and the fold in the upper lid not so deep as that on the right side.

31st.—Appearances quite normal. V. = J. 1; left pupil

Digitized by Google

equal to right and equally active; fundus shows no abnormal conditions.

Remarks.—The mode of production of the dislocation in this case cannot be determined with certainty. Presumably a small projecting bar or knob on the fender penetrated the orbit on the nasal side (where the wound of lid was situated) and forced the eyeball out. Once the globe was through the palpebral fissure its return was prevented by the closure of the lids.

Simple traumatic dislocation of the eyeball would appear from published records to be a rare accident. No instances are to be found in the *Transactions* of this Society, with the exception of a case communicated to the meeting in October last by Mr. Nettleship for Mr. Baldwin. On that occasion Mr. Beaumont referred to a case which had come under his observation.

In the *Beiträge zur Augenheilkunde,* Bd. iv, Heft 31, 1899, Rothenpieler published an article on "Die Luxatio Bulbi," and gave a list of references dating from the sixteenth century. In the same year (1899) three cases of dislocation of the eyeball were reported at a meeting of the College of Physicians of Philadelphia (see *Ophth. Review,* vol. xviii). (*March 13th,* 1903.)

---

9. *A case of pulsating exophthalmos (traumatic).*

By Gustavus Hartridge.

Emily F—, æt. 10 years, came under my care at the Royal Westminster Ophthalmic Hospital on October 9th, 1902. The child's mother gave the following account :— On July 1st, 1902, while playing in a hayfield with some other children, was struck with a hayfork, one of the prongs entering the left side of the nose slightly below and to the inner side of the inner canthus. Soon after this the eye

Digitized by Google

was noticed to be more prominent than the right eye, and it turned inwards.

R. V. $\frac{6}{6}$, Hm. 50 D. = $\frac{6}{6}$.

L. V. $\frac{6}{18}$, Hm. 50 D. = $\frac{6}{18}$.

The left eye is very prominent, and is strongly convergent. Complete paralysis of left sixth nerve.

Right disc normal. Left disc hyperæmic. Retinal veins full and tortuous. Loud bruit, of a blowing character, heard over the left side of the head.

June 10th, 1903: R. V. $\frac{6}{6}$; L. V. $\frac{6}{6}$. The bruit has altered, and is now of a whistling character.

(*Card specimen. June 11th*, 1903.)

---

10. *Blood in the anterior chamber, with staining of the cornea, simulating dislocation forwards of the lens.*

By Ernest Clarke, M.D.

F. C—, a lad aged 17 years, was first seen by me at the Miller Hospital on March 27th, 1903. He stated that he had been kicked in the right eye six weeks previously during a football match, and that he had not seen with the eye since.

On examination, the anterior chamber appeared to be full of blood, except in the centre, where there was a circular area of brownish-yellow colour. At the time the size of this patch was 6 mm., occupied exactly the central area of the cornea, and was remarkably like a small lens (or the nucleus of a lens) dislocated forwards into the anterior chamber, lying against the posterior surface of the cornea. In the lower part of the chamber the blood was of a very dark tinge, but in the upper part was bright scarlet, and looked like a recent hæmorrhage. The tension of this eye was slightly up, there was no perception of light, and he complained of no pain or discomfort.

Progress.—He was admitted and kept in bed, but little

Digitized by Google

change took place, the bright blood became darker and appeared to be becoming absorbed, and in a few days a small quantity of fresh bright blood appeared, evidently a fresh hæmorrhage. Since then the central area has slightly diminished, and now is 1 mm. less, and the resemblance to a lens is less marked.

Small fresh hæmorrhages are constantly occurring, and now and then parts of the iris on the upper part come into view, and are seen to be of the same colour as the central patch. The blood in the upper part of the chamber is very fluid, as shown by the change of its position by the patient altering the position of the head.

Remarks.—E. Treacher Collins* has shown that the central area is due to staining of the cornea by hæmatoidin, and that the stained area contracts, the contraction being due to absorption of the hæmatoidin granules, commencing at the periphery equally in all directions.

(*July 3rd*, 1903.)

The PRESIDENT (Mr. William Lang) said there would be no harm in watching the eye for a time.

* Collins, E. T., *Transactions*, vol. xv, p. 69.

Digitized by Google

XIV. OPERATIONS, INSTRUMENTS, AND APPLIANCES.

1. *Subconjunctival fistula formation in the treatment of primary chronic glaucoma.*

By Major H. Herbert, I.M.S.

Method A.—*By subconjunctival prolapse of iris.*

In this Report of work done in Bombay I wish to consider results, rather than to lay claim to any originality in ideas or in practice.*

In India the great bulk of primary glaucoma is distinctly chronic, and many of the patients submit to operation only when but little sight is left. Thus, we have a large proportion of the eyes in which typical iridectomy fails to relieve tension, or in which it destroys sight through various complications.

In my hands, large iridectomy in advanced glaucoma was apt to be complicated by loss of vitreous, at times with expulsion of the lens, and possibly with hæmorrhage from the fundus. The fault probably lay partly in the execution of the operation.† I also made acquaintance with fundus hæmorrhage apart from loss of vitreous, and with so-called "malignant glaucoma."

* This statement will serve to make reference to the work of others unnecessary.

† The edge of the narrow knife used had at times to be turned forwards to avoid too peripheral a wound, and the back of the blade may have pressed upon iris and suspensory ligament. I doubt, however, whether my experience was exceptionally unfortunate in the class of case dealt with.

Digitized by Google

Observing the results of other operators, as well as my own, the much more general success obtained when the iris by chance healed in the wound was soon noticeable. With this I coupled an observation upon prolapse of iris following cataract extraction. A large prolapse uncovered by conjunctiva was often associated with iritis from the beginning, whereas a similar prolapse, mainly or entirely covered by conjunctival flap, had not this liability. In the former case the uveal tract was exposed to the attack of the pyogenic organisms so commonly present in the Indian conjunctival sac, whereas the conjunctival covering in the other cases appeared sufficient to protect the eye from bacterial invasion. We must admit that the evil repute of cystoid cicatrices in rendering eyes permanently liable to infection has been earned mainly—at any rate, in the cases following cataract extraction—by prolapses and incarcerations, partly or completely uncovered by conjunctiva. Thus it seemed at least permissible to attempt to determine to what extent the immediate protective influence of a conjunctival covering over prolapsed iris might remain permanently, the more so since operating for fistula formation would enable one to reduce the size of the wound, aud so lessen the danger of the above-mentioned early complications. I have accordingly left prolapsed iris—in nearly all cases purposely—in 130 operations for primary glaucoma.* Of the 130 eyes, 48 were seen again after operation at periods varying

* Nearly all the glaucomas were chronic, simple, or congestive. A few secondary glaucomas, similarly operated upon, are not considered here; and three operations have been excluded upon eyes probably free from glaucoma. Two of these three eyes were in the one patient. They felt perhaps a trifle softer than most normal eyes, but the eye with more decided loss of sight seemed a trifle less soft than its fellow; and the fields of vision (of projection in the worse eye) were contracted chiefly inwards. There was no cupping of the disc in the better eye of the two; the disc of the other eye could not be seen owing to a cataractous lens. In the third case referred to there was no fellow-eye to serve as a standard of tension, and there was obvious fundus disease and no cupping of the disc; but the eye felt hard, and it was thought that high tension might have partly accounted for defective vision.

Digitized by Google

from six months upwards. These results have been collected in the table on page 338, and to them have been added 3 glaucomas in which subconjunctival prolapse had been obviously left unintentionally by a former operator.* In all but 18 of the 130 eyes some iris was removed; in 5 of these 18 eyes the iris was divided, but in the remainder it was left uncut.

Results.—(1) The question to which one's attention turns primarily is that of *late infection* introduced through the fistulous scar. So far as I know, none of the eyes operated upon have yet been lost through late infective inflammation. One patient (No. 8 in the table) came back two years and two months after operation with iridocyclitis of very threatening appearance, but it rapidly gave way to energetic treatment by the administration of mercury and the use of atropine. This is the only case of the sort that we have seen. And that this apparently almost complete exemption has been largely attributable to protection afforded by the remains of conjunctival covering is shown by seven infective inflammations that we have seen during the same period of observation in eyes where accidental prolapse, partly or entirely bare of conjunctiva, had complicated cataract extraction or other glaucoma operation. And the total number of uncovered prolapses over which these seven† late infections were spread is probably rather less‡ than 130, the number of

* Other eyes that had been similarly operated upon were seen at times, but without sufficiently exact histories to be of use.

† Of these seven prolapses, five followed cataract extractions, and two followed glaucoma operations. Five of the seven operations were performed within the period of the 130 special glaucoma operations now considered. Four of the seven infections led to complete loss of sight.

‡ My total cataract operations in India number not quite 2800. Slightly less than 500 of them were simple extractions. Among them the prolapses, 41 in number, were accurately recorded; they were nearly all partly or entirely uncovered by conjunctiva. Among the others, the "combined" extractions, I feel certain the average prolapse rate was under 3 per cent., *i. e.*, under 70 in all. And among the few simple iridectomies for glaucoma that were performed, there were very few uncovered prolapses.

Digitized by Google

covered prolapses specially considered, and the dates of formation of the large majority of the bare prolapses fall within the same period.

Speaking of infection as a whole, however, I have to chronicle two inflammations which set in immediately after operation, apparently due to organisms introduced at the operations. One of these (Case No. 44 in the table) ended in partial occlusion of the pupil, with vision rather worse than before treatment. The other led to gradual total loss, and, I believe, to sympathetic inflammation * of the fellow-eye. Possibly such an accident may be more liable to complicate the prolapse operation than to complicate simple iridectomy, but in any case it should be entirely preventable. Up to the time of this accident I had not taken the same precautions as to antisepsis in glaucoma operations as had been found necessary in our cataract extractions, not realising that such a serious complication was at all likely to happen.

(2) *The relief of tension* provided by a fistulous cicatrix appears to be *certain* and *permanent*. This statement may need corroboration. But my cases constitute powerful evidence in this respect, because so many of the eyes were at a very advanced stage of glaucoma, and therefore especially likely to show early evidence of failure. Yet in no single case has there been any question of a return of *plus* tension after free filtration had once become established. It must be borne in mind, however, that the prolapsed loop of iris is not at once pervious. In a few eyes the immediate lowering of tension provided by the leaking wound was followed by a period of slightly raised tension, lasting even up to two or three months. In

* Iritis was found in the operated eye the day after operation. The vision, however, improved, and the inflammation was not energetically treated. It persisted, and nearly six weeks after the operation similar chronic inflammation had begun insidiously in the fellow-eye, with a tendency to increase of tension. Iridectomy was performed in this eye a fortnight later, but both eyes went slowly to the bad. The infection should have been controlled and confined to the one eye by the administration of mercury—after Schirmer, and by the use of atropine.

Digitized by Google

some of the more advanced glaucomas the final result may have been impaired by this slight rise of tension, but daily massage, with occasionally eserine, did much to control the high tension and to shorten its duration, and fortunately the patients affected remained under treatment for sufficiently long periods. There is little doubt that one should always combine a small iridectomy with the operation to form a fistulous scar, in order to obtain what relief one can by the more recognised proceeding, and to rely upon the weak scar only as a sort of safety-valve. Especially is iridectomy needed as an adjunct when the iris has undergone considerable atrophic change under the influence of the glaucomatous process. When it has become fibrous, tough, and inelastic, it much less readily undergoes the absorption necessary to admit of the passage of aqueous through it.

It was considered that in many eyes the tension finally was about — 1; and when both eyes of a patient were similarly operated upon, the eye most damaged by the previous high tension was sometimes appreciably softer than its fellow. It seems reasonable to attribute this subnormal tension, in part, to atrophy of the ciliary body. And perhaps one ought to expect *minus* tension in eyes cured of very advanced chronic glaucoma, and to admit that progressive deterioration of sight after iridectomy for glaucoma may at times be due to insufficiently relieved tension, even although the latter feel quite normal.

(3) Bearing upon this question of tension is the fact that *the effect* of fistula formation *upon vision* has proved much more favourable than could be expected in similar cases from simple iridectomy. No case of chronic glaucoma appears to be too advanced for treatment if fingers can be counted * at any distance, however contracted the field of

* In some cases where vision was reduced to the perception of moving bodies, and where operation was done as a more or less experimental accompaniment to operation upon the fellow-eye, a moderate recovery of sight was obtained. Some of these are included in the table of results; others were observed for too short a period to obtain a place in the table.

Digitized by Google

projection * may be. In nearly all cases there was definite improvement † in vision, at least for a time, and in some eyes with the most contracted fields the improvement promises to be permanent. Where progressive diminution in sight set in later, it was often difficult to apportion the influence of slow cataract formation. Seven cases in which there was more or less evidence of further atrophy of optic nerve or retina—in spite of relieved tension—are numbered in the "Field of Projection" (F.P.) column in the table of results.

The superiority of the visual results of fistula formation over those of typical iridectomy ‡ in advanced chronic glaucoma is sufficiently marked to emphasise the probability already suggested—namely, that failures really attributable to imperfectly relieved tension are often put down to atrophy progressing in spite of relieved tension (see, for instance, our late President's Address on Glaucoma).

(4) *Early complications.*—Besides the two immediate infections given above, a complication that has occasionally caused anxiety has been delayed refilling of the anterior chamber. In one of these cases, the lens became rapidly cataractous, and was extracted after a month with the anterior chamber still quite empty. During this month, the field of projection, which was formerly good, became much contracted, and the iris

* The perimeter could not be used for the determination of fields of vision, owing to the want of trained assistance. It need scarcely be mentioned that any contraction of the field of projection in chronic glaucoma generally implies a somewhat advanced stage of the disease, such as would give a very marked contraction of the perimetric field. I have not found that operation was liable to do harm in eyes with very contracted fields of vision.

† I came to expect more regular and more decided increase of sight in the advanced cases than in those where central vision was still fairly good. In the latter the effect of the astigmatism produced by the operation, and of its sometimes imperfect neutralisation by lenses, was perhaps more appreciable.

‡ It must not be forgotten that many of the good results of intended simple iridectomy are got, not through reopening of the filtration angle, but through unintentional incarceration of the iris.

Digitized by Google

assumed a greyish atrophic appearance, although the tension of the eye was never found at all elevated. The patient afterwards saw only moving bodies; before operation she counted fingers at three feet. This and the sympathetic case already given are the only two operations among the 130 which proved directly disastrous. This proportion of serious early complication is very much lower than I was accustomed to formerly, when I performed large simple iridectomies.

In another case, with still empty anterior chamber, the tension rose twenty-one days after operation. An equatorial puncture was made, and the cornea pressed upon. After this the chamber refilled partly, but always remained shallow, and daily massage was needed to keep down the tension for about two months. Finally, three months after operation, the tension kept low, and the sight had improved from fingers at six and a half feet to $\frac{6}{60}$ with + 1·75 D. cyl.

In another patient both eyes were operated upon together (Nos. 42 and 43 in the table). One chamber was quite empty for ten days, the other longer. An equatorial puncture was made in the latter eye seventeen days after operation. Both eyes required daily massage for about six weeks for *plus* tension, and in both the chambers remained permanently shallow. In one (No. 43) the vision seemed to have been impaired by the complication.

Other delays in refilling were for shorter periods, and apparently did no harm.

The empty anterior chamber appears to be attributable to persistent leakage through the wound (from imperfect healing?) in spite of the conjunctival flap, and perhaps also to deficient secretion of aqueous. It appears to be never met with after cataract extraction with complete conjunctival flap, but I have once met with it after simple iridectomy for glaucoma.* It cannot be due simply to retention of fluid behind the lens, or there would be high tension at once—as in so-called "malignant glaucoma," which I have never seen after these prolapse operations.

* In this case there was ripe cataract also. Three weeks after the iridectomy the chamber was quite empty and high tension returned. The lens was extracted with difficulty after an equatorial puncture, but later the tension again rose and the eye did badly.

Digitized by Google

The only remaining early complications were (1) a small escape of vitreous in a case when the incision * was made a trifle larger and more peripherally than usual; and (2) a large fundus hæmorrhage, which was eventually absorbed (Case No. 10 in the table).

Conclusions.

The perspective in our views upon the operative treatment of chronic glaucoma evidently needs correction. Too much has been made of the fear of late infection, and too little of the fact that fistulous scars provide the only certain means of permanently relieving some glaucomas. An eye cured by typical iridectomy is undoubtedly a sounder organ than one with a filtering cicatrix. But we need something to fall back upon (1) where iridectomy has already failed; (2) where it seems likely to fail—possibly in chronic simple glaucoma at any stage, but more especially in all advanced chronic glaucomas, where there is but little sight left to experiment with; and (3) where patients, as in India, are not expected to return promptly for further treatment on failure of a first operation.

In late infection the inflammatory attack, even in India, generally drives patients back for treatment, which treatment—by the free administration of mercury, after Schirmer—is frequently effective. It is doubtful if the invasion by pyogenic organisms is in any way favoured by the connection of the uveal tract with the weak scar, but probably by it the organisms are enabled to do much more harm † to the individual eye, and are more likely to

* Two instances of late inflammation in eyes where I had established iris-free fistulæ, by conjunctival infolding, were quite mild. I have also noticed that on the breaking down of old corneal leucomata the accompanying irido-cyclitis has been readily overcome by treatment in cases where the leucomata were free from iris adhesion.

† The incision, 5 or 6 mm. long, was nearly always made with a narrow tapering, old Graefe's knife (*see* Appendix). In making a small section

Digitized by Google

set up sympathetic ophthalmia in the fellow-eye. Most, if not the whole of this connection of the iris with the fistulous track may be readily severed, if desired, by a second small operation—a subconjunctival sclerotomy upwards, dividing the adherent base of the iris. I did this only in a few instances where a simple prolapse had been made without iridectomy.

Perhaps the weak point in this treatment of glaucoma is the possibility of exciting sympathetic loss of the fellow-eye. But the chance is very remote, taking into consideration the rarity of the occurrence of late inflammation in the operated eye. If the patients be warned of the possibility, they are pretty sure to take the warning to heart, and energetic treatment by mercury, or, if preferred, enucleation of the operated eye when inflamed, should make the fellow-eye safe. It is better to have to enucleate one eye than to lose twenty or thirty by unrelieved tension. Finally, in our practice the fellow-eye was frequently already useless from absolute glaucoma, and so did not need consideration.

It appears to me that we have no right to allow any eye to become useless through unrelieved chronic glaucoma; rather than this, it is one's duty to subject the patient to the small risks pertaining to the formation of a filtering cicatrix.

Appendix to Method A.

On the local changes occurring in and about the subconjunctival prolapse.

My aim was usually to make the prolapse as small as possible. A little difficulty was experienced in steering a course between the production of a considerable local prominence, on the one hand, and total retraction of iris

with this knife the direction of the blade must be very little altered throughout, otherwise the making of the very oblique counter-puncture requires considerable force.

Digitized by Google

or an insufficient incarceration, on the other hand. In the cases where no iris was excised an elevation always persisted. Sometimes the elevation became of a fairly uniform grey colour. In other protrusions finally the dark remains of iris were plainly visible in the centre—the area of free filtration—surrounded by a narrow whitish zone of sodden conjunctiva, whence the normal pigment had been washed away, accumulating in an ill-defined outer ring about the margin of the prominence. As mentioned by Berry, the neck, by which the cavity of the so-called "cyst" communicates with the anterior chamber, often becomes sufficiently closed to prevent emptying of the chamber when the cyst is laid open. The corneal astigmatism produced by the prolapse appears to have little relation to the height of the swelling that persists; it varies rather with the extent of wound involved.

Total retraction of iris occurred once,* and an incomplete incarceration or adhesion of iris once, in cases excluded from my list; and in Case No. 48 in the table, although there was a little filtration, it may possibly have been insufficient. To prevent retraction of iris, it was found advisable to operate usually without previous instillation of eserine; and it was found better to make the sclero-corneal section with a very narrow Graefe's knife, rather than with a triangular kerotome, to ensure a uniformly peripheral position of the wound on the deep surface of the cornea.

Over some of the smaller prolapses there formed, after a few months, sharply outlined, pale, and translucent vesicular conjunctival thickenings, 3—6 mm. in diameter —"filtration areas," showing faintly through them the dark remains of iris, and surrounded by a little pigment washed out of the patch of conjunctiva. In other instances, where possibly a thinner conjunctival flap was made, the small prolapse simply became adherent to the overlying thin membrane. In other eyes the small bit of iris was indistinctly seen buried beneath slightly œdema-

* The simple iridectomy that resulted appeared to be effective.

Digitized by Google

tous conjunctiva. The absence of a filtration area perhaps indicated that the accompanying iridectomy was efficient, and the filtration through the abnormal outlet consequently small in amount. In these eyes with but slight external changes one would expect the liability to bacterial invasion to be correspondingly reduced.

Whatever the result of the prolapse, there was nearly always some surrounding conjunctival œdema. The pitting on pressure with a probe above the cornea was distinctly deeper than below the cornea. This pitting is suggested as a test for filtration through scars after sclerotomy or simple iridectomy. It was found in an iridectomised eye, with but the faintest supplementary evidence of filtration.

METHOD B.—*By conjunctival infolding.*

This method will be only briefly treated here.

Those who use very complete conjunctival flaps in operating for cataract must have noticed at times that early union of the flap and its subsequent stretching under the pressure of reaccumulated aqueous has been sufficient to keep separate the lips of the subjacent sclero-corneal incision, preventing union at least within the usual period of observation. If permanent filtration could be established thus in glaucomatous eyes, it promised to be a less dangerous method than by prolapse of iris. Accordingly, in April, 1901, I began operating by a small sclerotomy, together with a very long conjunctival flap. The flap was pushed into the anterior chamber, folded so that its end remained outside. The first attempt has proved particularly interesting, as the eye has been under frequent observation for almost two years.* It serves to show that apparently permanent and perfectly satisfactory drainage can be established in this way without the intervention of iris, as certified by a round

* I have had other successful cases under observation for various periods over a year.

Digitized by Google

central pupil. In this, as in most of the successful cases, the conjunctiva did not remain long infolded; after a few days—as soon as the anterior chamber had refilled—the proximal part of the flap lay as a distended fold over the scleral incision; and in this particular instance the flattened, semi-translucent remains of the flap still lie over the corneal margin. These cases establish the fact that a quite temporary separation of the lips of a sclero-corneal incision is effective in providing a permanent fistulous track. But this method of operating proved, as would be expected, very uncertain. It mattered little that the iris, in spite of eserine instillation, was liable to prolapse; a small iridectomy was generally added on this account. But in many eyes it was found impossible to keep the conjunctiva infolded. The flap was modified and subdivided, and various sutures were applied. The sutures were mostly ineffective; at other times they appeared to strangle or to irritate the flap, so that it became thickened by inflammatory infiltration. After twenty-three trials, the method was given up for a time. There was fairly frequent failure to relieve tension, and in one eye the fistula formed was too open. The eye was very soft, and eventually went to the bad.*

Quite recently I added a special suture, and have performed ten operations† with fairly promising results. A small, sharp, curved needle was used with sterilised silk thread; the double thread was knotted about one to two inches away from the needle. The point of the latter was passed through the centre of the conjunctival flap and down through the sclero-corneal wound, barely into the anterior chamber, and brought forward through the

* Ten months after operation, there was a mild attack of iritis, which, being untreated, reduced vision from $\frac{6}{5}$ to fingers at 7 feet 4 inches ordinarily, or to $\frac{6}{60}$ after the use of atropine. One year and seven months after operation, the vision was *nil*; the eye was injected, and there had been pain for a week. There was probably a complete detachment of retina.

† Without counting two eyes, blind from absolute glaucoma, that were operated upon.

Digitized by Google

cornea. When the thread was pulled upon, the knot drew down the centre of the conjunctival flap, and pressed it against the posterior surface of the cornea. This knot was retained in position by a second knot immediately in front of the cornea, got by cutting away the needle and tying together the two ends of thread thus set free. A small iridectomy was added in nine of the ten eyes after the suture was in place.* The suture was removed after twenty-four hours.

In two cases the infolded conjunctiva became adherent to the lens capsule; in one of these there resulted a little localised lenticular opacity. In two eyes where the suture was passed only into the wound—not into the anterior chamber—the complete reduction of tension did not appear quite assured. In another eye the tension was lowered possibly rather more than needful. In one eye—with vision only of moving bodies, before and after operation—there was some mild iritis later, apparently infective.

Bearing in mind that a temporary separation of the sclero-corneal wound only is required, two unsuccessful attempts were made to form subconjunctival fistulæ, utilising other means than the conjunctiva to separate the lips of the wound. The first method was *temporary iris prolapse*, or iridectomy in two stages. A conjunctival covering can be peeled off underlying prolapsed iris up to six days after the formation of the prolapse, and the iris excised after pulling upon it to free it from the scleral opening. This method was tried several times, but subconjunctival filtration failed to develop except once, apparently because the conjunctival flap became impervious through inflammatory thickening. The second attempt was the subconjunctival *insertion of small bits of bent capillary glass tubing* through sclero-corneal punctures. Possibly if the wounds had been made longer, and the bent glass kept near one end of the section, fistulæ might have resulted. As it was, the thickening around the foreign body was sufficient to prevent filtra-

* The iris nearly always prolapsed while the needle was being forced through the cornea.

Digitized by Google

tion. These latter attempts were only made upon eyes blind from absolute glaucoma. In Bombay there is a fairly plentiful supply of such cases.

The conjunctival infolding operation might perhaps be further modified in order to secure uniform results. As it stands, however, it appears to have some value. I can recall at least one eye in which it would probably have arrested a progressive secondary glaucoma, where chronic iritis had followed a combined cataract extraction, and where the narrow and tough remains of iris were unsuited for use in a prolapse operation.

Postscript.—In response to inquiries regarding the conjunctival infolding operation, the sclero-corneal incision is made with a very narrow, tapering, old, Graefe's knife, the direction of the blade being but little altered throughout. The wound is about 4 mm. long on the deep surface of the cornea. The conjunctiva may need to be pulled up with fixation forceps while the flap is being cut in order to make the latter sufficiently long. The passage of the thread through the cornea requires a sharp needle, the use of some force resisted by counter-pressure with fixation forceps applied to the front surface of the cornea, and a steady patient with the eye turned downwards. The iris generally prolapses while the needle is being inserted, although eserine may have been instilled beforehand; the prolapsed iris is then cut off. The iridectomy is not made before the needle is inserted, since the iris in position is useful to protect the lens from possible puncture by the needle.

Table of Results of Prolapse Operations, observed for Six Months or more.

P.O. = Period of Observation. V.R. = Visual Result (astigmatism uncorrected, except where specified). F.P. = Field of Projection of Light. R. = Remarks.

1.* P.O. 3 yrs. and 4 mos. V.R. **Improved** from moving bodies to fingers at 1 ft. 10 in. F.P. Much contracted except upwards.

2.* P.O. Ditto (same patient as No. 1). V.R. **Unaltered,** $\frac{6}{10}$. F.P. Good.

* These cases were not operated on by me, see reference in text, p. 327.

Digitized by Google

3. P.O. 3 yrs. and 1 mo. V.R. **Improved slightly** from fingers at 6 in. to 1 ft. F.P. Good at first; later a little contracted (l) everywhere. R. Lens cataractous, small, and tremulous.

4. P.O. Ditto. V.R. **Improved** from fingers at 10 in. to 4 ft. 1 in. (not improved by cylinders). F.P. *Nil* down and in, moderately contracted above, and very slightly contracted outwards. R. Lens decidedly cataractous.

5. P.O. Ditto (same patient as No. 4). V.R. **Improved** from fingers at 10 in. to 10 ft. 4 in. with — 3 D. cyl. F.P. Much the same as in No. 4. R. Lens slightly cataractous.

6.* P.O. 3 yrs. V.R. **Improved slightly** from fingers at 3 ft. 6 in. to 4 ft. 2 in. F.P. Contracted inwards only. R. Lens cloudy centrally.

7. P.O. 2 yrs. and 7 mos. V.R. **Improved** from moving bodies to fingers at 2 ft. 4 in. with — 6 D. cyl. F.P. *Nil* up and in, good down and out.

8. P.O. 2 yrs. and 2 mos. V.R. **Improved slightly** from $\frac{6}{36}$ to $\frac{6}{24}$ 1 yr. and 8 mos. after operation, but when last seen temporarily reduced by irido-cyclitis to fingers at 10½ ft. F.P. Good. R. See reference in text, p. 327.

9. P.O. Ditto. V.R. **Unaltered,** $\frac{6}{60}$, but after operation required — 6 D. cyl. F.P. Good.

10. P.O. 1 yr. and 11 mos. V.R. **Improved slightly** from fingers at 7 ft. 2 in. to 9 ft. F.P. Slightly contracted in and down. R. The iris was much atrophied, and there were two equatorial staphylomata. The operation caused a very large fundus hæmorrhage, and there was a protracted "high tension period," so that the blood took several months to get absorbed.

11. P.O. 1 yr. and 10 mos. V.R. **Improved** from fingers at 2 ft. to 9 ft. 2 in. F.P. Much contracted below only.

12. P.O. 1 yr. and 9 mos. V.R. **Improved** from fingers at 1 ft. to 7 ft. F.P. Good.

13. P.O. 1 yr. and 6 mos. V.R. **Reduced** from fingers at 1 ft. to moving bodies. (Temporarily improved to 2½ ft. six weeks after operation.) F.P. Good at first; later almost *nil* inwards, but good up, down, and out (2). R. An unripe cataract was extracted 1 year and 4 months after the glaucoma operation; afterwards there was fairly dense "after-cataract."

14. P.O. Ditto. V.R. **Improved slightly** from $\frac{6}{1\frac{1}{2}}$ to $\frac{6}{9}$, with — 3·5 D. cyl. F.P. Good.

15. P.O. 1 yr. and 5 mos. V.R. **Reduced slightly** from $\frac{6}{15}$ to $\frac{6}{24}$ with — 1 D. cyl. F.P. Good.

* This case was not operated on by me, see reference in text, p. 327.

Digitized by Google

16. P.O. 1 yr. and 4 mos. V.R. **Improved** from fingers at 3 ft. to 12 ft. 4 in. F.P. Good.

17. P.O. 1 yr. and 3 mos. V.R. **Improved** from fingers at 1 ft. 6 in. to 5 ft. 9 in. F.P. Contracted a little down and out, more so inwards.

18. P.O. Ditto. V.R. **Reduced** from fingers at $12\frac{1}{2}$ ft. to moving bodies. (Temporarily improved to $\frac{6}{24}$ five weeks after operation.) F.P. At first noted as "markedly contracted, least outwards." Later it was *nil* upwards and almost *nil* inwards; so there seems to have been a little further contraction (3). R. Before operation the lens was slightly hazy; afterwards there was quite enough cataract to account for the loss of central vision.

19. P.O. 1 yr. and 2 mos. V.R. **Improved** from fingers at 13 ft. to $\frac{6}{60}$ with -1 D. sph. and $+5$ D. cyl. F.P. Good.

20. P.O. Ditto. V.R. **Reduced,** by cataract, from $\frac{6}{18}$ to $\frac{6}{60}$. F.P. Good.

21. P.O. Ditto (same patient as No. 20). V.R. **Reduced,** by cataract, from $\frac{6}{24}$ to $\frac{6}{60}$. F.P. Good.

22. P.O. Ditto. V.R. **Improved** from $\frac{6}{36}$ to $\frac{6}{6}$ partly with $+1{\cdot}5$ D. cyl. F.P. Slightly contracted everywhere.

23. P.O. Ditto (same patient as No. 22). V.R. **Improved slightly** from $\frac{6}{6}$ to $\frac{6}{5}$ partly with $+1$ D. cyl. F.P. Good.

24. P.O. Ditto. V.R. **Improved** from fingers at $3\frac{1}{2}$ ft. to 8 ft. (Temporarily improved to 13 ft. 4 in. five months after operation.) F.P. Much contracted everywhere. R. Incipient cataract accounted for the later deterioration of sight.

25. P.O. Ditto. V.R. **Reduced** from fingers at 12 ft. 4 in. to 5 ft. 4 in. F.P. Good. R. Possibly uncorrected astigmatism (untested) may have accounted for the reduced sight.

26. P.O. 1 yr. and 1 mo. V.R. **Reduced slightly** from fingers at 1 ft. to 6 in. (Temporarily improved to 3 ft. three months after operation.) F.P. At first "contracted inwards;" later it was *nil* inwards, and extremely contracted up and down (4).

27. P.O. Ditto. V.R. **Reduced slightly,** by cataract (posterior polar), from $\frac{6}{30}$ to $\frac{6}{24}$ with $-2{\cdot}5$ D. cyl. F.P. Good.

28. P.O. Ditto. V.R. **Improved slightly** from $\frac{6}{30}$ to $\frac{6}{24}$ with -5 D. cyl. F.P. Good.

29. P.O. 1 year. V.R. **Reduced,** by cataract, from fingers at 5 ft. 4 in. to 3 ft. 4 in. (Temporarily improved to $\frac{6}{60}$ with $-3{\cdot}5$ D. cyl. three months after operation.) F.P. Contracted inwards only.

30. P.O. 11 months. V.R. **Reduced slightly,** by cataract, from fingers at 4 ft. 2 in. to 3 ft. 6 in. (Temporarily improved

Digitized by Google

to 8 ft. two weeks after operation.) F.P. At first much contracted in, less so above and below; later seemed less contracted (!).

31. P.O. 11 months. V.R. **Unaltered,** fingers at 1½ ft. (Temporarily improved to 5 ft. 8 in. seven weeks after operation.) F.P. At first much contracted up and in, very slightly down; later *nil* inwards, otherwise as before (5). R. The later impairment of central vision appeared accounted for by increase of cataract.

32. P.O. 10 months. V.R. **Improved** from fingers at 7½ ft. to 15 ft. 3 in. with — 3 D. cyl. F.P. Good.

33. P.O. 9 months. V.R. **Improved slightly** from $\frac{6}{10}$ to $\frac{6}{5}$ with — 1 D. cyl. F.P. Good.

34. P.O. Ditto V.R. **Improved** from $\frac{6}{10}$ to $\frac{6}{6}$ with — 0·5 D. cyl. F.P. Good.

35. P.O. Ditto (same patient as No. 34). V.R. **Improved** from $\frac{6}{30}$ to $\frac{6}{15}$ with + 1 D. cyl. F.P. Much contracted in, slightly up.

36. P.O. Ditto. V.R. **Improved** from fingers at 2 ft. 4 in. to $\frac{6}{20}$ (!). F.P. Good.

37. P.O. 8 months. V.R. **Improved** from moving bodies to fingers at 4 in. F.P. Much contracted everywhere.

38. P.O. Ditto. V.R. **Reduced,** by increase of cataract, from 7 ft. 6 in. to 1 ft. 10 in. F.P. Not taken.

39. P.O. Ditto. V.R. **Unaltered** practically; fingers at 8 in., later at 10 in. (Temporarily improved to 3 ft. 8 in. a month after operation.) F.P. At first "almost *nil*" inwards; afterwards absolutely *nil* inwards (6). R. A doubtful slight high tension period was noted about a month after operation.

40. P.O. 7 months. V.R. **Unaltered,** moving bodies only. F.P. Much contracted, except outwards.

41. P.O. Ditto (same patient as No. 40). V.R. **Improved slightly** from fingers at 8 in. to 1 ft. with + 11 D. sph. after cataract extraction. (Temporarily improved to 3 ft. two months after glaucoma operation.) F.P. Much contracted, except outwards.

42. P.O. Ditto. V.R. **Improved slightly** from fingers at 8 ft. 2 in. to $\frac{6}{30}$ with — 2·75 D. cyl. F.P. Good.

43. P.O. Ditto (same patient as No. 42). V.R. **Reduced slightly** from fingers at 14 in. to 10 in. (Temporarily improved to 5 ft. 4 in. four weeks after operation.) F.P. At first much contracted inwards only; later *nil* in and up (7). R. There was a high tension period, following delayed refilling of anterior chamber. See reference in text, p. 330.

Digitized by Google

44. P.O. 7 months. V.R. **Reduced** by iritis from fingers at 9 ft. to 5 ft. 4 in. F.P. Good.

45. P.O. Ditto (same patient as No. 44). V.R. **Improved** from fingers at 9 in. to 1 ft. 8 in. F.P. Much contracted in, less so up and down.

46. P.O. 6 months. V.R. **Improved** from $\frac{6}{60}$ to $\frac{6}{20}$ with + 2 D. cyl. F.P. Good.

47. P.O. Ditto. V.R. **Improved** from fingers at $6\frac{1}{2}$ ft. to $\frac{6}{12}$ (!). F.P. Slightly contracted in and down.

48. P.O. Ditto. V.R. **Reduced** from fingers at 5 ft. 4 in. to 3 ft. F.P. Good. R. It was doubtful whether the impaired vision was due to increase of cataract. There may have been insufficient filtration (see reference in text, p. 334).; but the good field of projection is against this.

49. P.O. Ditto. V.R. **Improved** from fingers at 11 ft. 4 in. to $\frac{6}{20}$ with + 2·5 D. cyl. F.P. Good.

50. P.O. Ditto (same patient as No. 49). V.R. **Improved** from moving bodies to fingers at 2 ft. 4 in., outwards only. F.P. Only remaining outwards.

51. P.O. Ditto. V.R. **Improved** from fingers at 4 ft. to 15 ft. with — 2 D. cyl. F.P. Good.

Nos. (1) to (7) in the Field of Projection mark out the seven cases referred to on p. 330, in which atrophy of optic nerve and retina possibly or certainly progressed in spite of relieved tension.

The number of cases in which cataract has been relied upon to explain deterioration of vision must appear remarkable to those practising in this country. In India secondary cataract in advanced chronic glaucoma appears to come earlier and more regularly than in Europe.

(*June 11th*, 1903.)

Mr. PRIESTLEY SMITH said the Society was much indebted to Major Herbert for reporting the results of his very extensive trials, although it appeared that he could not yet strongly recommend any one of the methods in question. The arrest of chronic glaucoma, in some cases at least, was attainable only by the formation of a subconjunctival corneo-scleral fistula. Until the surgeon was able to obtain this condition whenever he wished to do so, and with safety, he would still approach every case of chronic glaucoma with some anxiety. It appeared to depend in some cases on tucking in of conjunctival tissue; in some on inclusion of iris tissue. He was uncertain whether a permanent aperture in the scleral tissue was

Digitized by Google

ever attainable without permanent inclusion between the lips of the scleral wound of either conjunctiva or iris. Mr. Treacher Collins might perhaps be able to answer that question. Major Herbert appeared to ascribe failure in some cases to the infolded conjunctiva being pushed out by the aqueous before it had had time to form adhesions. If that were so he would suggest that the addition of a subconjunctival scleral puncture might do just what was wanted. The speaker had for years past employed that method of slackening the eye as a part of every operation for primary glaucoma. It rendered the eye safe against those malignant symptoms which used to occur every now and then through jamming of the lens against the cornea, and ensured a condition of subnormal tension for at least forty-eight hours. It might probably give a fold of conjunctiva a better chance of retaining its position between the lips of the sclera.

Mr. E. Treacher Collins said that some years ago, from the pathological examination of several eyes which had been operated upon for glaucoma—some successfully and some unsuccessfully,—he had convinced himself that iridectomy relieved the tension in one of two ways: either it opened up the normal channels for exit of fluid by dislodging the faultily placed iris, or else a fistula was formed in the sclero-corneal tissue by the prolapse of a fold of iris, and through that fistula fluid was able to pass into the subconjunctival tissue. He had examined a number of eyes with cystoid cicatrices, and found that all had been formed by inclusion of a fold of iris, which kept the sclero-corneal tissue from uniting, the conjunctiva healing over the gap. An adhesion of the iris to the conjunctiva was thus established. He did not quite agree with Mr. Priestley Smith that there was a mystery about the formation of cystoid scars, and Major Herbert's paper offered good evidence to show that they could be produced without difficulty by allowing a portion of the iris to prolapse. He had intentionally produced cystoid scars in that way, but he thought it was questionable how far it was desir-

Digitized by Google

able to go to work regularly to do so. He had so far never attempted to produce one where there was a possibility of danger to the other eye. Where there was adhesion of iris to conjunctiva, there was considerable risk of any inflammation which might subsequently occur in the latter, afterwards involving the former, and so spreading into the eye, inducing intra-ocular inflammation. It might be thought by some that the epithelium of the conjunctiva would prevent the spread of inflammation to the iris, but in the case of cystoid scars the covering epithelium, when softened by inflammation, might readily become abraded, and infection pass into the subconjunctival tissue. There was, further, good evidence to show that some micro-organisms were capable of attacking epithelium and passing into the subepithelial tissue. This danger was not only a theoretical one; there were a number of cases recorded in the literature, both of this country and of others, in which there was a cystoid scar, and where, as the result of conjunctival inflammation, the patient subsequently got suppurative panophthalmitis. If patients could get a severe form of intra-ocular inflammation in that way it was reasonable to suppose that they might also have one of the milder forms, of a serous or plastic character, or an inflammation which was capable of spreading to the other eye and giving rise to sympathetic ophthalmitis. He had seen the latter condition excited by inflammation in an eye in which there was subconjunctival rupture of the sclerotic and prolapse of iris without any apparent perforation of conjunctiva; so if inflammation could spread through the conjunctiva in such a case it could presumably spread into an eye through a cystoid scar. He had been dissuaded from making cystoid scars in consequence of a case which he saw some years ago. He had suggested to a distinguished Member of the Society that the way to form a cystoid scar was to allow prolapse of iris to occur. That was taken seriously, and the gentleman in question went to work and made a cystoid scar in a patient suffering from glaucoma. Some

Digitized by Google

time afterwards the patient was shown to him suffering from sympathetic ophthalmitis, which followed on the operation. Although he (Mr. Collins) had several times done sclerotomy and allowed the iris to prolapse, or after doing an iridectomy had purposely not tucked back the angles of iris, he had only done so in those cases where there was either no eye on the other side or only a useless eye. He thought they ought to recognise that there was considerable danger in the procedure described by Major Herbert, although his cases were encouraging.

Sir ANDERSON CRITCHETT said it would probably be in the memory of many present that at the meeting where Mr. Nettleship introduced the subject of operation in simple glaucoma at the time of the last meeting of the British Medical Association in London, he (Sir Anderson) ventured to say that permanent fame awaited the man who could invent a safe cystoid cicatrix, and he believed they were still waiting for that invention. At that meeting he (Sir Anderson) mentioned one case which impressed itself upon his memory, and he would like to repeat it. It was that of a nurse at St. Mary's Hospital who had subacute glaucoma. She was admitted, and he operated upon the one eye. There was no anterior chamber. He put her under an anæsthetic, and it was necessary to operate with a Graefe's needle-knife. He succeeded in doing an iridectomy—not one of the neatest he had ever done,—and it was followed by a cystoid cicatrix. Shortly after she was threatened by an attack in the other eye, and he was able to do a very much better operation from a cosmetic point of view. But she had repeated threatenings of attacks of glaucoma, and on one occasion did have an attack in the eye in which he had done the better iridectomy. She never had a relapse in the eye which contained the cystoid cicatrix. He confessed he was with Mr. Treacher Collins in thinking that to endeavour to procure that cicatrix by deliberately impacting a piece of iris in the wound must be a rather dangerous proceeding. His (Sir Anderson's) Father's operation of iridodesis was

Digitized by Google

practically given up for that very reason, the Germans even going so far as to say it was a dangerous operation, because it was necessary to have an adhesion of the iris in the wound. Fond as his Father was of his child, he recognised that there were those dangers, especially as he had seen cases in other people's practice where his operation was followed by sympathetic ophthalmitis. Some Members would remember, and probably would be glad to forget, certain very exaggerated cases of sclerotomy which were brought to the Society by a gentleman who no longer existed, cases where not only the iris, but a considerable portion of the ciliary body was flapping over on to the cornea, and many of the Members saw the disastrous results which followed in the other eye in some of those cases. He had endeavoured throughout his professional career, and he hoped to continue it, to keep an open mind, and to try any operation which seemed to offer a reasonable prospect of legitimate success, and he would be prepared, if he saw a favourable opportunity, to try the operation described by Major Herbert. But it was one which should be undertaken with every possible care, and he agreed with Mr. Treacher Collins that it was one which should only be tried in cases in which the other eye, if present, was not a good one.

In reply, Major Herbert stated that in some of the successful conjunctival infoldings absolutely nothing of the conjunctival tissue remained permanently in the sclero-corneal wound as far as one could judge clinically. Mr. Priestley Smith's suggestion of the addition of a posterior scleral puncture to aid in keeping the conjunctiva infolded seemed a very good one, and might possibly enable one to dispense with the suture. As regards late infection, the point insisted upon was the rigid separation of the two kinds of prolapse. Cystoid cicatrices formed from prolapses entirely covered by conjunctival flap were evidently less dangerous than in cases where the prolapsed iris had been partly or completely bare of conjunctiva. Further, Schirmer's remarkable

Digitized by Google

results in the treatment of infective irido-cyclitis, both in controlling the inflammation in the infected eye and in preventing its spread to the fellow-eye, had scarcely yet been fully appreciated. Major Herbert had himself come to rely greatly upon the most decided benefit seen in early infective irido-cyclitis from getting the patient rapidly under the full influence of mercury. These two new features affected the problem of cystoid cicatrices so greatly as to show need for revision in the accepted canons of the treatment of chronic glaucoma.

---

2. *A portable perimeter.*

By G. Brooksbank-James.

This instrument is an attempt to combine in some degree the virtues of the larger and more elaborate instruments of Professor McHardy, Mr. Priestley Smith, and others with greater portability. The chin-rest is separate from the part containing the arc. The arc is made of aluminium and is jointed. The supports for the chin and for the arc are made of brass. The distance from the eye to the fixation point is taken by means of a rod of steel, which can be removed subsequently. The entire instrument occupies a wooden box of convenient size, which will fit into a small hand-bag.

(*Card specimen. May 7th,* 1903.)

3.—I. *Appliance for electric warmth to the eye.*

By Ernest E. Maddox.

It is more for their usefulness than for their novelty that I have ventured to bring my little eye-heaters before

Digitized by Google

you, since they are probably much too simple not to have been constructed before.

About ten years ago a suggestion appeared in an American journal for the construction of an eye-heater by interthreading a cushion of asbestos with platinum wire to be heated with electricity. I endeavoured at the time to get one constructed by an instrument maker, but met with difficulty, and the idea seems to have dropped, perhaps because platinum is expensive, and asbestos is not a very suitable material, being, when dry, hard and heavy.

Since then I contented myself, therefore, with either hot-water tubes or Japanese muff-warmers, until a case of urgent need led me a few months ago to the homely device of stitching to flannel some tinned flower-wire, which only costs one penny for twenty yards, or, better still, some inexpensive, silk-covered, platinoid wire, for I found by experiment that neither asbestos nor platinum was essential. The lightness of these new heaters enables them to be placed upon the eye without the patient feeling anything unusual in the dressings except the connecting cord through which the electric current flows.

They are made of a small size in order to confine the heat to the eyeball without involving the brain also, that they may not, like the more diffuse modes of heating, cause a feeling of faintness. The delicate regulation of the heat by the hour together is of great value, since for every patient there is just one temperature which affords the greatest comfort and does the most good.

To prevent the insulated connecting cord from dragging, it is convenient to curl a narrow strip of adhesive plaster round it and fix it to the temple, from which the cord is then made to pass over the ear.

Although I have sometimes kept a heater on day and night continuously, a somewhat better plan is to apply it for periods of three hours with about equal intervals.

Slight scorching of the flannel from the great heat for which some patients crave does not interfere with the

Digitized by Google

efficiency of the appliance, and the inexpensiveness of the latter encourages the cleanly practice of giving each patient a new heater.

In houses not supplied with electricity, an accumulator of large capacity but low voltage affords the best source; but, under certain conditions, it is a wise precaution to insert a short length of fuse wire in the connecting cord, which makes it impossible for the patient to give himself an overdose of heat. It is then quite permissible to let him regulate the temperature to suit the comfort of his eye by placing an adjustable resistance near him.

A small circle of lint or of thin silk is laid upon the eye, with or without a very thin layer of silk fluff or cotton wool; then the heater, after bending it to the shape of the eye with the wires downwards, and over this a light pad of frayed-out cotton wool, or, better still, lamb's wool, fixed either by strapping or by a turn of "Japanese crêpe" bandage.

The uses of dry heat are already too well known to need description. *Rheumatic* affections of the eye, whether of the iris, the ciliary body, or the sclera, are those in which the most immediate relief is given, the pain often disappearing within a minute or two. Next in order come *gouty* affections, including glaucomatous iritis, for which so little else can be done. Many neuralgic and glaucomatous conditions receive benefit, and in most of them, I think, the effect of heat is aided by dionin and thwarted by adrenalin.

The CHAIRMAN (Mr. William Lang) thought the heater would be found very valuable. He (Mr. Lang) had used a more cumbersome one, more or less of a conical shape, a sort of coil, which acted in the same way but did not come into contact with the eye. He had found it rather clumsy, and no doubt Mr. Maddox's instrument would be more serviceable.

Digitized by Google

II. *A new adjustable pocket transformer.*

I now come to the little pocket transformer which forms the subject of my second communication. I have only been able to show you the first rough experimental model, as the finished instrument is not ready.

Where an *alternating* current is available, transformers afford the best means of utilising the current from the main for the purpose of eye-heating, and this for two reasons: first, no metallic connection can for a moment be established between the current in the main and the wire which leads to the patient; and, secondly, the transformer converts a small current of high electro-motive force from the mains into a larger current of low electro-motive force in its secondary coil, thus reducing the voltage in the cords which proceed to the patient to one of perfect safety.

The best transformer in present use was introduced by Mr. Woakes about eleven years ago, and is simply a modification of the "Sledge" coil of Du Bois-Reymond, so well known to all. For ophthalmic purposes, however, it is not sufficiently portable, nor does it allow of any screw adjustment for a delicate graduation of the current.

The little instrument which I have shown you meets all these difficulties. It is provided with a plug at one end which enables it to be tapped into any incandescent lamp-holder, where it hangs up out of the way while a thin cord drops from it to the patient's eye.

To obtain a screw action I have made a long tunnel through the centre of the iron core to lodge a screw, by the rotation of which the secondary coil is moved gradually over the primary.

So delicate is the adjustment that one whole revolution of the handle only alters the electro-motive force by about one-tenth of a volt. This makes it also an ideal apparatus for small eye cauteries, the temperature of which can be

Digitized by Google

regulated to a greater nicety than by any other apparatus known to me; but it needs to be arranged in a slightly different way for this purpose.

A valuable feature for eye-heating is the absence of any necessity for an incandescent lamp, which would disturb the physiological rest of the retina.

At first sight it may seem rather a liberty to make a tunnel through the heart of the core, and the question naturally arises whether the core is weakened thereby; I believe, however, that, provided the weight of metal be the same, there is no loss of power whatever.

In a hospital supplied with the alternating current it is most convenient to be able to carry this instrument in one's pocket, with the heater attached ready for use. It becomes immediately available by simply tapping it into the holder of the nearest incandescent lamp.

III. *A circular-shaped lamp resistance.*

Lastly, I have endeavoured to meet the need for an electric supply when the current in the mains is of the *continuous* variety, but this is not so easy.

The lamp resistances usually sold consist either of one series lamp-holder for suspension in a lamp-socket, or of a box on which the lamps stand erect side by side, and which is very apt to get knocked over. The design which I have shown you is a kind of universal lamp resistance, and of a much more compact nature, consisting, as you see, of a circular brass band in which the lamp-holders are fixed radially, four of them being in parallel, while one, and also a pair of binding screws, are placed in series with these four. Any lamp placed in one of the four contributes its current to the efferent cord, and by combining lamps of different candle-powers we can get almost any current we like. It hangs up, out of the way, from any lamp-socket.

We only need to know how much current passes through each kind of lamp, and this is most easily calculated from the figures marked on all good lamps.

Digitized by Google

It is a great convenience to have the choice of the binding screws, or of the bottom lamp-holder, for the attachment to whatever connecting cord we may have occasion to use.

For eye-heating it is well to have a means of gradually increasing or of decreasing the current, and the best plan for this is to attach a shunt by means of a cord to the binding screws.

The more of the current we allow through the shunt the less goes to the patient's eye. The eye-heater should have a lamp-plug at the proximal end of the cord for insertion into the lamp socket which hangs between the two binding screws.

The appliance also affords a very beautiful means of administering either continuous currents instead of a galvanic battery, or, with the alternating current, sinusoidal currents to be used instead of Faradism either for the ocular muscles, or for resuscitation of the heart under general anæsthesia, all that is necessary being to connect the electrodes to a lamp-plug for insertion in the same way as the eye-heater, the strength of the current being regulated in just the same way by the same shunt.

(*December 11th*, 1902.)

---

4. *A case operated on for conical cornea.*

By A. Stanford Morton.

Mrs. W— was first seen at the age of 32 years in May, 1880, complaining of failure of sight for the previous ten years. The corneæ were found to be very conical, and the V. was R. J. 1 at 2 inches, not $\frac{6}{60}$; L. J. 2 at 2 inches, not $\frac{6}{60}$. Both were improved by − 5 D. to $\frac{6}{24}$.

June, 1880.—Elliptical excision of L. apex of cone.

January, 1881.—Elliptical excision of R. apex repeated shortly afterwards.

Digitized by Google

May, 1881.—R. c + 2·5 cyl., $\frac{6}{9}$ partly ; L. + 2 sph. $\frac{6}{6}$.

February, 1901.—R. and L. J. 1 at 12 inches, and with correction $\frac{6}{9}$.

Mr. Morton wished to show how little scar remained after excision of the apex of a conical cornea. The amount of scar was so slight that he had on one or two occasions sent the patient round a class of men to ask them if they noticed anything amiss with the eyes, and she had been passed by the whole of them without noticing any scar. He also asked the patient to come to answer the question he was often asked as to how long the effect of the operation lasted; in this case twenty-two years. In reply to the President, he said he had operated upon twenty-three or twenty-five in that way, and he intended to narrate the cases some time. He had had some adhesions of the iris to the scar. The operation in the present case was by excision of a piece with the Graefe knife.

(*Card specimen. June 11th*, 1903.)

Mr. Adams Frost said it was interesting to hear the experience of others in operating for that condition. At one time he liked operating in the way mentioned by Mr. Morton, but of late years he had employed the cautery, which he believed to be productive of less scarring, and to be more satisfactory in many ways. He cauterised the apex of the cone fairly freely, and completed the operation by just puncturing at the apex. That produced a flatter cornea than by means of the knife.

Mr. Johnson Taylor asked whether Mr. Morton was in the habit of operating upon the area of greatest curvature.

The President (Mr. William Lang) said it would be interesting if some one would collect a number of cases of conical cornea which were improved by glasses without operation. That would be more important than even the results of operative treatment. A great number of such

Digitized by Google

cases could be improved by using very high convex cylinders. It was an observation made, he believed, by Landolt, but he (the President) learnt it from Mr. John Couper many years ago. The first case of the kind he had seen was one of Mr. Couper's private patients, in which the vision was improved from less than $\frac{6}{60}$ (with 15 D. convex cylinder) to $\frac{6}{9}$, and the patient got about quite comfortably. Only two weeks ago he saw a man whose vision was improved from less than $\frac{6}{60}$ to $\frac{6}{12}$ with 8 D. cylinder with the axis horizontal. Such lenses were the reverse of what one would expect to be required in such cases, and the results obtained were often very satisfactory.

Mr. H. E. JULER congratulated Mr. Morton on the result in the present case, which was exceedingly good. He had done a good many such cases, although he was not prepared with exact figures. He used to make the incision horizontally, and then complete it with a pair of scissors slightly curved, seizing the lower flap with a fine pair of iris forceps; but he had not achieved such results as $\frac{6}{6}$ in one eye and $\frac{6}{9}$ in the other. His results were fairly good in some cases, but in others quite the contrary. When the cases did not succeed the wound would not unite, and the iris became troublesome in the wound. He was almost afraid of operating upon a conical cornea. The cornea was very unhealthy in such cases, the *substantia propria* was very thin, and often the wound would not heal at all. He preferred the cautery because he could go by degrees, and could see what he was doing. He thought it was better to make a fine puncture at the finish through the centre of the cone, either with the cautery or with a knife.

Mr. MORTON, in reply, said he did not like anything in the nature of "show" cases, and he did not bring the patient up as a wonderful specimen of recovery, but because many years (twenty-two) had elapsed since the operation was done. He hoped shortly to publish the whole of his cases, good and bad, some with results quite

Digitized by Google

as good as in the present case. He had found the testing of such patients with glasses very unsatisfactory, and had given up testing which was the greater or lesser meridian of curvature. But every one of his cases was carefully tested with glasses, and the results would be given in the paper he would publish. The present woman's vision was increased from $\frac{6}{60}$ to $\frac{6}{24}$, but it did not improve her J. vision, so it would not have been very much use to her to have glasses. He had only seen one case in which glasses did any permanent good, and that was one of Mr. Couper's cases. She came to the Great Northern Hospital some years ago, and he thought it was a 9 cylinder, concave. With that she got very good vision. She was wearing $\frac{6}{9}$ he thought. He had not operated upon many such cases by means of the cautery. He was led to excise the apex in the present case by having read notes by Mr. Higgens, in the *British Medical Journal*, of some cases which were very satisfactory. Recently he had a case in which the cone was hardly steep enough to transfix, and yet in which the vision was very bad, and as that cone was to the outer side of the cornea, and therefore where the scar would not interfere with vision so much, he risked the cautery; but no case had given him so much anxiety as that did. He did it in the approved "target" fashion, with zones wide and narrow, and finally a central point, and made no visible puncture. He thought the aqueous was escaping and stopped the cautery, and although the aqueous did not go on escaping there was an anterior chamber when he tied it up. But three days afterwards when he saw it there was no anterior chamber, the cornea was infiltrated, and the pupil contracted up to the scar, and for three weeks there was no suspicion of an anterior chamber. Ultimately the case did very well, and the vision came out at $\frac{6}{9}$ or $\frac{6}{6}$, J. 1. One other he did more recently still, which he had seen with Sir Anderson Critchett. In that he made the usual concentric zones, but did not complete the circle. A horseshoe-shaped scar was thus obtained. The eye improved considerably, with vision $\frac{6}{36}$ and J. 1.

Digitized by Google

There was no loss of aqueous, and the vision went back to nearly what it was before. He repeated the operation, and punctured intentionally. The whole of the aqueous was lost, and her vision when last tested was $\frac{6}{18}$ and J. 1. He believed it was important to puncture the anterior chamber, for if that were not done a sufficiently good result was not obtained.

Note.—The foregoing discussion took place on May 7th, 1903, but Mr. Morton's patient was not actually presented until June 11th, 1903.—EDITOR.

Digitized by Google

XV. MISCELLANEOUS.

1*a*. *The innervation of the orbicularis palpebrarum muscle.*

By N. Bishop Harman, M.B.

(With Figs. 16 to 22 in text.)

During recent years there has sprung up an idea that the M. orbicularis palpebrarum is innervated by the nucleus oculo-motorius, and by an iteration and reiteration of this suggestion there is current a very general belief that the idea is a true one. In this paper I wish to state the evidence which has been put forward in support of this suggestion, and also to bring forward a mass of evidence, apparently previously overlooked, which to my manner of thinking, makes the innervation of a portion of the facial musculature by the nucleus oculo-motorius in the highest degree improbable.

Mendel (1) is in the main responsible for the "new" innervation of the M. orbicularis palpebrarum. Seeking an explanation for several curious cases of bulbar paralysis, wherein the orbicularis palpebrarum escaped paralysis, while the other muscles innervated by the N. facialis were paralysed; he followed the procedure of Gudden, who, by extirpating organs in very young animals, had been able to demonstrate, by the lack of growth in the nervous connections of the lost organs, the paths of their normal nervous impulses.

Mendel removed the M. orbicularis palpebrarum et frontalis from young rabbits and guinea-pigs, stitched the eyelids together, and allowed the animals to live for from

Digitized by Google

six to ten months. On examining the brains of the animals he described the following conditions :—Nucleus of sixth and of seventh unchanged. Facial trunk on side of operation thinner than the other. A reduction in the number of ganglion cells in the nucleus III on the side of the operation, as compared with the other. On these grounds he concluded that for rabbits and guinea-pigs the orbito-facial musculature has its nuclear origin in the hinder part of the centre of the oculo-motorius, which probably also innervates the M. levator palpebræ superioris.

Mendel's hypothesis stands thus :—"the frontalis and orbicularis palpebrarum muscle, although peripherally supplied by the facial nerve, are "eye muscles," and form the oculo-facial group whose central innervation is the oculo-motor nucleus."

The deductions from these observations are held to explain many of the difficult features of cases of bulbar paralysis, and some of these cases, in turn, are held to lend strong support to the idea of the third nucleus innervation, particularly the case which was worked out so admirably by Drs. Tooth and Turner (2).

In their case of bulbar paralysis, there was just before death :—Fifth motor paresis almost amounting to paralysis of the masticatory muscles; lower facial muscles completely paralysed; upper group in a tonic state of overaction. Their findings on examination of the brain were :—the seventh nucleus shows very few grey cells, and these are abnormally rounded, atrophied, or granular. The individual fibres of the seventh root in its course through the medulla seem to be quite natural, that is, none are seen in the process of degeneration, but the bundle, as a whole, is decidedly smaller than natural. On the other hand, the compact little bundle of transversely cut medullated fibres, the ascending loop of the seventh, which is so conspicuous above the posterior longitudinal bundles, is here invisible by Weigert-Pal staining. On examining it with the higher power, we find that normal

Digitized by Google

nerve-fibres are completely absent from it, and that it consists of loose meshwork of neuroglia and nuclei. In their conclusions these workers suggest a triple division of the facial musculature based upon the new and presumptive nerve supply :—

1. Oculo-facial group of frontalis, orbicularis palpebrarum, and corrugator supercilii of the third nucleus.

2. Middle group of elevators and depressors of the angles of the mouth, zygomatici, risorius, and buccinator of the proper facial nucleus.

3. Oro-facial group of the orbicularis oris of the twelfth nucleus.

Other cases have been noted which have relation to the question. Two were fairly recently shown before this Society, one by Dr. C. E. Beevor (3), another by Dr. James Taylor (4). Other cases have been published by Dr. Hughlings Jackson (5).

The general relation of the cranial nuclei in regard to this matter has been most exactly summed up by Sir Wm. Gowers (6), and lest the matter should be deemed so far proven as to admit of no further discussion, I would like to quote his concluding paragraph.

After discussing the proposed connection between the twelfth nucleus and the muscles of the mouth, he writes : —" Similarly it has been suggested that the fibres in the facial supplying the orbicularis palpebrarum, frontalis, and corrugator supercilii are derived from the nucleus of the third nervé, and reach the facial by way of the posterior longitudinal bundles. But for evidence of these hypotheses we have still to wait."

The matter has at present only been attacked by the neurologists from the central nuclear and fibrillar region—a region notoriously difficult, involved, and treacherous to even the least dogmatic exponent. There is, however, another road of approach to the subject, namely, that of morphology.

When an aberrant muscle is noted in the dissecting room the most important search is that for its nerve supply ;

Digitized by Google

it is the best clue to the primary source of origin of the muscle. Conversely, if you are able accurately to follow back the migration of a muscle, and trace it to its original source of origin, you will find the primitive muscle supplied by a nerve common to the metamere or body-segment in which the muscle arose; and that the muscle through all its migrations has continued to be supplied by that same nerve, however entangled the path of travel of the axons

Fig. 16.

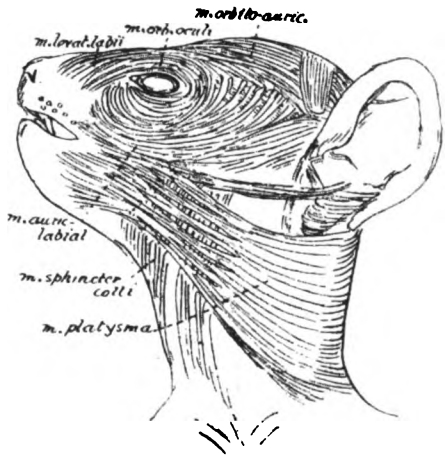

(*After Ruge.*)

may be, their source will remain the same. In short, there is only one thing stable about a muscle, neither "origin," "insertion," nor function, but its nerve supply.

The general arrangement of the facial musculature is familiar to all. I would recall your attention to the chief points. The muscles are disposed in two planes, superficial and deep. No one muscle, in these planes, is independent of its fellow, each muscle is to a greater or less extent continuous with its neighbours, *e. g.*, the orbicularis palpebrarum is continuous with the zygomatici, the zygomatici with the risorius, the risorius with the platysma, and so on. In fact, the individualisation of these muscles is an effect of dissection rather than a natural distinction.

Digitized by Google

The facial musculature of man appears, by contrast, to be distinctly and sharply individualised when it is compared with that of lower primates, *e. g.*, the lemurs (Fig. 16). Here the same two muscle-sheets are found, a superficial and deep, commonly known as the platysma and sphincter colli layers. In these layers the fibres are disposed in relation to the openings of eye, nose, and mouth, in a manner like to that found in man, but there is this distinction: the differentiating action of the vigorous facial movements of man has no place in the lemur, and its musculature

FIG. 17.

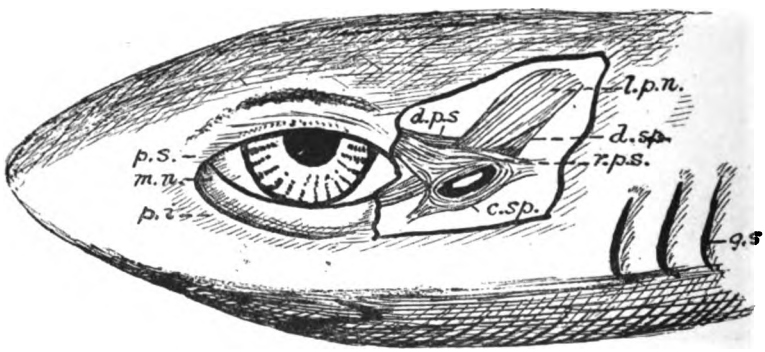

The skin around the spiracle has been removed to show musculature.
p.s. Superior palpebral fold. *p.i.* Inferior do. *m.n.* Membrana nictitans. *g.s.* Gill slit. *d.p.s.* M. depressor palp. sup. *r.p.s.* M. retractor palp. sup. *l.p.n.* Levator palp. nictitans. *d.sp.* Dilator spiraculi. *c.sp.* Constrictor spiraculi.

remains smooth and continuous; no strong breaks have separated the fibres to form more or less distinct muscles. It appears, therefore, that morphologically the facial musculature is a unity, and is not susceptible of a fundamental grouping into orbito-facial, middle, and oral groups as suggested by Drs. Tooth and Turner.

My next aim will be to show you the original ancestry of this musculature, and, to do this, we must revert to our old friend of biology days, the shark. Our laboratory companion *Scyllium canicula*, the "spotted dog-fish," would do, but since my investigation was made on a near

Digitized by Google

relative, *Mustelus lævis*, "smooth hound," I will use this creature.

The eyelids of sharks are provided with a definite musculature (Fig. 17); many have well-developed nictitating membranes, and the musculature is then proportionately accentuated. The muscles are, as in man, blended with the muscles of the spiracle (the homologue of man's external auditory meatus), and are disposed in two layers, a

FIG. 18.

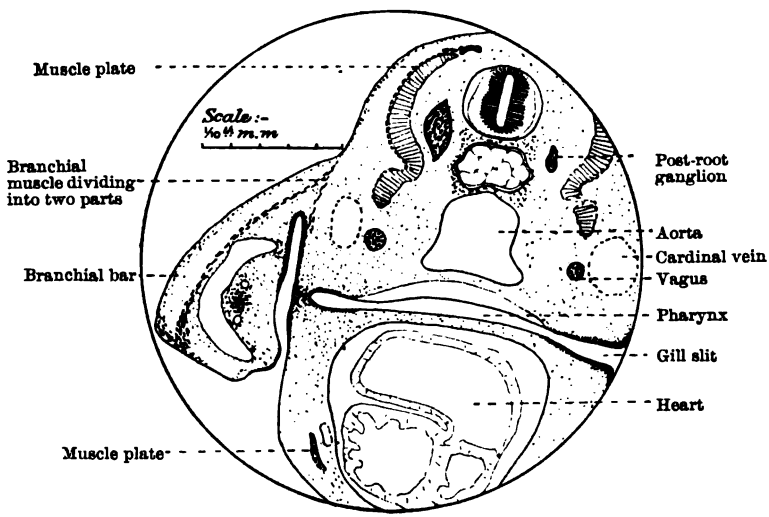

superficial and deep. The former comprises a retractor palpebræ superioris and a constrictor spiraculi, and the latter a levator palpebræ nictitans, a depressor palpebræ superioris, and a dilator spiraculi. These muscles are by no means distinct, they are always more or less blended; the levator palpebræ nictitans becomes most highly differentiated when the membrana nictitans is most specialised. In 1899 I investigated the origin of this musculature. Serial sections were made of embryos of this species in various stages of growth. This fish was chosen because it is viviparous, and also because, in the adult fish, the

Digitized by Google

development of upper and lower lids and membrana nictitans is about equal. The Naples Marine Biological Laboratory supplied me with a beautifully graduated series of embryos.

For a detailed account of this work reference must be made to the original paper (7), but the observations may be summarised as follows. This fish has for breathing outlets six openings in the lateral region behind the eye, first a spiracle and then five gill-slits (the spiracle and three gills

Fig. 19.

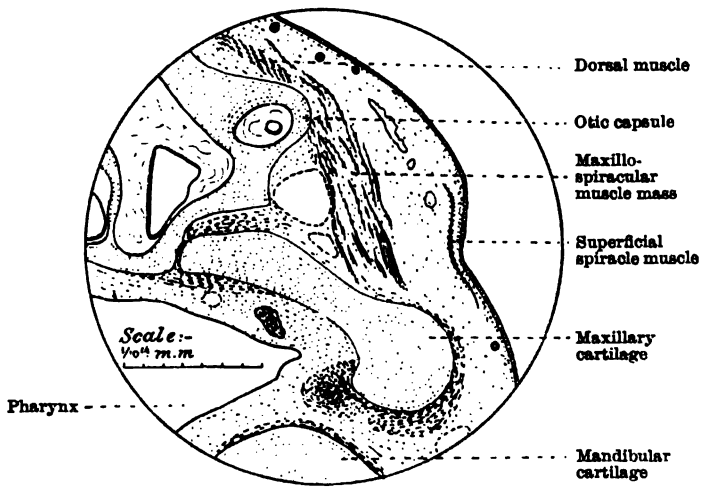

are seen in Fig. 17). A section through an ordinary gill-slit (Fig. 18) shows two sets of muscles to the gill, a superficial and deep. The section through the highest gill (Fig. 19) shows, besides these, an additional, more superficial, or skin mass. In the region of the spiracle (Fig. 20) the superficial gill-muscle separates from the deep gill-muscle (which becomes the mass of muscle attached to the maxillary cartilage), and blends with the third mass, the more superficial or skin mass, to form a single mass of considerable size which is attached to the roof of the spiracle. A part of this mass remains closely applied to the skin

Digitized by Google

after the spiracle has been passed (Fig. 21), when it becomes elongated, and extends forwards and somewhat ventrally.

FIG. 20.

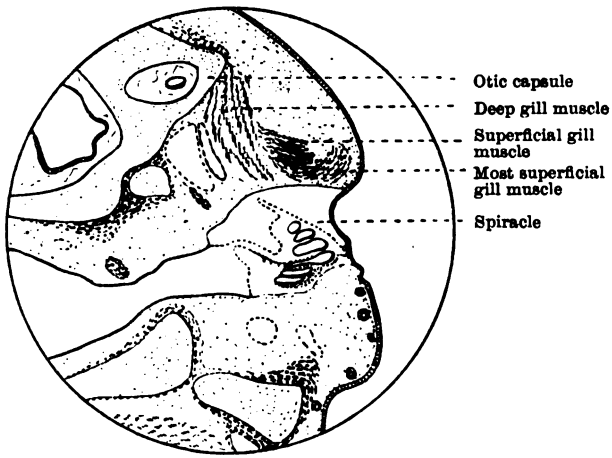

Later it separates into two portions (Fig. 22), a large ventral and a smaller dorsal portion, which are lost in the skin

FIG. 21.

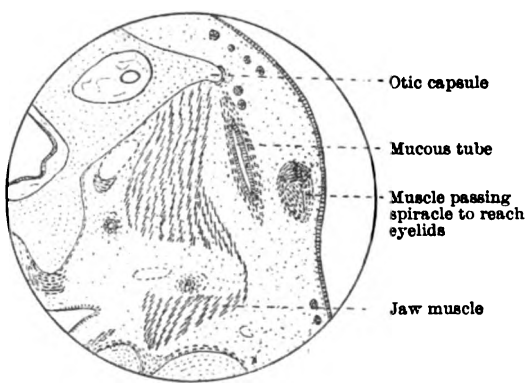

fold covering the posterior angle of the orbital cavity at two spots, from which, a few sections further forward,

Digitized by Google

there arise the upper and lower lid-folds. I concluded "that the musculature of the eyelids of Mustelus is derived from a musculature primarily belonging to the spiracle." There is also to be kept in mind the observation that the musculature of the maxillary cartilage is the deep part of this gill or spiracular muscle-set.

Now comes the question of the nerve supply of this primitive orbito-spiracular musculature. Previous to my dissection of the adult fishes at the Plymouth Laboratory in 1898, I had read the statement that the muscles of the M. nictitans were supplied by the N. abducens (Huxley,

FIG. 22.

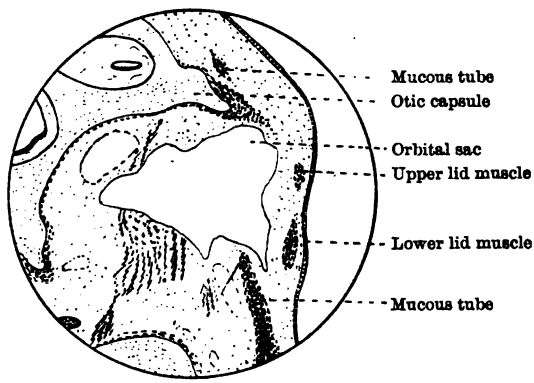

8, and Stannius, 9). On dissecting out the connections in Mustelus I found it was not so, the N. nictitans was traced into the maxillo-mandibular division of the N. trigeminus—an observation simultaneously and independently arrived at by Dr. Ridewood (10) of the British Museum (Nat. Hist.). The error of supposing the sixth to supply this musculature arose doubtless from the peculiar position of the sixth in these fishes. It escapes from the skull by the same foramen as the largest part of the fifth, and immediately enters the substance of the M. rectus externus, so that it does not appear exposed within the orbital cavity. The rectus must be opened out before the nerve can be seen.

Digitized by Google

Failure to note this would lead one to suppose that the N. nictitans was the sixth nerve.

In the embryos I was able to trace out the connection of the N. nictitans more fully, along the trunk of the fifth, alongside the nerve supplying the M. levator maxillæ superioris, past the Gasserian ganglion to the medulla, closely conjoined with the ventral root of the fifth, and in contiguity with the origin of the N. facialis.

In these fish the fifth and seventh nerves are so closely connected that they are commonly known as the "facial complex." Stannius (9A) writes of Plagiostomes, "the N. trigeminus and facialis arise conjointly from three roots, the most anterior of which arises from the ventral surface of the medulla by two short roots, which unite shortly after leaving the brain. This root is in Raja the motor supply of the muscles by which the respiratory movements of the anterior wall of the spiracle are effected, and also of certain other muscles in connection with the jaws." Similar observations have been made by other workers on allied fishes.

There is no doubt, then, that this orbito-spiracular musculature is from its earliest, most primitive form, innervated by the facial complex, by nuclei which are ventral in position in the medulla. This orbito-spiracular musculature is the primitive ancestor of the complicated facial musculature of man; macroscopically, this is in man still supplied by part of the original facial complex nerve.

It may be questioned by some whether observations made on lower animals are to be taken as unreservedly applicable to man. To this the answer is positive for two reasons: 1. On general grounds: embryology owes its existence to the investigations of lower organisms, Balfour's work on the dog-fish made it; later work on human embryos has confirmed the truth of these observations for man also, there is only a difference where the adult forms show some marked specialisation, as in the septation of the mammalian heart. 2. In particular: that the observations in fish for the present case of the facial muscles hold good

Digitized by Google

for man also there is strong evidence, in the occurrence of those curious cases of associated "jaw-winking" movements, the explanation of which is appended to this paper.

Now, is it possible that the primary source of the axones found in the nerve-supply of these muscles should have been shifted from the facial complex nuclei to the oculo-motor nucleus?

To show the high degree of improbability, almost impossibility, of such a shifting, I must refer you to the morphological researches into cranial and spinal nuclei by Dr. Gaskell (11). In 1886 he demonstrated that there were different orders of nuclei in the cerebro-spinal axis, distinct both in the relative position borne by the nuclei to the neural canal, and in their function. In the cord they are—1. Ventro-median nuclei of large cells giving rise to somatic efferent nerves. 2. Lateral nuclei of smaller cells giving rise to visceral or splanchnic efferent nerves (gangliated and non-gangliated). 3. Dorsal connections of afferent nerves.

On account of the opening and lateral "splaying-out" of the neural canal in the medulla these three orders become—1. Dorsal nuclei of somatic efferent nerves; 2. Intermedio-lateral nuclei of visceral or splanchnic efferent nerves; 2. Lateral connections of afferent nerves. Since the neural canal in the mid-brain is a closed tube like that in the cord, the nuclei retain their relative position as in the cord.

Now the nuclei of the third, fourth, sixth, twelfth cranial, and ventral cells of the anterior horn nuclei of the cord are of the first or somatic order; they are large-celled nuclei. The nuclei of the fifth motor, seventh N. ambiguous, part of the N. accessorius, and part of the eleventh are lateral in position, give rise to splanchnic non-gangliated efferent nerve-fibres belonging to the second order; they are smaller-celled nuclei. The fifth sensory, eighth, tenth sensory, and the posterior spinal root connections are of the third order.

Digitized by Google

This classification points out the differences in position and character presented by the oculo-motor nucleus and the facial complex nuclei. They are found to be on quite different planes—they belong to different orders of nuclei. The suggested transference of the innervation of the orbito-facial musculature means, not a mere shifting of the axones of a motor nerve from one somatic nucleus to another a few metameres higher up, but the transference of splanchnic fibres supplying a musculature of splanchnic (gill) origin to a somatic nucleus. The thing is not only revolutionary, but is actually subversive of all morphological ideas.

Further, there is an objection to the proposed transference which has apparently not been thought of. The "convenience" of a similar innervation for the M. levator palpebræ superioris and the M. orbicularis palpebrarum has been much considered,. to the neglect of the greater consideration of the *importance* of the similar innervation for the conjunctiva, and for the guard of the conjunctiva, the orbicularis muscle. In the remains of the primitive connection of the N. trigeminus and facialis as the facial complex we have this: the connection has been recognised in the human brain (Edinger, 13, p. 392), whilst the persistence of the connection of the motor portions of fifth with seventh is shown in the "jaw-winking" movements discussed later.

The co-ordination of the intra-orbital and extra-orbital musculature is amply provided for by the posterior longitudinal bundle, a long band of short linking fibres found to extend from the subthalamic reticulum even to the extremes of the cord as the anterior ground-bundle. More than this is not to be expected, for the whole determination of the musculature of the eye is "fortuitous;" the eye as a primitive sense-organ had no musculature. With the advancement of the organism there has arisen an imperative demand for a mobile eye, and the eye has boldly adapted the musculature of the surrounding primitive head-segments for its purpose; hence the odd conjunction

Digitized by Google

of metameres represented by the third, fourth, and sixth nuclei. With this mobility, and the growing necessity for a due protection of the sense-organ, the eye has similarly filched the musculature of its neighbour, the spiracle. To such an extent has this robbery gone in some sharks developing large nictitating membranes, that the spiracle from inanition has become effete and closed completely.

I would note in passing the case of the whole facial musculature stands on exactly the same footing. The idea of the twelfth nucleus supplying the "orbicularis oris" is just as incongruous. There is no such muscular entity as an orbicularis oris. The "sphincter" of the mouth is but the interwoven endings of the surrounding muscles, dep. ang. oris, zygomatici, lev. lab. sup., dep. lab. inf., lev. ang. oris, and buccinator (Macalister, 12, p. 537). These muscles are extensions of the same sheet as the orbito-spiracular group which sprang into existence a splanchnic musculature with a splanchnic innervation. How, then, is their innervation to be transferred to the somatic hypoglossal nucleus?

I have given you the evidence for the proper facial innervation of the facial musculature. I do not know that it rests with me to account for the considerations upon which Mendel based his hypothesis, and those which Tooth and Turner have brought to its support.

This I will venture to say. The operations which Mendel performed on young animals were not free from objection, for by his procedure he could not fail to produce interference with the proper musculature of the motor-oculi nucleus. After the ablation of the orbicularis palpebrarum and frontalis, he stitched the lids together, and so interfered with the action of one at least of the third nerve muscles, the levator palpebræ superioris, the very one into the region of whose nucleus he sought to attach the orbicularis. That alone is sufficient to throw considerable doubt upon the conclusions he based upon the diminution of the number of the cells in the oculo-motor nucleus. As regards the case of Drs. Tooth and Turner,

Digitized by Google

these authors found many healthy nerve-fibres in the outflow of the facial nerve, with much degeneration of the facial nucleus. They therefore thought the healthy fibres might come from the motor-oculi nucleus, as suggested by Mendel. I would remark that the nucleus of the facial is much larger than we commonly suppose; as Edinger (13, p. 391) puts it, "the facial nucleus is a long row of cells arranged in groups; from these arise continually fibres extending dorsally; these are gradually gathered to form a good-sized bundle." It is obviously almost impossible to judge the ratio of healthy nuclei and fibres diffused over a large area to those fibres grouped in a compact bundle. That there is no mystery in the fibres known as the nerve facialis I do not for a moment assert; indeed, the remembrance of the connection of the trigeminal and facial as the facial complex would guard against this, and I would suggest that the mystery of degenerated fibres in the loop of the facial nerve, of which Gowers writes, may be associated with this.

1*b*. *Associated "jaw-winking" movements.*

The following case does not differ essentially from those previously shown.

Woman, æt. 38 years, partial ptosis left upper lid, congenital. On working the jaws, as in chewing, the drooped lid jerks up and down involuntarily. The movement is best demonstrated by diverting the jaw to the right; the external pterygoid is put into action, and the lid jerks up. V., pupils, and intra-ocular muscles, normal.

Comments.—What appears to be the first case of this nature recorded was shown to this Society by Marcus Gunn (14) in 1883; a committee of investigation considered it. In 1895 Sinclair (15) described and collected notes of other cases, giving the literature of the subject, whilst as recently as 1899 E. C. Fischer (16) showed an excellent example of the condition to the Society.

Various have been the explanations of these associated

Digitized by Google

jaw-winking movements. No one of them has recognised that what at first sight appears to be a "freak" is really not so, but a revival of an old-time and long-accustomed associated movement.

I have shown that the facial musculature is the old spiracular musculature. In tracing the development of this we noted that the musculature of this gill was two-fold, superficial and deep; the superficial was for the movement of the mouth of the spiracle, the deep for the movement of the maxillary cartilage, a plate which in the fish is intermediate between the mandible and the skull. The descendant of this deep musculature in man is in the pterygoids.

Now if you will watch the respiration of a fish you will observe that there is an association between the movements of the jaw and the gills; when the mouth is opened the spiracle dilates. It can be well seen in the gold-fish of aquaria; when the mouth is opened for breathing or when the fish swallows its food, the operculum covering the gills swings open.

It is a revival of this which one sees in these curious cases of jaw-winking movements. In the normal human subject there is a nicely balanced opposition betwixt levator and depressor of the upper lid; this, with the cultivated composure of feature of advanced man, causes the suppression of the old-time association of jaw-muscles and migrated spiracle muscles. In these cases, however, there is a weak, probably ill-developed levator palpebræ, as is shown by the ptosis. During the action of the pterygoid there is an associated relaxation of the orbicularis, and the weak levator palpebræ, taking advantage of the quiescence of its too powerful opponent, lifts the eyelid. The occurrence of this associated movement is what is known as an "atavistic anomaly," and the persistence of the association of the deep and superficial muscles of this branchial arch of the spiracle—now pterygoids and orbicularis muscles respectively—is strong evidence as to the truth of the conclusions in the previous section of this

Digitized by Google

paper regarding the retention of the proper facial innervation of the facial musculature.

Cases of these associated jaw-winking movements are by no means infrequent. Why all cases of congenital partial ptosis do not exhibit it I cannot say, any more than I am able to explain why every man is not able to move his scalp and ears at will.

References.

(1) E. G. Mendel.—*Internat. Med. Congress*, Washington, 1887, vol. v, p. 311.

(2) Tooth and Turner.—*Brain*, 1891, p. 473.

(3) C. E. Beevor.—*Trans. Ophthal. Soc.*, vol. xv, p. 242.

(4) James Taylor.—*Trans. Ophthal. Soc.*, vol. xviii, p. 381.

(5) Hughlings Jackson.—"Neurological Fragments," *Lancet*, July 15th, 1893.

(6) Gowers.—*Diseases of the Nervous System*, 2nd edit., vol. ii.

(7) Harman.—*Journal of Anat. and Physiol.*, vol. xxxiv, p. 1.

(8) Huxley.—*Anatomy of Vertebrate Animals*, 1871, p. 67.

(9) Stannius.—*Handbuch der Zootomie*, 1854, vol. i, Die Fische, p. 163.

(9A) Ibidem.—*Das Peripherische Nervensystem der Fische*, Rostock, 1849, p. 30.

(10) Ridewood.—*Journal of Anat. and Physiol.*, vol. xxxiii.

(11) Gaskell.—*Journal of Physiol.*, 1886, vol. vii, p. 1.

(12) Macalister.—*Text-book of Anatomy*.

(13) Edinger.—*The Anatomy of the Central Nervous System of Man and Vertebrates*, trans. from 5th ed. by Hall, 1899.

Digitized by Google

(14) MARCUS GUNN.—*Trans. Ophthal. Soc.*, vol. iii, p. 283.

(15) SINCLAIR.—*Ophthal. Review*, vol. xiv, p. 307.

(16) E. C. FISCHER.—*Trans. Ophthal. Soc.*, vol. xix, p. 5.

(*June 11th*, 1903.)

Dr. ALDREN TURNER said he would like to make a few remarks on the paper, as his name had been mentioned in it. Many years had elapsed since the case referred to by Mr. Harman was examined clinically and microscopically by Dr. Tooth and himself, so that he found his memory of the exact details somewhat deficient, and for that reason he was hardly prepared to assume an antagonistic attitude without having the details at hand. But the general principle was quite clear to his mind, namely, that it was supposed, both from Mendel's experiments and from pathological observations on certainly one case, and from the clinical observations of several cases, that the orbicularis palpebrarum, and perhaps also the frontalis muscle, were more closely associated with the external ocular muscles in their nuclear innervation than with the facial muscles. To assume that nuclear innervation could change from splanchnic to somatic segments, as would occur if this hypothesis were true, was, as Mr. Harman had pointed out, not in accordance with strict biological principles. Mr. Harman's observations that evening were based almost exclusively upon fishes, and although he (Dr. Turner) admitted that the general morphological principle held good throughout the whole vertebrate series, yet he thought some latitude must be allowed when considering the physiological relations of the muscular movements in connection with special organs. It seemed to him that the orbicularis palpebrarum, in its physiological action, was an "eye muscle;" it was there for the definite purpose of protecting the eye. The reflex of the orbicularis palpebrarum was obtained from the cornea and the conjunctiva, and that action therefore

Digitized by Google

seemed to him to be more in association with ocular than with facial movements; it was, in fact, more particularly an ocular muscle, and less distinctly a muscle of expression.

---

2. *A case of acromegaly with bitemporal hemiopia, showing the changes that have taken place in the visual fields after four months' treatment with pituitary body tabloids.*

By Arnold Lawson.

The patient, who is aged 30 years, exhibits all the physical signs characteristic of acromegaly.

On August 14th, 1902, the state of vision was as follows:—R. V.: letters of Jaeger No. 16 with difficulty. Field hemianopic. L. V.: hand-movements. No visual field could be mapped out for the left eye. Very little ophthalmoscopic evidence of disease. Optic discs are rather grey, and that is all. Pituitary feeding began, commencing with one tabloid (2 grs.) three times daily, to be increased by a tabloid three times a day each week.

On November 5th, 1902, R. V.: letters of Jaeger No. 20 with difficulty. Visual field smaller. L. V. $\frac{2}{60}$. Letters of Jaeger No. 14. Visual field easily mapped out. Is taking five tabloids three times daily.

On December 5th, 1902, R. V. has been reduced to hand-movements. L. V. = $\frac{6}{60}$, − 1·5 D. = $\frac{6}{36}$ badly. Right visual field is very small, and is mapped out with difficulty. Left visual field has largely increased.

(*Card specimen. December 11th*, 1902.)

Mr. R. W. Doyne had tried, and abandoned, the internal use of pituitary gland in cases of acromegaly.

Digitized by Google

3. *Report of five cases of glaucoma in which adrenalin caused an increase of tension.*

By A. Ferguson MacCallan.

The use of adrenalin in ophthalmic operations is now very general, the advantages of the drug being that the hæmorrhage, on section of conjunctiva and iris, is reduced, and when a local anæsthetic is used, its absorption and resultant action are more complete. This, of course, is well known, but I think it is not well known that in certain cases of glaucoma the tension of the eye is occasionally increased by the use of the drug. In view of its recommendation as a therapeutic agent in glaucoma by Dr. A. Darier, the following cases may be of interest.

Case 1.—Rosa F—, a Jewess, became an in-patient at Moorfields Hospital, under the care of Mr. Gunn on March 7th, 1902 (Reg. No. 346). Eserine had been used freely in the out-patient department for both eyes, which exhibited the signs of acute glaucoma.

When she came under my observation, the tension of the right eye had fallen to normal, but in the left the tension was + 1. The condition of the left eye was as follows:—the conjunctiva was much congested, the cornea was clear (except for three nebulæ), the anterior chamber was shallow, and the pupil was semi-dilated. On ophthalmoscopic examination, it was found that the outlines of the optic disc were obscured above and below by hæmorrhages situated along the course of the vessels, and partially obliterating them. On the temporal side of the disc were several small linear hæmorrhages. There was no definite pathological cupping of the disc. The vision of the eye was equal to finger-counting at 1 foot. The right eye was normal, except for a shallow anterior chamber and some vascular congestion.

Digitized by Google

The following day Mr. Gunn saw the case, and in view of the hæmorrhagic condition of the left retina did not advise immediate operation. He suggested, however, a trial of adrenalin in addition to the eserine.

Adrenalin, together with eserine, was instilled by a nurse into the patient's worse eye twice during the afternoon. At 6 p.m. of the same day it was reported to me that the patient's condition was worse. I went at once to see her in the ward, and found that she was vomiting, and that she had a severe headache. The left eye, into which alone the adrenalin had been instilled, was acutely painful, the pupil was widely dilated, the cornea was steamy, and the tension was + 3. The adrenalin was at once discontinued. Under the influence of hypodermic injections of morphia, the application of leeches to the left temple, and eserine, the tension was reduced to about normal by 10 p.m.

On March 15th, and again on March 19th, there were rises of tension in the left eye, which were subdued in the same way. These occurred although eserine was continued, and although adrenalin was not again used. But in these instances the tension did not reach so high a pitch, nor were there any general constitutional disturbances, as occurred during the adrenalin increase of tension. During this time the condition of the right eye did not alter. No operation was performed on this patient, but she was directed to remain under observation as an out-patient. This, however, she did not do, and I have been unable to get into communication with her.

Case 2.—Francis C— was admitted to Moorfields under Mr. Silcock on April 18th, 1902 (Reg. No. 569). Owing to the patient's extreme deafness, it was impossible to get any trustworthy history from him. He was suffering from acute glaucoma. The condition of the left eye was as follows:—there was much conjunctival injection, the cornea was slightly steamy, and the pupil was dilated. No view of the fundus was obtained owing to the opacity

Digitized by Google

of the media. Vision = finger-counting at 2 feet; T. + 2.

The right eye was in the following condition :—pupil semi-dilated, disc hyperæmic, not excavated; T. + 1. Active miotic treatment was at once commenced. In the right eye the pupil contracted, the tension falling to normal. The left eye, however, did not respond so well to eserine, although the pupil did become smaller, and the tension fell to + 1.

The patient was prepared for operation, and from 6.30 p.m. to 7.15 p.m. adrenalin (as well as a solution of eserine and cocain) was instilled several times into the left eye, with a view to reduce the congestion and permit of the operation being performed under a local anæsthetic.

At 7.15 p.m. it was found that the tension had increased to + 2, while the cornea had become slightly steamy, and the pupil had dilated.

A successful iridectomy leading to permanent diminution of tension was performed by Mr. Silcock on the left eye under a general anæsthetic.

Case 3.—Matilda P—, an out-patient under Mr. P. Flemming, was admitted to the hospital suffering from acute glaucoma on May 9th, 1902 (Reg. No. 686).

The patient was treated for spasmodic entropion, and was ordered eserine for both eyes. On May 11th the condition was as follows:—R.: congestion of the conjunctiva, pupil semi-dilated and oval (5 mm. vertically by 4·5 mm. horizontally, as measured by callipers), some lenticular opacity; ophthalmoscopically there was a dull red reflex only. V. = finger-counting at 6 inches. Field much contracted. T. + 1. L.: tension normal, and pupil pin-point.

Immediately after noting the above facts, I instilled two drops of adrenalin into the right eye. After the lapse of seven minutes, there was increased tenderness of the globe on palpation, and the tension had risen to + 2. The con-

Digitized by Google

junctiva was now paler, and the pupil had increased in size by half a millimètre in each meridian.

This condition persisted for half an hour. I then began to instil eserine, and pushed the drug vigorously. This reduced the tension very nearly to normal, while the pupil contracted to 4 mm. in each meridian.

On May 13th, when iridectomy was successfully performed by Mr. Flemming, under the influence of adrenalin and cocain, it is noteworthy that no increase of the existing degree of tension could be detected.

Case 4.—Ernest J—, æt. 28 years, came under Mr. Morton's observation at Moorfields on May 7th, 1902. He complained of pain in the eyes, with neuralgic headaches and failing vision. In order to carry out a complete investigation of the case, a drop of mydriatic solution (homatropine and cocain) was instilled into each eye. This caused a slight rise of tension in both eyes, but especially in the right. However, the pupils became contracted, and the tension was reduced to normal by two instillations of eserine ¼ per cent. He was ordered to use, twice a day, a solution of eserine $\frac{1}{16}$ per cent. while he attended as an out-patient. He was seen again on May 30th, when there was a good deal of conjunctival injection in both eyes. It was noted that the tension in each eye was somewhat above normal. A drop of adrenalin was then placed in each conjunctival sac, with the result that the injection disappeared, but was replaced by signs of glaucoma; that is to say, the corneæ became steamy, the pupils dilated, and the tension rose to + 2 in each eye.

I saw the patient for the first time while in this condition, and he was admitted as an in-patient (Reg. No. 783). By the use of eserine, the tension was diminished to + 1 in the right eye, and to a degree which was only slightly above normal in the left.

For about a week the tension was unaltered in spite of continuous miotic treatment. The patient informed me that his vision was always better after his principal meal

Digitized by Google

about midday; that is to say, during the time that his splanchnic area was engorged with blood, with resulting depletion of the peripheral circulation, and hence lowered blood-pressure, he had better vision. Probably, therefore, the eyeball tension was more nearly normal during his periods of lowered blood-pressure. Experimentally J. H. Parsons found that the intra-ocular tension bore a close relationship to the general blood-pressure, as he stated in his Arris and Gale Lectures.

On June 10th I performed paracentesis of the right eye, but the relief of tension obtained was merely temporary, as two hours after the operation it had risen to + 2.

On June 13th Mr. Morton performed an iridectomy on the right eye under a general anæsthetic successfully. Four months after this, the tension was normal, and vision = $\frac{6}{9}$ in each eye. Ophthalmoscopically a retinal hæmorrhage in the process of absorption was seen just above the right optic disc.

Case 5.—Kate P—, æt. 55 years, came to Moorfields on June 17th, and was seen by Mr. C. D. Marshall. The right eye was in a condition of acute glaucoma, while the left eye also exhibited some increase of tension as well as cupping of the disc. Under the influence of eserine, the right cornea, previously steamy, became clear, the pupil contracted somewhat, but the tension remained about + 2. (Reg. No. 877.)

The patient was taken to the theatre for operation, and while on the table adrenalin was instilled into the right eye. This resulted in steaminess of the cornea, wide dilatation of the pupil, and increase of the tension to + 3. Mr. Marshall successfully performed the operation of iridectomy under a general anæsthetic. In this case there was a good deal of reactionary hæmorrhage, which did not clear up for about ten days. It was probably the result of the adrenalin.

Digitized by Google

Remarks.—This increase of tension of glaucomatous eyes—as the result of the instillation of adrenalin,—as must be well known, is not an invariable phenomenon. I have notes of its occurrence only in the five cases which I have reported, while the drug was used in a large number of cases while I was house-surgeon at Moorfields. It will be observed that all the cases I have reported have been instances of acute or subacute glaucoma, and in two of them there were retinal hæmorrhages.

In several cases of chronic glaucoma, I have carefully examined the fundus ophthalmoscopically, both before and after using the drug, without being able to detect any change. Nor in these cases did I observe any change in the tension of the eyeball. It has not been my experience that adrenalin has any influence on the size of the normal pupil when used alone, as determined by measurements before and after its instillation. This, I think, is the general opinion, although Königstein obtained dilatation, and Polasky contraction, of the pupil with supra-renal extract.

Darier states that adrenalin produces dilatation of the pupil, but nevertheless he looks upon it as a sheet-anchor in the treatment of glaucoma. He explains this on the theory that the drug diminishes intra-ocular secretion as the result of its local action. Diminution in the intra-ocular secretion may conceivably occur if the drug is freely used and is absorbed into the eye, but I can imagine that a weak adrenalin solution, used in conjunction with eserine, might cause a larger reduction in tension in a glaucomatous eye than a solution of eserine alone. For by the vascular constriction produced by the adrenalin the way is paved for an increased absorption of the miotic, since the blood-vessels will not carry away so much eserine when they are contracted as when they are dilated. But adrenalin was used in three of the cases which I have reported, and in most of the cases of glaucoma in which the drug was prescribed when I was house-surgeon at Moorfields, merely as a preliminary to operation. Its object was to render operation under a local

Digitized by Google

anæsthetic feasible, if possible, and to prevent hæmorrhage during the operation. Hence it was used in the strength of 1 : 1000, and it has proved to be of considerable service on many occasions, the cases which I have reported being quite exceptional in my experience.

To what, then, can be attributed the increased tension which I have observed after the use of adrenalin in glaucomatous eyes? I do not know, although I can suggest a theory. In acute glaucoma there is dilatation of the anterior ciliary veins, which carry away from the interior of the eye a greater volume of blood than they do under normal conditions. When these veins are constricted by the use of adrenalin there will be a damming back of blood in the interior of the eye. This suggested increase in the volume of the intra-ocular blood may account for the rise of tension which I have observed.

Parsons has found that a rise of intra-ocular tension resulted in animals when adrenalin was injected intravenously into the circulation. This is dependent on the increased blood-pressure thereby produced. A very small quantity of the drug is sufficient to produce an effect on blood-pressure. Takamine calculated that less than one thousandth of a grain of adrenalin would be sufficient to cause a distinct rise of pressure in an adult man.

Have we then to do with a general increase of blood-pressure (due to absorption of the drug), resulting in an increased intra-ocular tension, in the cases which I have reported? If so, the increased tension ought to have manifested itself in both eyes equally when adrenalin became absorbed into the circulation after having been dropped into one eye. However, I have never observed any increase in the tension of the untouched eye, nor any alteration in the translucency of the cornea, nor any dilatation of the pupil.

In conclusion, I desire to thank the members of the staff of Moorfields Hospital who permitted me to publish these cases.

(*May 8th*, 1903.)

Digitized by Google

Mr. N. Bishop Harman said that at the discussion on episcleritis at the meeting of the British Medical Association at Manchester in 1902 he had reported briefly a case which suggested that the use of adrenalin was not without danger, for its use had in this instance been attended with inconvenient diminution of visual acuity and field. The full notes of the case were as follows.—Man, æt. 47 years, a patient for two or three years at Moorfields for left episcleritis. In February, 1902, there was slight atropine irritation; the vision was noted—R. = $\frac{6}{36}$ c̄ − 1·5 D. sph. = $\frac{6}{6}$; L. = $\frac{6}{12}$ c̄ − 0·75 D. sph. = $\frac{6}{6}$. March 1st.—Adrenalin 1 : 5000, gutt. j, t. d. s., was given. 5th.—Patient returned, saying he had stopped the use of the drops after four days, for they caused a biting pain in the eye; the eye was uncomfortable, and he could not see so well with it as before. On examination, R.V. same, field full, T. n.; L.V. = $\frac{6}{36}$, and J. 8 at 9″ *not improved;* field both for red and white diminished by 20°. T. n., fundus n. 15th.—R. same; L.V. = $\frac{6}{24}$ c̄ − 0·75 D. sph. = $\frac{6}{6}$, three letters, field full for white and red. T. n. The phenomena noted here might, he thought, be explained in two ways. (1) The drug was absorbed, and caused constriction of the intra-ocular vessels, diminution of nutrition of the retina, and consequent partial failure of vision. (2) The constriction of the surface vessels by the adrenalin was balanced by an engorgement of the deeper circulation—in the eye,—or a transient attack of glaucoma followed its use. Considering the results of the action of the suprarenal extract in the physiological laboratory, he was inclined to think the former was the true explanation for this case, but the latter suggestion was not unsupported, for it had been noticed on occasion that small doses of the drug produce an initial dilatation of the vessels.

Mr. W. H. Jessop said he had not been satisfied with adrenalin in episcleritis and scleritis. In the cases in which he had trouble he tried it in every way, and the patients said there was great pain some minutes after injection. In one case he found there was a decided increase of tension.

Digitized by Google

He thought the pain might be imaginary, and in order to test that point he put in water next time, but there was no complaint of pain. He then tried cocain without complaint of pain. On again putting in adrenalin, there was the old pain some minutes afterwards. He believed the pain was due to the fact that constriction was followed in a few minutes by great engorgement of the vessels.

Mr. J. H. PARSONS said there was no question that, experimentally, the local effect was diminution in the intra-ocular tension. The second and general effect was to increase the intra-ocular tension. But he did not think it was possible to get any glaucomatous condition arising even from the general absorption, unless there was a predisposition to glaucoma. The explanation of the effect of adrenalin was very difficult, because there were so many factors which had to be taken into account. It had been shown by Schäfer and Moore that adrenalin, or its equivalent, acted on the actual walls of the vessels, and therefore probably either on the nerve-endings or on the actual muscle-fibres. It probably acted on the muscle-fibres of the iris as well, and one would expect that the sphincter would win in that case. But there was an opposite effect on the blood-vessels, which would result in a constriction of these, and therefore a tendency to dilatation of the pupil. The sphincter would be acting against the blood-vessels, and it was very difficult to foretell what would happen. There was the local effect on the vessels, which would be constriction of the arterioles, which was greater than the effect on the veins, and therefore he did not think Mr. MacCallan's theory would "hold water," because, although the blood in the ciliary processes might remain there, and there would be a diminished outflow of blood through the veins, there would also be a diminished inflow through the arteries. He had not tried the effect of adrenalin on excised eyes, but according to Darier there was dilatation of the pupil. If there was dilatation of pupil, he thought that accounted better than anything else for the tendency to rise of tension. The whole matter was theoretical.

Digitized by Google

But experimentally in normal eyes in animals the local effect was diminution of tension due to arterial constriction, and diminished secretion following that, and the general effect on absorption was increase of tension due to the effect on the general blood-vessels of the whole body, the splanchnic area winning the less important areas, the globe included, being areas of passive vascular dilatation. An important point about adrenalin itself was as follows. —He used adrenalin from Parke, Davis, and Co. in some of his experiments. He found afterwards that it was customary to get the adrenalin in solution. That was supposed to be 1 in 1000. He thought it was customary to use that practically undiluted, whereas the ordinary doses which were read of were 1 in 10,000 applied externally. He found that the adrenalin solution varied enormously, as was only reasonable to expect, for Takamine showed that adrenalin solution was an excellent developer for photographs, and when it was oxidised it ceased to have any pressor action. Therefore there was no question that the solid material should be used and the solution made up frequently from that, and then one knew what one was using. But even the solid preparation did not always act physiologically, and there were enormous variations in the effects. He had sometimes put in very large doses of Parke, Davis, and Co.'s adrenalin without getting any appreciable rise of blood-pressure. He doubted whether Takamine had got hold of the true active principle of the supra-renal gland, or possibly Parke, Davis, and Co.'s preparation was not identical with Takamine's original adrenalin.

Mr. Holmes Spicer said that with regard to the greater effect of adrenalin on the arteries than on the veins, he did not think that altogether destroyed Mr. MacCallan's theory, because these glaucomatous subjects were old people whose arteries were notoriously rigid, and therefore in them adrenalin would be more likely to act on the veins than on the arteries.

Mr. Johnson Taylor asked whether the use of adrenalin

Digitized by Google

in conjunction with cocain for cataract caused any risk of choroidal hæmorrhage. If not, there would be a decided gain, in that hæmorrhage from the conjunctival flap would be avoided. But if it increased the intra-ocular tension, that would be an objection.

Mr. MacCallan said, in reply, that with regard to the use of adrenalin, he had never known serious intra-ocular hæmorrhage occur after operations on eyes into the conjunctival sacs of which the drug had been previously instilled. The use of the drug had been adopted very largely in operations during the last eighteen months of his tenancy of the post of house-surgeon at Moorfields Hospital. Occasionally there was some reactionary hæmorrhage into the anterior chamber, as he described in his paper, and as Mr. Sydney Stephenson had mentioned in a foot-note to his recent translation of Darier's *Ocular Therapeutics* (1903).

---

4. *Tumour in region of yellow spot.*

By Walter H. Jessop.

Mrs. S. B—, æt. 63 years; married forty years ago, thirty-three years a widow. Has two children. Husband died of phthisis. Is often subject to coughs. Five years ago told by doctor she was in consumption. Fifteen years ago fell on back of head, and has pain at back of head at times since. Eight months ago knocked right eye against a brass gas-pipe when going upstairs. Eyebrows swollen afterwards and eye painful at time. Lately loss of memory and headache.

Present state.—V.: R. $\frac{6}{60}$; L. $\frac{6}{18}$. Pupils equal, and act normally. Tension normal. R. media clear. Optic disc, surface indistinct and hazy; vessels normal. About two-thirds O.D. from O.D. is an oval swelling covered by

Digitized by Google

the retina, not transparent, about three O.Ds. in length and two and a half O.Ds. in height. The edges are fairly distinct, especially at outer and lower part. Swelling is greyish in colour and in places white and reticulate in appearance. Retinal vessels cross it. Greatest height = 4 D. At one side are two dark-brown pigment patches. In retina, to outer side and near swelling, are several glancing white spots (cholesterin). Above are two or three yellowish-white retinal spots. About three O.Ds. breadth from O.D., along inferior temporal vein, and starting from a fork in the vein, are numerous black retinal pigment spots arranged as a streak. At periphery above and below are a few isolated retinal spots. Fields for white and red are normal at periphery, and also no scotoma at centre for white; for red there is a very small central scotoma. L.: optic disc a little pale, but nothing found in fundus. Refraction H. = 2 D.

(*Card specimen. March 13th*, 1903.)

Mr. Jessop said he wished to ask the opinions of Members of the Society. His own view was that it must be a connective-tissue tumour. The swelling was four dioptres in height, and there were other changes around. Mr. Silcock had a case of gumma, which had been published in the *Transactions*, and in which the eye had been excised.

Mr. G. Hartridge said that he showed a case fourteen years ago, and a second time six years ago, of an apparent growth of the macular region, and had watched the case ever since. It had undergone many changes, but it was not a growth, although it projected into the vitreous about 2½ mm. There had been hæmorrhages on the top of the projection, which suggested its being a neoplasm. He suggested that Mr. Jessop's case should be watched carefully for a considerable time before any operative procedure was undertaken. There was now considerable retinal change, although the patient appeared healthy.

Digitized by Google

The retina and retinal vessels in the other eye showed no change. The urine contained albumen.

Mr. Quarry Silcock said he showed a case like that mentioned by Mr. Jessop about four years ago, and it was published in the *Transactions*, vol. xix. The condition had undergone absolutely no change since first seen at Moorfields Hospital and subsequently exhibited before the Society. In his case the difference of opinion as to its nature and appropriate treatment was extremely marked, some Members counselling immediate excision, while others opposed any active interference. He believed that such growths were composed of cicatricial connective tissue. There was in his case marked disseminated choroiditis, and he thought this was so in Mr. Jessop's case. He punctured his case by plunging a needle through the sclera while observing it with the ophthalmoscope, but no blood came out. It was a very avascular substance.

---

5. *Cerebral degeneration with symmetrical changes in the maculæ in two members of a family.*

By F. E. Batten, M.D.

(With Plate XV, fig. 2.)

R. B—, a girl æt. 7 years, was a healthy child until about twelve months ago. She learnt to talk and walk early, but was never good at her lessons. Twelve months ago she became spiteful at school, had attacks of violent temper, and about that time it was noticed that her sight was failing, and "she looked out of the corners of her eyes to see an object." The child had had no headache, no vomiting, and no fits. Her appetite was good, and she was clean in her habits. The Father and Mother are both alive and well, and are of English origin. There

Digitized by Google

were seven children in the family, and the Mother had had no miscarriages.

Family.—1st, boy, æt. 15, healthy. 2nd, girl, æt. 13, is in Darenth Asylum (see below). 3rd, boy, died of convulsions at 2½. 4th, boy, æt. 9, healthy. 5th, girl, æt. 7, patient. 6th, boy, æt. 5, healthy. 7th, girl, æt. 1½, healthy.

The physical condition of the child was good. She walked well, and was able to find her way about the ward. She was extremely irritable at times, and would shout and scream for hours, but she complained of no headache. She talked well, could count beads, and tell their colour. The knee-jerks were obtained with difficulty, and the plantar reflex tended to give an extensor response.

The vision was extremely defective, but she seemed to see fairly well with the periphery of the field of vision. She could tell all simple colours, and could pick up and point to small objects accurately (probably there was a central scotoma in both eyes).

For the following note on the condition of the eyes I am indebted to Mr. W. T. Lister:—There was no ptosis, all movements of the eyes were good, and there was no squint. There was occasional fine nystagmus. The pupils were equal, reacted poorly to light, and did not maintain their contraction well. The media were clear. The discs were clearly defined, slightly pale, but not markedly atrophic. There was no sign of previous neuritis. There were peppered pigmentary changes all over the retina, the result probably of old retinitis. At each macula (right and left) there was a reddish-black spot, larger and more defined in the left than the right eye (about ⅓ O.D. diameter in size). The shape was irregular and not round, and the margin was not very sharply defined (*cf.* Waren Tay's cases). The region immediately surrounding the dark spot was paler than the rest of the fundus, and more atrophic-looking. The retinal vessels were on the "small side," but not markedly so.

Digitized by Google

The elder sister, now in Darenth Asylum, was a patient at the National Hospital, under the care of Dr. Bastian, in January, 1900, and to him I am indebted for permission to make reference to the case.

S. B—, a girl æt. 10 years. When four years old began to complain of headache, but was never sick. Three months later it was noticed that her sight began to fail, and her mental state deteriorated.

In November, 1899, she had a fit, commencing in the right hand and spreading down the right side, and then becoming generalised. She was unconscious for four hours. The speech was not affected after the fit. The fits have recurred on two occasions since.

The physical condition of the child was good. She talked fairly well, and her memory was good. There was no weakness of either upper or lower extremities, and she walked well. The knee-jerks were active, and the plantar reflex gave a flexor response on both sides.

When looking at anything she turned her head and eyes to one side, and did not look straight at an object. Pupils were large, reacted slightly to light. There was slight nystagmus on lateral deviation.

Mr. Gunn's report on the condition of the fundus was as follows:—The discs are pale, edges fairly distinct, vessels are small, and there is some exudation along them; there is considerable pigmentation in the region of the yellow spot.

The mental condition of the child deteriorated, and she was removed to Darenth Asylum.

Remarks.—The changes found in the maculæ of these two children associated with mental deterioration suggest a resemblance to the condition of fundus described by Waren Tay in infants with progressive cerebral degeneration. The macular changes, however, bear but a superficial resemblance to those described by Waren Tay.

A markedly similar condition as regards the changes at the macula has, however, been described by Dr. Rayner D. Batten in the *Transactions* of the Society, vol. xvii,

Digitized by Google

p. 48, but in his cases there was no mental defect. He reports the cases of two brothers whose sight commenced to fail at the age of fourteen. At the time of examination their ages were fourteen and twenty-one years respectively. The fundus changes were symmetrical and similar in the two brothers, consisting of an aggregation of fine stippled pigment at the macula, with slight pallor of the optic discs. No other evidence of organic disease was detected. There was a definite history of syphilis in the parents, but no evidences of congenital syphilis in the children.

(*December 11th*, 1902.)

Dr. R. D. BATTEN said that in 1897 he reported two cases with changes at the macula of a similar character, occurring in two brothers, the younger of them aged fourteen years, who came to him with the history of the sight having recently failed. It was symmetrical in the two eyes. In his cases there was no mental defect, and the sight failed rapidly and then became stationary. The elder brother's sight rapidly failed at the age of fourteen also, and then became stationary. In both there were some dark pigmentary changes at the macula, symmetrically placed in the two eyes, and slight pallor of discs. The conditions were ophthalmoscopically markedly similar to the case shown. In his own cases there was a definite history of syphilis in the parents.*

The CHAIRMAN (Mr. W. Lang) asked whether the cases were like those which Mr. Waren Tay had called attention to in Jewish children. In Mr. Tay's cases all the patients died.

Dr. F. E. BATTEN said that when he first saw the condition he thought it similar to that described by Mr. Waren Tay. Many Members of the Society had seen the eyes and expressed the opinion that, although they might be a stage of that disease, their appearance did not now resemble that condition.

Mr. W. ADAMS FROST said that in Mr. Waren Tay's cases

* *Ophthal. Soc. Trans.*, vol. xvii, p. 48.

Digitized by Google

the patch on the macula was perfectly circular and of large size—almost as large as the disc. In the present case there was a small, irregular, dark spot.

Mr. E. Treacher Collins said that in the cases of symmetrical changes at the yellow spot shown by Mr. Tay and Mr. Kingdon (of which he cut some sections) the condition seemed to be due to an œdema around the macula, and the central red spot was like the red spot caused by an embolism of the retinal artery. In Dr. Batten's case the changes at the maculæ seemed to be due to actual pigmentation; it was possible to see definite granules of pigment. The darkest part of the patches resolved themselves into a number of fine punctate granules, quite different from the condition in Mr. Tay's case.

---

6. *Two drawings of normal fundi, illuminated by means of a mercury vapour lamp.*

By M. S. Mayou.

(With Plate XVIII, figs. 1 and 2.)

1. The fundus of a girl, æt. 13 years. Complexion fair. Irides light brown. Refraction, mixed astigmatism (see fig. 2).

2. The fundus of an albino rabbit (see fig. 1).

The light is produced by allowing an ordinary constant current to flow through a vacuum tube containing mercury from a platinum to an iron electrode, the resistance in the tube having first been broken down by a spark of high tension. Although the light is extremely brilliant, it produces an "after image" of very short duration. Examined with the spectroscope, it is seen to be rich in blue and violet rays, but there is a complete absence of rays from the red end of the spectrum.

Digitized by Google

Digitized by Google

PLATE XVIII.

Illustrates Mr. M. S. Mayou's communication (p. 390) on the appearance of Normal Fundi Illuminated by means of a Mercury Vapour Lamp.

FIG. 1.—The fundus of an albino rabbit.

FIG. 2.—Fundus of a girl, æt. 13 years, with slight mixed astigmatism.

Digitized by Google

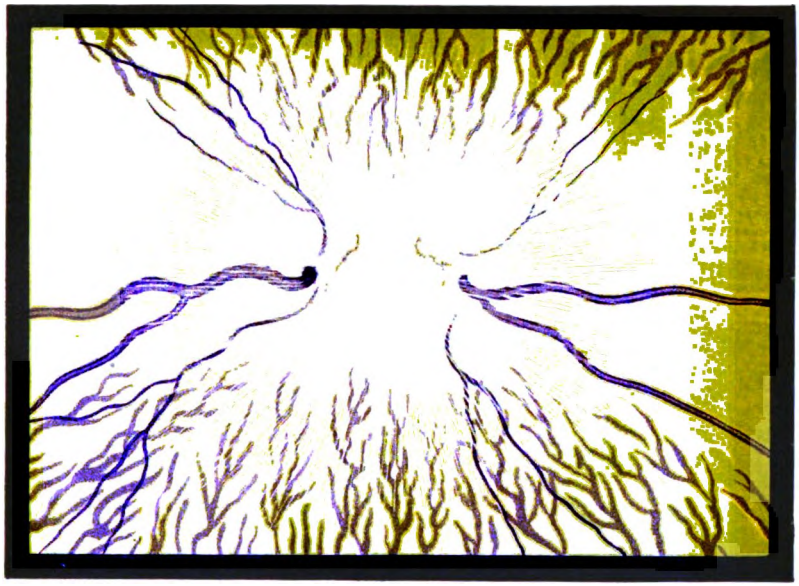

Fig. 1.

M. H. Brooks, del.

Fig. 2.

Bale & Danielsson, Ltd.

Digitized by Google

Digitized by Google

The chief features of fundi examined by this light are—

1. The colouring of the fundus is entirely altered.

2. A retinal reflex is seen all over the fundus, being especially well-marked along the course of the vessels, but somewhat deficient at the macula.

3. The arteries are well defined, and can be traced to their smallest branches.

4. A better perspective of the fundus is gained,—that is to say, of the varying depths of the retina, choroid, and sclera.

A somewhat similar light can be produced, although the definition obtained by it is not so good, by using a Gifford's fluid "F-line" screen in front of an electric arc lamp. (*Card specimen. March 13th*, 1903.)

---

7. *Paralysis of the upward movement of the eyes.*

By Simeon Snell.

Frank T—, æt. 50 years, came to the Sheffield Royal Infirmary as my out-patient on July 25th, 1902.

He was employed by the Tramways Department of the Corporation to look after the car-sheds. He had always been a healthy man. He gave the following history. On July 19th he had been at work all day, and returned home at 5 p.m. After having his tea, he sat in the easy chair and smoked his pipe. Whilst smoking, he fell asleep. He remembered nothing until 4 o'clock the next morning. His wife says she called him three times during the night, and that he replied quite well, but he himself recollects nothing whatever about her having spoken to him. When he awoke at 4 a.m. he felt very giddy, and experienced difficulty in standing. His wife assisted him into the adjoining room. He then went to bed and almost imme-

Digitized by Google

diately fell asleep, and remained so until 8 a.m. When he then awoke, he had severe pain in the forehead, and objects he looked at seemed to be double; there was no sickness. At this time also he was very dizzy, and had to be assisted to walk about. He experienced this giddy feeling more or less for a week, and then it gradually passed away.

At the date of his first visit to me he was still somewhat unsteady in his walk, and it had only been within the three or four days previously that he had been able to go out by himself. The diplopia had persisted. He described it as follows:—"If he looked into the road in front of him there appeared to be two pathways and two sets of people walking on them, one being on the top of the other. In the same way, if a person approached him it seemed as if there were two heads, one above the other."

It was just the same then as it was after the attack. He was under the impression that he had become a little deaf in the right ear. On testing him, however, the hearing in both ears was alike, and practically unaffected. On July 25th, the day he came to the Infirmary, the movements of the eyes inwards, outwards, and downwards were normal, but the eyes, either together or separately, could not be raised upwards. It was curious to note that when he made an effort to look upwards the eyeballs themselves did not move, but the eyelids made the normal elevation, leaving a rim of sclerotic bare above the cornea; in fact, the exact reverse of Graefe's sign of exophthalmic goitre. The attempt also brought about contraction of the occipito-frontalis muscle, and consequent wrinkling of the forehead. Placed eight feet from an electric lamp and on the same level, he saw two lamps, one being about an inch above the other. V. = $\frac{6}{6}$ each eye, and with presbyopia corrected (+ 2·5 D.) he read J. No. 1 with each eye. The pupils reacted normally. There was no numbness in arms or legs, and the patellar reflexes were normal. Two days later the diplopia disappeared, but the inability to move the eyes upward continued. It, however, had passed away

Digitized by Google

by the end of August. At the time of writing, he is able to turn the eyes upwards, singly or together, perfectly. The treatment consisted of iodide of potassium internally.

Remarks.—From the record of this case it will be noted that the palsy of the upward movements of the eyeballs was not associated with disability of the upper eyelids. A reference which particularly bears upon such a case is that by Gowers in his *Diseases of the Nervous System*, 1893 edition, p. 185. It is as follows:—"Paralysis of the upward movement of the eyes has often been observed in cases of central disease, associated with paralysis of the levators. It may result from disease of the posterior part of the third nerve nuclei (Kahler and Pick). When due to such a focal lesion it is usually unilateral. It is possible that there is also a higher centre, disease of which may paralyse the upward movement without the lid, since this isolated symptom may be met with. I have recorded one such case in which the symptom was well-marked. The patient has died since the account of her case was published. A very small tumour was found in the middle line behind the posterior quadrigeminal bodies, damaging these slightly, the velum, and the adjacent part of the inferior vermiform process of the cerebellum."

Whether my case is an instance such as Gowers suggests as possible, *viz.*, of disease of a special centre for the upward movements of the eyes, or not, I must leave to the eminent nerve pathologists we number amongst us to decide. A point, however, which appears to me to suggest its being nuclear or basal is the presence of diplopia, indicating an unequal involvement of the two eyes. The nuclei for the superior rectus and inferior oblique are, it seems, situated in close proximity, and a thrombus or hæmorrhage, whilst involving both sides, might affect one more completely than the other.

Whilst, however, the mode of onset suggests the lesion as more likely to be nuclear, the possibility of its being basal must be borne in mind, especially as basal lesions of

Digitized by Google

the oculo-motor nerve do not always cause paralysis of all its branches. Bearing on this point, I am indebted to my friend Dr. Burgess for the following references from Schmidt-Rimpler's volume of Nothnagel's *System of Medicine:*

Thomson (*Centralb. f. prakt. Augenheilkunde,* 1886, p. 203) observed an impairment of upward movements in both eyes. This was found to be due to a gumma which involved the right nerve and pressed on the left; the nuclei were normal.

Uhthoff (*Deutsche med. Wochenschrift,* 1890, No. 10) asserts that by anatomical lesions of both oculo-motor nerves a partial symmetrical paralysis may result, causing what appears at first sight to be impairment of associated movements or nuclear paralysis. He cites loss of upward movements in illustration of this.

(*November* 14*th,* 1902.)

Dr. ALDREN TURNER said that the interest of Mr. Snell's case was chiefly from a neurological point of view. It would seem, from the suddenness of the onset, to be a vascular lesion, but whether the lesion was limited to the quadrigeminal bodies, or whether it affected both those and the subjacent oculo-motor nuclei, he did not think there was sufficient evidence to show. Paralysis of the upward movements of the eyeballs was one of the classical symptoms of lesions of the quadrigeminal bodies, either directly or from pressure; but the fact remained that the quadrigeminal bodies might be removed experimentally from monkeys without any interference with the movements of the eyeballs, provided the lesion was not sufficiently deep to interfere with the grey matter around the aqueduct of Sylvius. From the facts which Mr. Snell had given, he (Dr. Turner) did not think one could say whether the lesion was limited to the quadrigeminal bodies or affected the oculo-motor nuclei as well. The point which would distinctly favour the supposition that there was a lesion limited to the quadrigeminal bodies in

Digitized by Google

the present case was the presence of the giddiness and unsteadiness observed at the onset of the illness. He understood that that had now passed away, and that the patient was able to walk without assistance.

Mr. MARCUS GUNN drew attention to the fact that in examining the upward movements of both eyes it was important to draw a distinction between the power of the patient to look up if he were merely asked to do so, and his power of looking upwards if an object were given him to look at and follow. In the former case the loss seemingly indicated implication of a higher centre of initiative movement, while in the latter the movement was dependent upon the integrity of lower parts of the nerve-mechanism. At any rate, there was a distinction in the two cases, which he had not infrequently noticed. Sometimes a patient might be absolutely unable to look upwards, and yet might be perfectly able to follow upwards with his eyes a moving object.

Mr. SIMEON SNELL, in reply, thanked Dr. Turner and Mr. Gunn for their remarks. He was not aware that the point Mr. Gunn mentioned was one of importance, but he had tried the present patient in both ways without his being able to turn his eyes upwards.

---

8. *Intra-ocular hæmorrhage in each eye of a young man; recurrence.*

By ROBERT W. DOYNE.

THE L. was affected five years ago, in which he had bare P. L. for five months, recovering with cicatricial bands in vitreous and retina. At that time the R. eye was slightly affected outwards and a little downwards, very far out. Now there is a recurrence in the R. at the

Digitized by Google

same place, down and out. The hæmorrhage was obviously venous on the first occasion.

(*Card specimen. March 13th*, 1903.)

Mr. S. Johnson Taylor asked whether chloride of calcium had been used for the case, as Professor Wright, of Netley, had proved that that substance increased the coagulability of the blood if given in large doses, *i. e.*, 30-gr. doses: it would probably arrest the hæmorrhage. As a prophylactic, 5 grs. three times a day would probably check the tendency to hæmorrhage.

Mr. Bishop Harman said a friend of his who suffered from hæmorrhage from the bladder had been prescribed chloride of calcium by a surgeon; the patient took it for two months regularly without result. He then went to Llandrindod Wells and took the water, the analytical report of which shows the main salt to be chloride of calcium. After taking those waters, the hæmorrhage stopped. Mr. Harman asked his friend to stop the water and see the effect. That was done, and the hæmorrhage recommenced; the water was resumed, and the hæmorrhages stopped. This manœuvre was repeated six times during a period of six months with the same result each time. Mr. Harman suggested an explanation of this might be found in the use of a natural preparation as distinguished from a laboratory product.

Digitized by Google

APPENDIX.

The following specimens and communications were also brought before the Society during the session.

Ophthalmoplegia, congenital.
G. W. Roll (November 14th, 1902).

Spasmodic lid movements associated with jaw muscle contraction. G. W. Roll (November 14th, 1902).

Congenital paralysis of both external recti.
H. B. Grimsdale (November 14th, 1902).

Congenital anophthalmos.
N. C. Ridley (December 11th, 1902).

A case of contracted pupils with only slight dilatation to a mydriatic. S. Mayou (December 11th, 1902).

Changes in papillo-macular region following contusion.
M. T. Yarr, R.A.M.C. (January 29th, 1903).

Carcinoma of conjunctiva of upper lid, with pigmentation of that of the lower.
R. W. Doyne (March 13th, 1903).

A case of chronic irido-cyclitis (probably of sympathetic nature) following an injury to the other eye, twenty-one years previously.
A. Lawson (March 13th, 1903).

Paralysis of the ocular fibres of the right sympathetic associated with aortic disease.
A. Lawson (March 13th, 1903).

A case of "leak in the vitreous."
R. W. Doyne (March 13th, 1903).

Digitized by Google

Microphthalmos. G. W. Roll (May 7th, 1903).

Vagliasindi's instrument for detecting feigned amblyopia.
R. H. Elliot (May 7th, 1903).

Anterior synechia of pupillary membrane.
H. B. Grimsdale (July 3rd, 1903).

Plexiform neuroma of orbit.
W. C. Rockliffe and J. H. Parsons (July 3rd, 1903).

Digitized by Google

REPORT OF THE COUNCIL,

Read at the Annual General Meeting of the Society, July 3rd, 1903.

THE Council have pleasure in reporting upon the continued prosperity and usefulness of the Society, judging by the number and quality of the communications, the variety of the cases shown, the character of the discussions, and the full attendance at the meetings. A large number of new Members annually join the Society. This year twenty-four new names have been added to the list, three Members have resigned, and four have been removed by death, *viz.*, Dr. David Little (the President), Dr. Wm. Woodburn, Dr. Bankart of Exeter, and Dr. J. du Gama. Dr. David Little was an original Member of the Society; he filled the office of Councillor in 1880–81, was a Vice-President in 1888–91, and was elected President in July, 1901. Failing health deprived the Society of his presence in the Chair during the earlier meetings of the current Session, and he died in November, 1902.

Owing to the death of the President, the Council asked the senior Vice-President, Mr. William Lang, to carry on the duties of President during the remainder of the Session.

In response to the request of the Committee of the International Medical Congress held in Madrid in April, 1903, that the Society should be officially represented, the President deputed Mr. Walter H. Jessop to act as

Digitized by Google

delegate at the Congress. Mr. Jessop reports that he was received with great consideration and courtesy, and was nominated one of the Honorary Presidents of the Ophthalmic Section, and that he had the honour of a personal presentation to the King of Spain.

The Council have pleasure in reporting that Dr. F. W. Mott, F.R.S., of London, will deliver the Bowman Lecture in 1904.

The Council also desire to report that they have taken over from the Committee the custody of the Nettleship Prize Fund for the encouragement of scientific ophthalmic work, and have appointed three trustees. The details and working of the prize will be communicated to the Society at the commencement of next Session.

It will be within the recollection of the Members of the Society that a change was made in the day of meeting from Thursday to Friday for two meetings during the Session, in order to facilitate the attendance of members living at a distance from London. The Council suggest that if it is the wish of the Society the old order should be restored, and all the meetings take place on Thursday evenings. In order to cope with the increasing desire of Members to show cases and to communicate papers, the Council have decided to arrange for one additional meeting during the Session in the month of February.

The Honorary Librarian reports that contributions to the library have been received from Dr. Buchanan, Prof. Fuchs, Dr. Maitland Ramsay, and Messrs. Ernest Clarke, Karl Grossman, Arnold Lawson, and Sydney Stephenson.

The Treasurer's report and balance-sheet are in the hands of Members, and show a satisfactory financial condition.

Digitized by Google

ACCOUNT OF THE RECEIPTS AND PAYMENTS OF THE OPHTHALMOLOGICAL SOCIETY OF THE UNITED KINGDOM.

RECEIPTS.

1902–3.	£	s.	d.
To Balance at Bankers, June 18th, 1902	131	12	1
„ Subscriptions	238	8	3
„ Entrance Fees (16)	33	12	0
„ Composition Fees (7)	68	5	0
„ Messrs. Churchill, Sale of 'Transactions'	36	14	0
„ Dividends:			
East India Railway B Annuities £17 6 8			
Ramsgate Corporation Stock 14 7 0			
	31	13	8
	£540	5	0

INVESTMENTS:
£220 East India Railway B Annuities.
£500 Ramsgate Corporation Stock.

PAYMENTS.

1902–3.	£	s.	d.
By Rent	80	0	0
„ Printing Vol. XXII of 'Transactions'	213	16	4
„ Illustrations for do.	47	10	0
„ Library Grant	40	0	0
„ Sub-Librarian	15	15	0
„ Nettleship Prize Fund	10	10	0
„ Expenses at Meetings (Hire of Lantern, Microscopes, etc.)	4	3	0
„ Refreshments at Meetings	9	0	0
„ B. Shaw (carpenter)	1	1	6
„ Expenses at Society's Dinner	11	14	0
„ Bankers' Charges	0	7	5
„ Petty Cash Disbursements	5	8	6
„ Balance, June 18th, 1903	100	19	3
	£540	5	0

(Signed) JOHN ABERCROMBIE, *Hon. Treasurer.*

June 18th, 1903.

Examined, compared with vouchers, and found correct.

(Signed) { N. BISHOP HARMAN, G. WINFIELD ROLL, } *Auditors.*

Digitized by Google

NOTICE.

September, 1902.

Members desirous of using abbreviations in their communications to the Society are requested to confine themselves to those included in the following official list.*

ABBREVIATIONS.

Acc.	Accommodation.
Aq.	Aqueous humour.
As.	Astigmatism.
A.C.	Anterior chamber.
C.	Cornea.
Ch.	Choroid.
cm.	Centimetre.
Cyl.	Cylindrical lens.
D.	Dioptre or dioptric.
E.	Emmetropia.
F.	Field of vision.
H.	Hypermetropia.
H.l.	Latent hypermetropia.
H.m.	Manifest hypermetropia.
I.	Iris.
L.	Left eye (and R., right eye).
m.	Metre.
mm.	Millimetre.
My.	Myopia.
M.L.	Macula lutea (and Y.S., yellow spot).
Oph.	Ophthalmoscope, ophthalmoscopic examination, ophthalmoscopic appearances.
O.D.	Optic disc.
O.P.	Optic papilla.
P.	Pupil.
Pr.	Presbyopia.
P.L.	Perception of light.
p.p.	Punctum proximum.
p.r.	Punctum remotissimum.
R.	Right eye (and L., left eye).
Ret.	Retina.
Scl.	Sclerotic.
Sph.	Spherical lens.
T.	Tension of the eyeball. T.n., tension normal. T. +1, T. +2, T. +3, } degrees T. −1, T. −2, T. −3, } of increase and decrease of tension.
Vit.	Vitreous humour.
Y.S.	Yellow spot (and M.L., macula lutea).
V.	Visus, acuteness of sight, power of distinguishing form.

SYMBOLS.

+	Symbol for a convex lens.
−	Symbol for a concave lens.
′	Foot.
″	Inch.
‴	Line.

* See *Transactions*, vol. iv (1884), p. 365.

Digitized by Google

INDEX.

PAGE

A case operated on for conical cornea . . . 351
A circular-shaped lamp resistance . . . 350
A clinical and pathological account of some of the injuries to the eye of the child during labour . . . 296
A contribution to the study of rheumatic iritis . . 39
A minimal form of facial fissure 256
A new pocket transformer 349
A rare form of nystagmus 260
Acromegaly, a case of 373
——— pituitary body in 373
Adrenalin and glaucoma 374
Alveolar sarcoma of the cornea 34
Anatomy, pathological 216
Aneurismal dilatations on diseased retinal arteries . . 73
Aniridia and coloboma of iris 261
Anophthalmos and microphthalmos in a chick . . 244
Appendix 397
Appliance for electric warmth to the eye . . . 346
Artery, persistent hyaloid 242
Associated "jaw-winking" movements . . . 369
Atrophy of optic nerve caused by lightning . . 114
Avulsion of eyeball by midwifery forceps . . . 294

BALDWIN (H. Clifford), traumatic dislocation of eyeball forwards through the palpebral opening; immediate reduction by taxis; complete recovery 281
BALLANTYNE (A. J.) and THOMSON (W. E.) 273, 274, 276, 277
BATTEN (F. E.), cerebral degeneration with symmetrical changes in the maculæ in two members of a family . 386
BATTEN (Rayner D.), discussion on symmetrical changes in the maculæ 389
——— obliteration of a retinal vein, with formation of new vessels 75

Digitized by Google

PAGE

BEAUMONT (W. M.), discussion on traumatic dislocation of eyeball 282

BEEVOR (C. E.), discussion on paralysis of right sixth and seventh nerves 291

BLAIR (Charles), a case of zonular opacity of the cornea . 29

——— and POTTER (Bernard), two cases of aniridia and one of coloboma of the iris in the same family . . 261

Blood in the anterior chamber, with staining of the cornea, simulating dislocation forwards of the lens . . 322

BREUER (A.), discussion on colour-blindness . . 208

BREWERTON (E. W.), a rare form of nystagmus . . 260

——— pathological report on nævus of the orbit . . 192

Brood capsules in echinococcus cyst . . . 193

BROOKSBANK-JAMES (G.), a portable perimeter . . 346

BUCHANAN (Leslie), a case of mycosis of the cornea . . 29

——— and THOMSON (W. E.), injuries to the eye of the child during labour 296

——— case of congenital maldevelopment of the cornea and sclerotic 267

——— ——— of early formation of true bone in a shrivelled stump 216

——— keratitis, with special reference to the part played by the corneal corpuscles 239

——— traumatic separation of the ciliary body due to rupture of the pectinate ligament 283

CARGILL (L. V.), discussion on the treatment of trachoma by the X-rays 22

Case in which paralysis of the right sixth and seventh nerves was present at birth in a child delivered by forceps; recovery 287

——— of acromegaly 373

——— of defect of movement of one eye with enophthalmos . 269

——— of detachment of retina 66

——— of early formation of true bone in a shrivelled stump . 216

——— of intra-ocular echinococcus cyst . . . 193

——— of Leber's disease in which recovery of sight took place 108

——— of mycosis of the cornea 29

——— of primary papilloma of the cornea . . . 31

——— of zonular or ribbon-shaped opacity of the cornea . 29

Cases illustrating an unusual form of corneal opacity, due to the long-continued application of copper sulphate to the palpebral conjunctiva 25

Digitized by Google

PAGE
Central serpiginous choroiditis 48
Cerebral degeneration with symmetrical changes in the maculæ in two members of a family . . . 386
Chick, anophthalmos and microphthalmos in a . . 244
Child with multiple deformities of the eye, eyelids, etc. . 263
Chorio-vaginal veins 273
Choroid, ossification of the 217
Choroiditis, central serpiginous 48
——— tubercular 50
——— tuberculous 63
Ciliary body, separation of 283
Clarke (Ernest), blood in the anterior chamber, with staining of the cornea, simulating dislocation forwards of the lens . 322
Collins (E. Treacher), a case of favus of the upper eyelid . 1
——— and Parsons (J. H.), anophthalmos and microphthalmos in a chick 244
——— discussion on a minimal form of fissura facialis . 260
——— ——— on fistula formation in simple chronic glaucoma 342
——— ——— on symmetrical changes in the maculæ . 390
——— histological reports on Snell's cases of plexiform neuroma 163, 168, 171
——— partial atrophy of the optic nerves caused by lightning 114
Coloboma of optic nerve sheath, with microphthalmos . 272
Colobomata, pigmented, of optic discs 277
Colour-blindness 206
——— the tests for 206
Concussion injury; coloboma of disc 285
Congenital bilateral pigmentation of the cornea . . 274
——— conditions 242
——— development of choroidal tissue in the optic nerves of two brothers 276
——— malformation of lower eyelids . . . 263
Conjunctiva, diseases of the 3
——— epithelioma of ocular 5
——— lymphangiectasis of 23
——— melanosarcoma of 7
——— papilloma of the ocular 4
——— ——— of the palpebral 3
Connective tissue veiling the optic disc . . . 254
Cornea, alveolar sarcoma of 34
——— and sclerotic, maldevelopment of . . . 267
——— conical 351

Digitized by Google

PAGE
Cornea, copper staining of . . . 25
——— diseases of 25
——— endothelioma of the 35
——— mycosis of the 219
——— pigmentation of, congenital . . . 274
——— primary papilloma of 31
——— zonular opacity of . . 27, 29
Corneal corpuscles in keratitis 239
Council, report of the 399
Crater-like hole in the optic disc 277
CRITCHETT (Sir Anderson), discussion on endothelioma of the cornea 38
——— ——— on fistula formation in simple, chronic glaucoma 344

DEAN (C. W.), a case of primary papilloma of the cornea . 31
Deformity of the head, and proptosis . . . 264
Dermoid cyst of orbit, causing complete dislocation of eyeball 154
Detachment of retina 66
Dislocation of the eyeball . . . 294, 316, 319
DODD (H. Work), melanosarcoma of conjunctiva . . 7
DONALDSON (E.), a case of deformity of the head, and proptosis 264
——— alveolar sarcoma of the cornea . . . 34
DOYNE (R. W.), a case of microphthalmos, etc. . . 269
——— a child with multiple deformities of the eye, eyelids, etc. 263
——— discussion on acromegaly 373
——— ——— on concussion injury . . . 286
——— ——— on dermoid cyst of orbit . . . 156
——— intra-ocular hæmorrhage in each eye of a young man; recurrence 395
Drusenbildungen, *see* Hyaline bodies at the optic disc.

EASON (Herbert L.), a case of congenital defect of movement of one eye associated with a slight degree of enophthalmos 269
Echinococcus cyst with brood capsules . . . 193
EDRIDGE-GREEN (F. W.), on the necessity for the use of colour names in a test for colour-blindness . . 210
——— the tests for colour-blindness . . . 206
Elephantiasis neuromatosis 157
Embolism of central artery of retina . . . 74
Endothelioma of the cornea 35
Enophthalmos and defective movement of eye . . 269
Epithelioma of ocular conjunctiva . . . 5

Digitized by Google

PAGE
Ethmoid, disease of 177
Exophthalmos, a case of pulsating . . . 321
Eyeball, avulsion of, by midwifery forceps . . . 294
——— dislocated by dermoid cyst of orbit . . . 154
——— traumatic dislocation of . . . 281, 319
Eyelid, favus of 1
Eyelids, diseases of 1
——— lower, congenital malformation of . . . 263

Favus of upper eyelid 1
Fisher (J. Herbert), aneurismal dilatations on diseased retinal arteries 73
——— discussion on dermoid cyst of orbit . . . 156
——— ——— on paralysis of the right sixth and seventh nerves 293
Fissura facialis, a minimal form of . . . 256
Fistula formation in glaucoma 324
Flemming (P.) and Parsons (J. H.), persistent hyaloid artery 242
Frost (W. Adams), discussion on colour-blindness . 207, 208
——— ——— on concussion injury . . . 286
——— ——— on conical cornea 352
——— ——— on detachment of retina . . . 68
——— ——— on recovery of sight in Leber's disease . 111
——— ——— on symmetrical changes in the maculæ . 389
——— ——— on zonular opacity of the cornea . . 28

Glaucoma, adrenalin in 374
——— fistula formation in 324
Goldsmith (G. H.). concussion injury; coloboma of disc . 285
Gunn (Marcus), discussion on hyaline bodies at the optic disc 153
——— ——— on paralysis of the upward movement of the eyes 395

Hæmorrhage, intra-ocular 395
——— ——— calcium chloride in 396
Harman (N. Bishop), a minimal form of fissura facialis . 256
——— associated "jaw-winking" movements . . 369
——— discussion on adrenalin in glaucoma . . 381
——— ——— on defect of movement of one eye with enophthalmos 271
——— ——— on intra-ocular hæmorrhages . . 396
——— rectangular connective-tissue film veiling the optic disc 254
——— the innervation of the orbicularis palpebrarum muscle . 356

Digitized by Google

PAGE
HARTRIDGE (G.), a case of pulsating exophthalmos (traumatic) 321
——— discussion on rheumatic iritis . . . 44
——— ——— on tumours in yellow spot . . . 385
——— zonular opacity of the cornea . . . 27
HERBERT (Major H.), subconjunctival fistula formation in the treatment of primary chronic glaucoma . . 324
Hyaline bodies at the optic disc 135
Hyaloid artery, persistent 242

Injuries 279
Innervation of the orbicularis palpebrarum . . 356
Intra-ocular hæmorrhage 395
Iris, diseases of 39
Iritis, rheumatic 39

JESSOP (Walter H.), discussion on adrenalin in glaucoma . 381
——— ——— on unusual retino-choroidal changes . . 65
——— retro-bulbar neuritis and peculiar appearance of retinal vessels 112
——— sympathetic ophthalmitis with cystic changes in the iris 46
——— tumour in region of yellow spot . . . 384
——— two cases of proptosis associated with disease of ethmoid and sphenoid respectively . . . 177
——— two cases of tubercular choroiditis . . . 50
JULER (H.), discussion on conical cornea . . . 353
——— ——— on tubercular choroiditis . . . 59

Keratitis and the part played by the corneal corpuscles . 239
Krönlein's operation 77

Labour, injuries to the eye during . . . 296
LANG (William), discussion on atrophy of the optic nerves caused by lightning 116
——— ——— on blood in the anterior chamber . . 323
——— ——— on colour-blindness . . . 207
——— ——— on concussion injury . . . 286
——— ——— on conical cornea 352
——— ——— on Krönlein's operation . . . 108
——— ——— on mycosis of the cornea . . . 31
——— ——— on rheumatic iritis 44
——— ——— on staining of the cornea due to copper sulphate 27
——— ——— on symmetrical changes in the maculæ . 389

Digitized by Google

PAGE

LANG (William), discussion on the treatment of trachoma by the X-rays 21
——— ——— on traumatic separation of the ciliary body . 285
——— ——— on unusual retino-choroidal changes . . 65
——— ——— on zonular opacity of the cornea . . 28
LAWFORD (J. B.), discussion on dermoid cyst of orbit . 156
——— ——— on Krönlein's operation . . . 108
——— ——— on recovery of sight in Leber's disease . 112
——— notes of a case of dislocation of the eyeball . . 319
LAWSON (Arnold), a case of acromegaly with bitemporal hemiopia, showing the changes that have taken place in the visual fields after four months' treatment with pituitary body tabloids 373
——— unusual retino-choroidal changes . . . 64
Leber's disease and recovery of sight . . . 108
LEDIARD (H. A.), dermoid cyst of orbit, causing complete dislocation of eyeball 154
Lightning and atrophy of optic nerves . . . 114
Lymphangiectasis of conjunctiva 23

MACCALLAN (A. F.), lymphangiectasis of conjunctiva . 23
——— report of five cases of glaucoma in which adrenalin caused an increase of tension 374
MADDOX (E. E.), a circular-shaped lamp resistance . . 350
——— a new pocket transformer 349
——— appliance for electric warmth to the eye . . 346
MARSHALL (C. D.), discussion on the necessity for the use of colour names in a test for colour-blindness . . 214
MAYOU (Stephen), treatment of trachoma by the X-rays . 10
——— two drawings of normal fundi illuminated by means of a mercury vapour lamp 390
Melanosarcoma of conjunctiva 7
Mercury vapour lamp 390
Microphthalmos and anophthalmos . . . 244
——— and coloboma 272
——— etc. 269
Miscellaneous communications 356
MORTON (A. S.), a case operated on for conical cornea . 351
——— and PARSONS (J. H.), hyaline bodies at the optic disc . 135
——— discussion on night-blindness . . . 70
Mycosis of the cornea 29

Nævus of orbit. 188

Digitized by Google

PAGE

NETTLESHIP (E.), a case in which paralysis of the right sixth and seventh nerves was present at birth in a child delivered by forceps; recovery 287
——— ——— of family optic neuritis (Leber's disease) in which perfect recovery of sight took place . . 108
——— discussion on dermoid cyst of orbit . . . 156
——— ——— on detachment of retina . . . 68
——— *see* Traumatic dislocation of eyeball.
Night-blindness in five generations . . . 68
Notes of a case of dislocation of the eyeball . . 319
Nystagmus, a rare form of 260

Obliteration of a retinal vessel with formation of new vessels 75
OGILVY (A.), tumour of ocular conjunctiva . . . 5
On the necessity for the use of colour names in a test for colour-blindness 210
Operations, instruments, and appliances . . . 324
Optic disc, crater-like hole in 277
——— ——— hyaline bodies at 135
——— discs, pigmented colobomata of . . . 277
——— nerve, diseases of 77
——— ——— primary extra-dural tumours of . . 116
——— ——— ——— intra-dural tumours of . . 77
Orbicularis palpebrarum, innervation of . . . 356
Orbit and sinuses, diseases of 154
——— nævus of 188
ORMOND (A. W.), discussion on recovery of sight in Leber's disease 111
Ossification of the choroid 217
Oxycephaly 264

Palpebral conjunctiva, papilloma of . . . 3
Papilloma of cornea 31
——— of ocular conjunctiva 4
——— of palpebral conjunctiva 3
Paralysis of the upward movement of the eyes . . 391
Parasites 193
PARSONS (J. Herbert) and FLEMMING (P.), persistent hyaloid artery 242
——— and MORTON (A. S.), hyaline bodies at the optic disc . 135
——— and SINCLAIR (W. W.), endothelioma of the cornea . 35
——— discussion on adrenalin in glaucoma . . 382
——— primary extra-dural tumours of the optic nerve . 116

Digitized by Google

PAGE
Partial atrophy of the optic nerves caused by lightning . 114
Pathological anatomy 216
Paton (Leslie), ? tuberculous choroiditis . . . 63
Perimeter, a portable 346
Plexiform neuroma (elephantiasis neuromatosis) of temporal region, orbit, eyelid, and eyeball . . . 157
——— ——— histological report on, by E. T. Collins 163, 168, 171
Potter (B.) and Blair (C.) 261
Poynton (F. J.) and Paine (A.), a contribution to the study of rheumatic iritis 39
Primary extra-dural tumours of the optic nerve . . 116
Proptosis due to disease of ethmoid and sphenoid . . 177
Pulsating exophthalmos (traumatic) . . . 321

Report of the Council 399
Retina and choroid, diseases of 48
——— detachment of 66
Retinitis pigmentosa 68
——— proliferans and detachment of retina . . 71
Retino-choroidal changes, unusual . . . 64
Retro-bulbar neuritis and peculiar appearance of retinal vessels 112
Rheumatic iritis 39
Ridley (N. C.), embolism of central artery of retina in a young girl 74

Scott (G. M.), retinitis proliferans and detachment of retina . 71
Sight, recovery of, in Leber's disease . . . 108
Silcock (A. Q.) and MacCallan (A. F.), case of detachment of retina 66
——— discussion on tumour in region of yellow spot . 386
Sinclair (W. W.) and Parsons (J. H.), endothelioma of the cornea 35
Smith (Priestley), discussion on fistula formation in simple, chronic glaucoma 341
Snell (Simeon), avulsion of eyeball by midwifery forceps . 294
——— numerous instances of night-blindness occurring in five generations 68
——— paralysis of the upward movement of the eyes . 391
——— plexiform neuroma 157
Snowball (Thomas), ossification of the choroid . . 217
Sphenoid, disease of 177

Digitized by Google

PAGE
SPICER (Holmes), discussion on adrenalin in glaucoma . 383
——— ——— on rheumatic iritis 44
——— ——— on tubercular choroiditis . . . 59
——— nævus of orbit; evacuation of the orbit after removal of the eye 188
STEPHENSON (Sydney), discussion on Krönlein's operation . 108
——— ——— on the treatment of trachoma by the X-rays . 22
——— ——— on tubercular choroiditis . . 58, 60, 61
——— papilloma of palpebral conjunctiva . . . 3
——— ——— of the ocular conjunctiva . . . 4
——— staining of the cornea by copper sulphate . . 25
Stump, early formation of bone in . . . 216
Subconjunctival fistula formation in the treatment of primary, chronic glaucoma 324
Sunlight causing thrombosis 279
Sympathetic disease 46
——— ophthalmitis with cystic changes in the iris . . 46

TAYLOR (Johnson), discussion on adrenalin in glaucoma . 383
——— ——— on conical cornea 352
——— ——— on intra-ocular hæmorrhage . . 396
——— ——— on recovery of sight in Leber's disease . 111
——— ——— on tubercular choroiditis . . 59, 61
Tests for colour-blindness 206
THOMSON (W. E.) and BALLANTYNE (A. J.), chorio-vaginal veins in the myope and hypermetrope . . . 273
——— ——— congenital bilateral pigmentation of the cornea 274
——— ——— ——— development of choroidal tissue in the optic nerves of two brothers 276
——— ——— crater-like hole in the optic disc . . 277
——— ——— pigmented colobomata of the optic discs . 277
——— and BUCHANAN (Leslie), a clinical and pathological account of some of the injuries to the eye of the child during labour 296
Thrombosis of the inferior temporal branch of the arteria centralis retinæ with ? persistent hyaloid artery and vein 279
Trachoma, treatment of, by the X-rays . . . 10
Traumatic dislocation of eyeball 281
——— separation of the ciliary body . . . 283
Treatment of trachoma by the X-rays . . . 10
Tubercular choroiditis 50
Tuberculous choroiditis 63

Digitized by Google

PAGE

Tumour in region of yellow spot 384

TURNER (Aldren), discussion on paralysis of the upward movement of the eyes 394

——— ——— on the innervation of the orbicularis palpebrarum muscle 372

TYRRELL (F. A. C.), congenital malformation of lower eyelids 263

VERHOEFF, discussion on plexiform neuroma . . 176

WALKER (Cyril H.), thrombosis of the inferior temporal branch of the arteria centralis retinæ in an eye with ? persistent hyaloid artery and vein; ? caused by exposure to direct sunlight 279

WERNER (L.), a case of intra-ocular echinococcus cyst with brood capsules 193

——— central serpiginous choroiditis . . . 48

——— coloboma of the optic nerve-sheath with microphthalmos 272

——— discussion on hyaline bodies at the optic disc . 153

——— two cases of primary intra-dural tumours of the optic nerve 77

Zonular opacity of cornea 27

PRINTED BY ADLARD AND SON, LONDON AND DORKING.

Digitized by Google

Digitized by Google

Digitized by Google

Digitized by Google